

Eye Muscle Surgery for Acquired Forms of Nystagmus

ROBERT L. TOMSAK, LOUIS F. DELL'OSSO, JONATHAN B. JACOBS,
ZHONG I. WANG, AND R. JOHN LEIGH

ABSTRACT

We report 3 patients with acquired nystagmus who were treated with eye muscle tenotomy and reattachment. The first patient had acquired pendular nystagmus (APN) associated with multiple sclerosis (MS) and underwent bilateral medial rectus tenotomies and bilateral lateral rectus recessions to correct exotropia. Eye movements were recorded before surgery, after surgery, and after surgery and treatment with memantine. Following surgery, APN decreased by $\approx 50\%$ and the eXpanded Nystagmus Acuity Function (NAFX) increased by 34%. Measured Snellen acuity increased 100%, from 0.125 OD and OS to 0.25. Saccades were unaffected. After treatment with memantine, APN was damped further by 69%, and NAFX was improved an additional 9%; Snellen acuity increased 60% to 0.4. The second patient had monocular APN associated with MS. The horizontal recti were tenotomized and reattached in only the eye with nystagmus. This resulted in damping of the nystagmus by 66%, and Snellen acuity increased 100% from 0.2 to 0.4. The third patient had downbeat nystagmus of undetermined etiology and preferred a chin-down (up-gaze) head position to diminish symptoms. Asymmetrical superior rectus recessions, to address head position and hypertropia, were combined with tenotomy and reattachment of both inferior recti. Surgery resulted in reduction of vertical nystagmus by 46%, improvement of NAFX values by 17%, and improvement in visual acuity from 20/25

to 20/20. These preliminary results support the view that eye muscle tenotomy may diminish acquired forms of nystagmus and improve vision in selected patients.

Although eye muscle surgery is established as a treatment modality for congenital forms of nystagmus, its place in the therapy of acquired forms of nystagmus is debated. Currently, there is a dearth of studies that evaluate the results of such surgery using reliable methods for measuring eye movements. In this chapter, we report our experience in studying the effects of surgery on the eye muscles of 3 patients with acquired forms of nystagmus. We have used a procedure developed for the treatment of congenital forms of nystagmus—eye muscle tenotomy and reattachment (T&R).¹ Partial descriptions of these cases have been previously published.^{2,3}

CASE REPORTS

Case 1

The first patient had acquired pendular nystagmus (APN) from multiple sclerosis (MS) and underwent bilateral medial rectus T&R and bilateral lateral rectus recessions to correct exotropia (i.e., tenotomy combined with recession). Eye movements were recorded by the scleral search coil technique at three times: before surgery, after surgery, and after surgery and treatment with oral memantine (Figs. 13.1 and 13.2). Following surgery, APN decreased by $\approx 50\%$, and the eXpanded Nystagmus Acuity Function (NAFX)

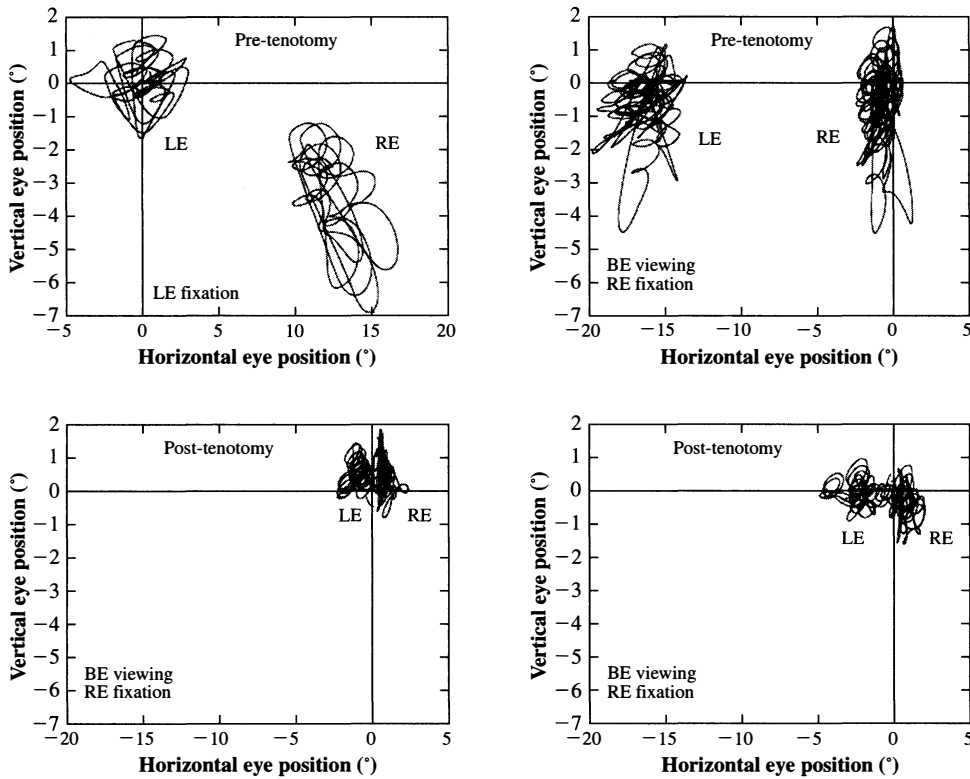


Figure 13.1 Presurgery and post-surgery scanpaths (horizontal vs. vertical) from case 1. The horizontal and vertical components of acquired pendular nystagmus were damped by surgery and exotropia was improved post-operatively. RE, right eye; LE, left eye; BE, both eyes.

increased by 34%. Measured Snellen acuity increased 100% from 0.125 OD and OS to 0.25. Saccades were unaffected. After treatment with memantine, APN was damped further by 69% and NAFX was improved an additional 9%; Snellen acuity increased 60% to 0.4.

Comment: Vertical components of APN were reduced as well as horizontal components, even though surgery was only done on the four horizontal recti. Memantine appeared to have an additive effect to T&R, presumably by a different, central mechanism.

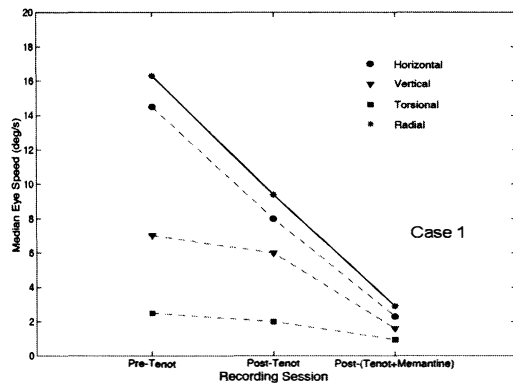


Figure 13.2 Eye speeds for the fixating right eye (case 1) measured pre- and post-horizontal rectus muscle surgery and also after addition of memantine.

Case 2

The second patient (Fig. 13.3) had unocular APN in association with MS. Pre- and post-tenotomy eye movements were studied using digitized video recordings. The horizontal recti were tenotomized and reattached only in the eye with APN; this resulted in damping of the nystagmus by 66% and an increase in Snellen acuity 100% from 0.2 to 0.4. *Comment:* The addition of gabapentin did not appear to augment effect of T&R in this patient.

Case 3

The third patient (Fig. 13.4) had downbeat nystagmus of undetermined etiology, oscillopsia, and vertical

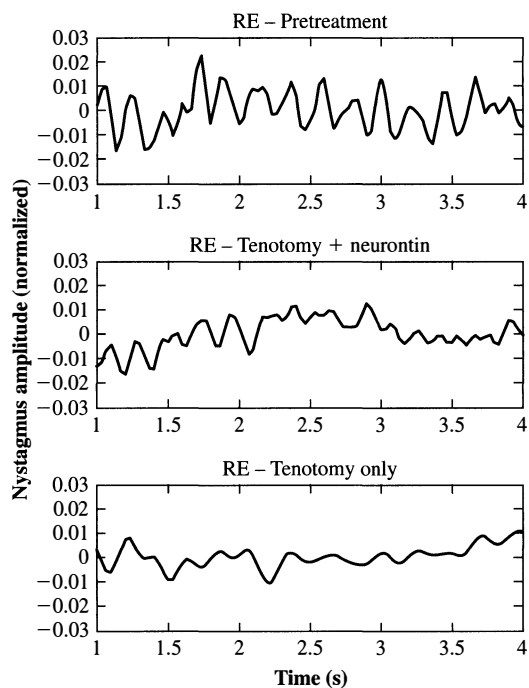


Figure 13.3 Case 2: Segments of right eye horizontal nystagmus reconstructed from the digitized videotape recordings. The addition of gabapentin (*center*) did not appear to augment effect of tenotomy and reattachment.

diplopia from skew deviation; he preferred a chin-down (up-gaze) head position to diminish symptoms. Pre- and post-tenotomy eye movements were recorded by a high-speed digital video system. Asymmetrical superior rectus recessions were done to address head position and hypertropia and were combined with T&R of both inferior recti. Surgery resulted in movement of the NAFX peak from 10° up to primary position, and NAFX values were improved by 17%. Vertical NAFX values increased across the -10° to $\pm 5^\circ$ vertical range. Foveation time per cycle increased from 88 to 178 milliseconds (102%). Vertical component nystagmus amplitude was reduced by 46%, and frequency was unchanged at ≈ 3 Hz. Visual acuity was improved from 20/25 to 20/20, and the hypertropia was improved. *Comment:* The vertical NAFX was increased across the -10° to $\pm 5^\circ$ range, resulting in improved functional vision.

DISCUSSION

To put the present results into context, we provide a brief historical review of the surgical treatment of nystagmus. In 1906, Colburn described attaching the

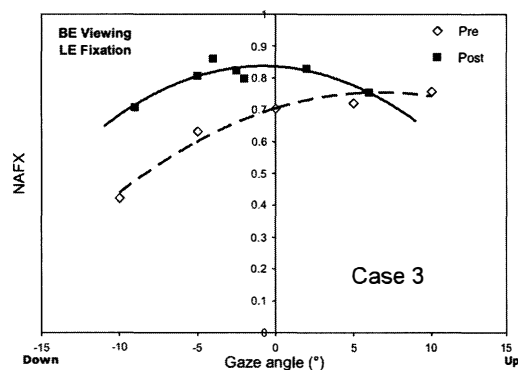


Figure 13.4 Case 3: Vertical eXpanded Nystagmus Acuity Function (NAFX) values increased across the -10° to $\pm 5^\circ$ range of vertical gaze postoperatively.

lateral rectus to the periosteum of the orbital wall in an attempt to reduce the amplitude of nystagmus.⁴ Little else was reported until the early 1950s, when Kestenbaum,⁵ Anderson,⁶ Goto,⁷ and Rama⁸ described surgical techniques to change gaze angle in order to take advantage of nystagmus null positions, mainly in cases of congenital nystagmus.⁴ (*Infantile nystagmus* is now replaced *congenital nystagmus* as the preferred term and will be used in this chapter except when quoting older literature.) Kestenbaum described a resect-recess operation and, in the second edition of his book, *Clinical Methods of Neuro-Ophthalmologic Evaluation*,⁵ made the following comment (italics added): “The genesis of the nystagmus is not relevant for the indication of surgery. The nystagmus may be an asymmetric nystagmus from infancy or an *acquired nystagmus in a demyelinating disease* or a ‘manifested latent nystagmus.’ ”

Anderson⁶ described recession of yoke muscles in the direction of the slow-phase drift of nystagmus. He came to this idea after observing a change in subjective and objective characteristics of nystagmus in a patient who underwent strabismus surgery.

It had been observed that nystagmus is not infrequently lessened after an operation for strabismus had been performed. One man, aged 22 years, at the time of operation for a left convergent strabismus of at least 60 dioptres, had been worried by the apparent movement of a wall from side to side. It is unusual for patients with congenital nystagmus to be conscious of movement of objects, and this man was conscious only of the movement of walls. Vision was 6/9 in the right eye and 6/12 in the left. Both nystagmus and strabismus had been life-long. The conscious movement vanished after a recession

of each internal rectus muscle and a resection of each external rectus muscle, even though an angle of anomaly of 20 dioptres persisted. (p. 279)

Apparently this was one of the rare patients with infantile nystagmus who had oscillopsia, and the oscillopsia resolved following a bilateral recession–resection (i.e., four-horizontal-muscle) surgery, thus implying an improvement in nystagmus.

Rama,⁸ in 1953, reported a technique similar to Anderson's procedure. One year later, Goto⁷ described combining recession with advancement of the antagonist muscle. Over time, surgical procedures to realign the eyes of patients with nystagmus and gaze nulls became known as "Anderson-Kestenbaum procedures." (We refer to "nystagmus surgery" as any eye muscle surgery done primarily to damp nystagmus, and "strabismus surgery" as any procedure done primarily to correct ocular misalignment. Often, nystagmus surgery and strabismus surgery are combined in the same patient.)

In 1979, Dell'Osso and Flynn⁹ recorded eye movements of 3 patients before and after surgery for congenital nystagmus. In addition to shifting the nystagmus null, they observed broadening of the null region and an overall reduction of nystagmus intensity at all gaze angles. This led them to speculate that the surgery caused "nonlinear changes in ocular motor plant dynamics (i.e., changes in the characteristics of the muscles, tendons, Tenon's capsule, fatty and scar tissue interactions) as a result of the surgical changing of the points of insertion and methods of attachment of the muscles to the globe."

Bosone et al.¹⁰ found similar results. Subsequently, Dell'Osso et al. showed that eye muscle tenotomy and reattachment (T&R) alone had salutary effects on nystagmus amplitude and velocity in dogs with nystagmus¹¹ and in humans with infantile nystagmus.^{1,12} A hypothesis evolved that T&R damaged proprioceptive structures in eye muscle tendon that affected the nystagmus oscillation.¹³

More recently, Büttner-Ennever et al.¹⁴ identified two separate sets of ocular motor neurons, one of which participates in proprioceptive feedback that aligns and stabilizes the eyes and has palisade endings located in myotendinous junctions of eye muscles. The cell bodies for these neurons are located around the periphery of the brainstem nuclei. Hertle et al.¹⁵ found similar structures more distally at the enthesial (tendino-scleral) regions of eye muscle tendons.

All of the forgoing support the hypothesis that T&R of selected eye muscles should have a beneficial effect on acquired nystagmus by the same mechanism as it does on infantile nystagmus: reduction of small-signal gain of the ocular motor plant by interfering with

proprioceptive tension control.¹⁶ Our present results support the view that eye muscle tenotomy may have a role to play in acquired forms of nystagmus of differing etiologies, waveforms, planes of action, and even various neuroanatomic sites of origin. This ability to treat different types of nystagmus supports the hypothesized proprioceptive mechanism of action. Controlled, prospective studies of T&R as treatment of acquired nystagmus are called for so that this therapy can be compared with available pharmacological measures.

References

- Hertle RW, Dell'Osso LF, FitzGibbon EJ, Thomson D, Yang D, Mellow SD. Horizontal rectus tenotomy in patients with congenital nystagmus. Results in 10 adults. *Ophthalmol.* 2003;110:2097–2105.
- Tomsak RL, Dell'Osso LF, Rucker JR, Leigh RJ, Bienfang DC, Jacobs JB. Treatment of acquired pendular nystagmus from multiple sclerosis with eye muscle surgery followed by oral memantine. *Digital J Ophthalmol.* 2005;11(4):1–11.
- Tomsak RL, Wang Z, Dell'Osso LF, Jacobs JB. Combined tenotomy ± Anderson procedure for treatment of acquired vertical nystagmus and infantile horizontal nystagmus associated with diplopia and oscillopsia. ARVO Annual Meeting Abstract and Program Planner. *Invest Ophthalmol Vis Science.* 2006;47. E-Abstract 2512.
- Colburn JE. Fixation of the external rectus muscle in nystagmus and paralysis. *Am J Ophthalmol.* 1906;23:85–88.
- Kestenbaum A. *Clinical Methods of Neuro-ophthalmologic Evaluation*, 2nd ed. New York, NY: Grune and Stratton; 1961.
- Anderson JR. Causes and treatment of congenital eccentric nystagmus. *Brit J Ophthalmol.* 1953;37:267–281.
- Goto N. Nystagmus surgery. *Act Soc Ophth Jap.* 1954;58:176.
- Rama G. Strabismo e nistagmo. *Rass Ital Ottal.* 1953;22:245.
- Dell'Osso LF, Flynn JT. Congenital nystagmus surgery: a quantitative evaluation of the effects. *Arch Ophthalmol.* 1979;97:462–469.
- Bosone G, Reccia R, Roberti G, Russo P. On the variations of the time constant of the slow-phase eye movements produced by surgical therapy of congenital nystagmus: a preliminary report. *Ophthalm Res.* 1989;21:345–351.
- Dell'Osso LF, Hertle RW, Williams RW, Jacobs JB. A new surgery for congenital nystagmus: effects of tenotomy on an achiasmatic canine and

- the role of extraocular proprioception. *J AAPOS*. 1999;3:166–182.
12. Hertle RW, Dell’Osso LF, FitzGibbon EJ, Thompson D, Yang D, Mellow SD. Horizontal rectus muscle tenotomy in patients with infantile nystagmus syndrome: a pilot study. *J AAPOS*. 2004;8:539–548.
 13. Dell’Osso LF. Extraocular muscle tenotomy, dissection and suture: an hypothetical therapy for congenital nystagmus. *J Pediat Ophth Strab*. 1998;35:232–233.
 14. Büttner-Ennever JA, Horn AKE. The neuroanatomical basis of oculomotor disorders: the dual motor control of extraocular muscles and its possible role in proprioception. *Curr Opin Neurol*. 2002;15:35–43.
 15. Hertle RW, Chan CC, Galita DA, Maybodi M, Crawford MA. Neuroanatomy of the extraocular muscle tendon entheses in macaque, normal human, and patients with congenital nystagmus. *J AAPOS*. 2002;6:319–327.
 16. Wang Z, Dell’Osso LF, Zhang Z, Leigh RJ, Jacobs JB. Tenotomy does not affect saccadic velocities: support for “small-signal” gain hypothesis. *Vision Res*. 2006;46:2259–2267.

Advances in Understanding
Mechanisms and Treatment of Infantile
Forms of Nystagmus

Edited by

R. John Leigh, MD

Michael W. Devereaux, MD

OXFORD
UNIVERSITY PRESS
2008