

# Combining Peripheral-Surgical (Tenotomy) with either Central-Pharmacological (Memantine) or other Peripheral-Surgical (Anderson) Therapies to Damp Acquired Pendular or Downbeat Nystagmus and Oscillopsia

Louis F. DELL'OSSO<sup>1,3</sup>, Robert L. TOMSAK<sup>1,2,4</sup>, Zhong WANG<sup>1,3</sup>, R. John LEIGH<sup>1,3</sup>, and Jonathan B. JACOBS<sup>1,2</sup>

<sup>1</sup> The Daroff-Dell'Osso Ocular Motility Laboratory, Louis Stokes Cleveland Department of Veterans Affairs Medical Center and CASE Medical School, Cleveland, OH, USA

<sup>2</sup> Dept of Neurology, Case Western Reserve University and University Hospitals of Cleveland, Cleveland, OH, USA

<sup>3</sup> Dept of Biomedical Engineering, Case Western Reserve University, Cleveland, OH, USA

<sup>4</sup> Dept of Ophthalmology, Case Western Reserve University, Cleveland, OH, USA

## ABSTRACT

We report the results of our studies of the effects of tenotomy on two different types of acquired nystagmus, pendular (APN) and downbeat (DBN). Eye movements of two subjects, Case 1 with APN and Case 2 with DBN were recorded using infrared reflection, magnetic search coil, or high-speed digital video. The eXpanded Nystagmus Acuity Function (NAFX) quantified tenotomy-induced foveation changes in the nystagmus. Horizontal rectus muscle tenotomies of both eyes were combined with recessions to correct exotropia (Case 1) and to move the null region downward (Case 2); memantine was given following surgery (Case 1). Search-coils were used to record ocular motility before and after surgery and after memantine in Case 1; high-speed digital video was used in Case 2. Following surgery, APN decreased by ~50%, NAFX increased by 34%, and Snellen visual acuity increased 100% to 0.25. Saccades were unaffected. Memantine further damped the APN 69%, increased the NAFX by 9%, and increased visual acuity 60% to 0.4. The cumulative effects were: APN reduced by 82%; NAFX increased by 46%; acuity increased by 220%; and oscillopsia reduced by 75%. Following surgery, DBN decreased by 46%, NAFX increased by 17% in primary position over the previous peak at 10° upgaze, and visual acuity increased by 25% to 1.0+. Four-muscle surgery (including tenotomy and reattachment) reduced APN, DBN, and oscillopsia and improved NAFX and visual acuity; memantine provided additional improvement in APN. Their synergistic effect suggests a dual-mode (surgery + drug) therapy for maximal effectiveness in APN.

**Keywords:** Acquired Nystagmus, Tenotomy, Memantine

## 1. INTRODUCTION

The tenotomy surgical therapy for nystagmus, derived from ocular motor analysis of the effects of the Anderson-Kestenbaum procedure [1-3], was demonstrated to damp and otherwise improve the waveforms of infantile nystagmus syndrome (INS) [4]. Based on control-systems analysis, its was hypothesized that the mode of action is by changing the proprioceptively controlled resting tension in the extraocular muscles. We also hypothesized that tenotomy would have similar therapeutic effects on acquired forms of nystagmus as well as INS [5,6].

To test this hypothesis, we evaluated the therapeutic effects of tenotomy on two different types of acquired nystagmus: acquired pendular nystagmus (APN, Case 1) [7] and downbeat nystagmus (DBN, Case 2). The nystagmus in both Cases caused oscillopsia and reduced visual acuity. We believe that evaluation of surgical therapies for nystagmus is best

accomplished by measuring its *direct* outcomes rather than the possible idiosyncratic effects they may or may not have on improvement of visual acuity. The most accurate outcome measure of both surgical and central-peripheral drug therapies is the eXpanded Nystagmus Acuity Function (NAFX), which is a mathematical function applied to nystagmus fixation data that provides a numerical measure of waveform quality (i.e., foveation quality) [8].

## 2. METHODS

### *Subjects and Protocol*

Written consent was obtained from subjects before the testing. All test procedures were carefully explained to the subject before the experiment began, and were reinforced with verbal commands during the trials. Subjects were seated in a chair with headrest or a chin stabilizer, far enough from an arc of red LEDs to prevent convergence effects (>5 feet). At this distance the LED subtended less than 0.1° of visual angle. The room light could be adjusted from dim down to blackout to minimize extraneous visual stimuli. An experiment consisted of from one to ten trials, each lasting under a minute with time allowed between trials for the subject to rest. Trials were kept this short to guard against boredom because nystagmus intensity may vary with inattention.

Two patients, one with MS, were treated using the tenotomy procedure in conjunction with strabismus correction (Case 1) or vertical null-position correction (Case 2). Case 1, who also had a significant afferent visual deficit, was subsequently treated with memantine. The APN of Case 1 was multiplanar whereas Case 2 had only a vertical component.

### *Recording*

Eye movements were measured using either a magnetic scleral search coil (C-N-C Engineering, Seattle, WA; Case 1) or high-speed digital video (EyeLink II, SR Research Mississauga, ON, Canada; Case 2) system. We measured horizontal and vertical rotations of each eye in both Cases and the torsional and head position in Case 2. The coil system had a linear range greater than ±20° with a sensitivity of 0.1°, and crosstalk less than 2.5%. Each coil was pre-calibrated using a protractor device. The total system bandwidth was 0-100 Hz. The digital video system had a linear range of ±30° horizontally and ±20° vertically. System sampling frequency was 500Hz, gaze position accuracy error was 0.5°-1° on average, and pupil size resolution was 0.1% (0.02 mm change in diameter reliably detectable). The total system bandwidths were 0-100 Hz; the data were digitized at 500 Hz with 16-bit resolution.

The position signal for each eye was adjusted with the other eye behind cover to obtain accurate position information; the foveation periods were used for zero-adjustment (all systems) and calibration (video). Eye positions and velocities (obtained by analog differentiation of the position channels) were displayed on a strip chart recording system. Monocular primary-position calibration allowed accurate position information and documentation of small tropias and phorias hidden by the nystagmus.

#### Analysis

All the analysis and graphics were done in MATLAB environment (The MathWorks, Natick, MA) using custom-written OMtools software available from [www.omlab.org](http://www.omlab.org) ("Software and OMS Models" page). Only eye position was sampled directly; velocity was derived from the position data by a 4<sup>th</sup>-order central-point differentiator; acceleration was derived from the velocity data by the same differentiator. Position data were pre-filtered with a low-pass filter with the cutoff frequency of 50 Hz to reduce the noise while minimally affecting the data. The differentiating and filtering were applied equally to the pre- and post-data sets to ensure consistency. A mixture of voluntary and breaking saccades were picked throughout the records to provide a statistical pool at each saccadic amplitude. Only horizontal eye movements were analyzed in this study. The analysis was always performed on the fixating eye. The post-surgical records examined in this study were obtained at least 3 months after the procedure; it was reported that visual functions stabilized before this time and remained stable thereafter [5].

The eXpanded Nystagmus Acuity Function (NAFX) and the peak-to-peak nystagmus amplitude were used to measure tenotomy-induced changes in the nystagmus. The NAFX is an unbiased mathematical function based on eye-movement data that characterizes the foveation profile/quality of nystagmus waveforms. The NAFX is a unique, direct measure of the *motor effects* of therapies aimed at altering any type of nystagmus and was initially developed to evaluate patients with INS and fusion maldevelopment nystagmus syndrome (FMNS). The NAFX is linearly correlated to potential, best-corrected Snellen (decimal) visual acuity, predicts potential acuity improvement, quantifies the portion of visual acuity loss attributable to afferent deficits, and, as demonstrated in this study, predicts post-therapeutic improvements in *measured* visual acuities. A newly automated version of the NAFX software (written for MATLAB, Waltham, MA) may be downloaded as part of the OMtools software available from [www.omlab.org](http://www.omlab.org) ("Software and OMS Models" page).

Radial data, derived from the horizontal and vertical data, was used to calculate the NAFX for Case 1's multiplanar nystagmus. This *biplanar NAFX*, from fixating-eye data segments during binocular viewing, provided pre- and post-therapy comparisons. Averaged values were used to assess and estimate potential and measured visual acuity improvements. Peak-to-peak nystagmus amplitudes were also measured.

#### Surgery

The tenotomy procedure consists of detaching the muscle at the enthesial, or insertion, end of the tendon and reattaching it in the same place with absorbable sutures. (In this paper, when referring to the surgical procedures performed, the word *tenotomy* means the removal and reattachment of the tendons.)

In Case 1, horizontal tenotomy was combined with a horizontal strabismus procedure (bilateral lateral rectus muscle recessions) to alleviate an existing exotropia. In Case 2, vertical tenotomy was combined with a vertical Anderson procedure (recession of both superior rectus muscles) to move the damped region of the DBN from up gaze to primary position.

### 3. RESULTS

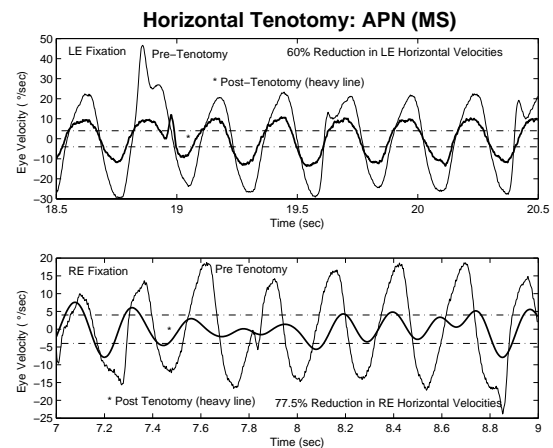
#### Case Reports

Case 1. A 50 year-old male with MS who had intractable oscillopsia for 10 years that was resistant to drug therapy. He had exotropia and diplopia and his visual acuity was between 20/100 and 20/150.

Case 2. A 44 year-old male who had intractable oscillopsia for 14 years that was resistant to drug therapy. He had DBN and a right-eye hypertropia and esotropia, resulting in oscillopsia and vertical diplopia. He exhibited a chin-down head position. His visual acuity was 20/25.

#### Eye Movements

(Case 1) Following the horizontal tenotomy + strabismus recessions procedure, APN decreased by ~50%. Figure 1 shows a segment of fixation with each eye both pre- and post-tenotomy. There was a clear reduction in both cases; the left eye being damped by 60% and the right eye by 77.5%. As a result of this damping, the image of the target was within the foveal area with low retinal slip velocity for longer durations in each cycle.

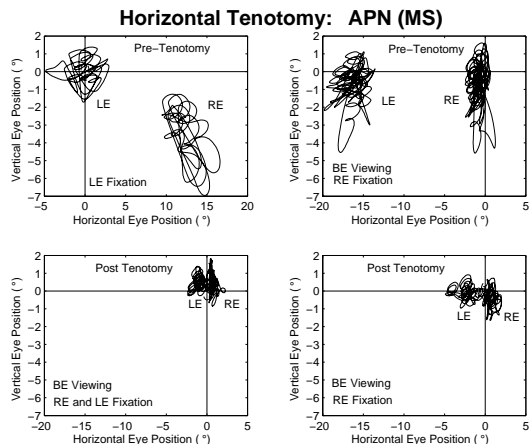


**Figure 1.** APN during left- (LE, top) and right-eye (RE, bottom) fixation pre- and post-tenotomy. Limits of clear vision retinal slip velocity ( $\pm 4^\circ/\text{s}$ ) are shown with dot-dashed lines.

The tenotomy + strabismus surgery damped the APN and reduced the exotropia. The nystagmus scan paths (horizontal vs. vertical eye position) in Figure 2 show both effects for left- and right-eye fixation. The horizontal extent of the APN in both eyes is clearly less post surgery. The strabismus correction allowed the patient to fixate with either eye more easily, resulting in more frequent changes in the fixating eye; binocular function was not restored.

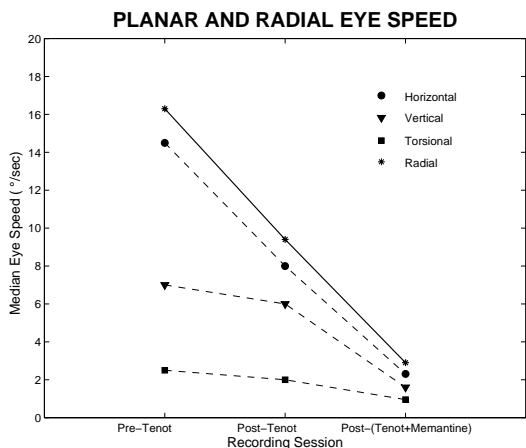
In addition to damping the horizontal component of the APN, tenotomy also damped the vertical and torsional components to a lesser degree. Figure 3 demonstrates the reduction in each plane (and radial reduction) following horizontal tenotomy.

Subsequent administration of memantine further damped the APN 69%.



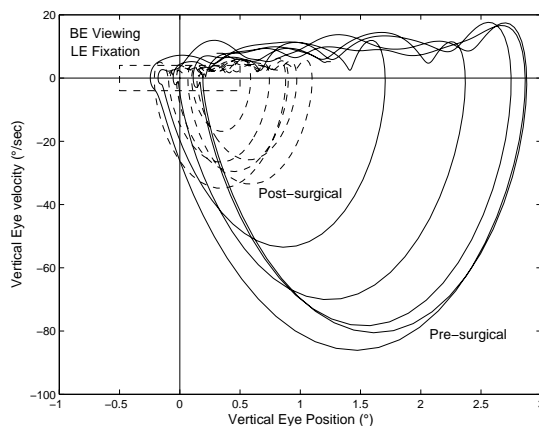
**Figure 2.** APN scan paths during left- (LE, top left) and right-eye (RE, top right) fixation pre-tenotomy and post-tenotomy (bottom).

Tenotomy increased NAFX values by 34%. Measured Snellen visual acuity increased 100% from 0.125 OD and OS to 0.25. Saccades were unaffected. The addition of memantine increased the NAFX by 9% and visual acuity by 60% to 0.4. The cumulative effects of tenotomy + memantine were: APN reduced by 82%; NAFX increased by 46%; acuity increased by 220%; and reported oscillopsia reduced by 75%. There were no substantial post-operative changes in saccadic dynamics, smooth-pursuit, optokinetic, or vestibular eye movements



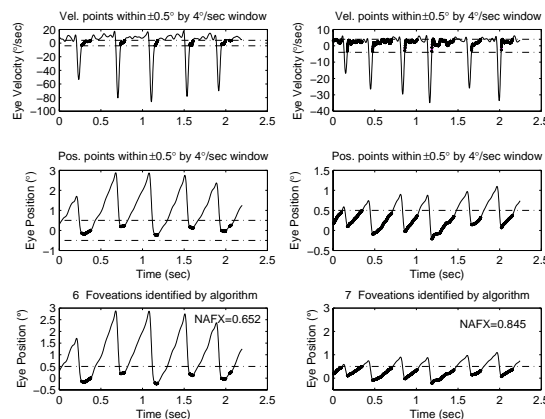
**Figure 3.** Planar and radial eye speed of APN pre- and post-tenotomy and post-(tenotomy + memantine).

(Case 2) Following the vertical tenotomy + Anderson procedure, the DBN was damped by 46%. The phase plane in Figure 4 shows the reduction of DBN and the post-saccadic foveation improvement (time spent within the foveation window).



**Figure 4.** Pre- and post-surgery phase planes of DBN during left-eye (LE) fixation with both eyes (BE) open. Foveation window ( $\pm 0.5^\circ$  by  $\pm 4^\circ/\text{s}$ ) is shown by dashed box.

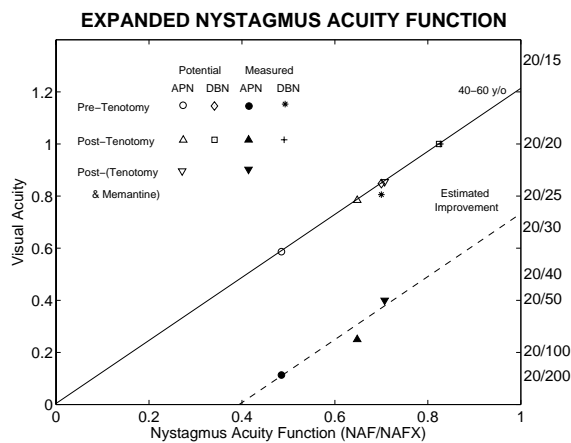
After surgery, the NAFX peak values increased 17%, foveation time-per-cycle increased 102%, the NAFX peak was moved from  $+10^\circ$  (upward) to primary position, NAFX values increased for fixation from  $-10^\circ$  (downward) to  $+5^\circ$  (broadening the high-acuity visual field), and the chin-down position was eliminated. As Figure 5 shows, the post-surgical foveation periods are longer and better aligned. The periods simultaneously satisfying the position and velocity criteria are automatically identified by the NAFX algorithm and shown as thickened portions of the output traces. The NAFX values for these intervals increased 29.6% from 0.652 to 0.845. Visual acuity improved 25% from 0.8 to 1.0+ and both reported diplopia and oscillopsia were reduced.



**Figure 5.** Pre- (left) and post-surgery (right) NAFX outputs of DBN during left-eye (LE) fixation with both eyes (BE) open. Foveation window boundaries ( $\pm 0.5^\circ$  and  $\pm 4^\circ/\text{s}$ ) are shown by dashed lines. Foveation periods satisfying the NAFX criteria are shown thickened.

#### 4. DISCUSSION

Our data from both types of AN support the hypothesis that tenotomy surgery damps AN as well as INS, for which it was designed. The direct measure of therapeutic effectiveness, the NAFX, showed increased foveation quality and improvement in potential visual acuity in both cases.



**Figure 6.** NAFX vs. visual acuity, age-adjusted line with pre- and post-surgical data points for both potential and measures acuities for both Cases.

In Figure 6, the age-adjusted NAFX vs. visual acuity line is plotted with data points for both Cases. In Case 1, with APN and afferent deficits due to MS, the vertical difference between the potential acuity corresponding to the pre-surgical NAFX and the measures value reflects the decrement in acuity due to the afferent deficits. To estimate the improvement in the patient's measures acuity after therapy (tenotomy or tenotomy + memantine), a second (dashed) line with the same slope as the age-adjusted line is drawn through the pre-surgery measured-acuity data point. Note that the intersection of this line with the NAFX value of 1.0 (i.e., no nystagmus) shows the decrement in visual acuity due solely to the afferent deficit (i.e., from ~20/17 to ~20/27).

The post-tenotomy and post-(tenotomy + memantine) measured data points fall along this second line of estimated, measured visual acuity, indicating that the afferent deficits did not change appreciably during the course of our study. In contrast to Case 1, Case 2 had no afferent deficits and the data points for potential and measured acuities fell close to each other, overlapping for the post-surgery data.

The NAFX combines a direct measurement of the outcomes of nystagmus therapies (peripheral—surgical, optical, or drug—or central—drug) with a value that is directly related to the medically desirable but more indirect measure of visual acuity. A direct measure of the cosmetic improvement of nystagmus therapy is the change in amplitude which is not always related to a change in acuity.

Because of the linear relationship between the NAFX values and the potential visual acuity of an individual with nystagmus, in the presence of a constant, or minimally changing, afferent deficit, we now have a method to use the pre-therapy NAFX value in conjunction with the pre-therapy measured visual acuity to estimate the improvement in measured visual acuity that we may expect from peripheral therapy of the nystagmus alone. In both Cases (one with afferent visual deficit and one without), the pre-operative NAFX and measured acuity values were able to predict both the best potential visual acuities (as it was designed to do) and the estimated post-operative measured acuities. Using the method outlined above for Case 1, the NAFX can be used to estimate the expected improvement in

measured visual acuity as a result of therapy in patients with nystagmus, whether or not they have additional afferent visual deficits. Thus, as has been demonstrated for INS patients with no afferent deficits, the NAFX is an accurate predictor of measured visual acuity in patients with acquired forms of nystagmus.

We have no explanation for the beneficial effects that horizontal tenotomy had on the vertical and torsional components of APN in Case 1. Such cross-plane damping suggests that motion of the globe in each plane may not be independent of motion in the other planes. The reduction of strabismus is not thought to have affected the nystagmus since binocular function was not restored. The literature does not suggest that surgical realignment of a strabismic eye affects a coexisting nystagmus. As expected, memantine reduced all components of the APN and did so independently of the prior surgery, an important dissociation in patients in whom one therapeutic measure provides insufficient improvement. Had the memantine proved ineffective, or if the patient elects to discontinue the memantine at some later date, tenotomy of the vertical rectus muscles remains a viable therapeutic option to further reduce the vertical component of the APN.

The absence of any effect on saccadic velocity supports the proprioceptive hypothesis for the action of tenotomy on small-signals (like nystagmus slow phases) where the muscles act synergistically in a linearizing push-pull fashion; during saccades, the neural signal to the antagonist muscle is turned off and only the non-linear length-tension characteristics of the agonist muscle determine the eye-movement trajectory.

In Case 2, we combined tenotomy with a vertical Anderson recession surgery to both shift the DBN “null” downward from its up-gaze position and to broaden the range of vertical gaze angles with high NAFX values; both aims were accomplished, resulting in a 17% increase in primary position NAFX and a 25% increase in primary position visual acuity.

Eye-muscle surgery (tenotomy and reattachment combined with recession) reduced acquired nystagmus and oscillopsia and improved visual acuity in both APN (Case 1) and DBN (Case 2); memantine provided additional improvement in APN. This synergistic effect in Case 1 suggests the use of dual-mode (surgery + drug) therapy for maximal effectiveness in APN. Our data suggest that oscillopsia *did not* appear to have a significant role in visual acuity reduction. In both Cases, the combination of tenotomy (a nystagmus surgery) with strabismus surgeries produced the desired improvements in both. As a result of this and prior studies, we conclude that the tenotomy surgery improves nystagmus waveforms whether it is a component of a combined nystagmus plus strabismus procedure or is done independently.

Tenotomy should be considered for therapy in cases of acquired nystagmus; unlike pharmacological treatment, it is a simple, low-risk, one-time surgical therapy with no long-term side effects.

## 5. ACKNOWLEDGEMENTS

This research was supported by the Department of Veterans Affairs Merit Reviews (lfd, rjl); NIH Grant EY06717 (rjl); Evenor Armington Fund (rjl) and NIH Training Grant EY07157 (bjb).

## 6. REFERENCES

- [1] J.R. Anderson, "Causes and treatment of congenital eccentric nystagmus," **Br J Ophthalmol**, vol. 37, 1953, pp. 267-281.
- [2] A. Kestenbaum, "Nouvelle operation de nystagmus," **Bull Soc Ophthalmol Fr**, vol. 6, 1953, pp. 599-602.
- [3] L.F. Dell'Osso, "Extraocular muscle tenotomy, dissection, and suture: A hypothetical therapy for congenital nystagmus," **J Pediatr Ophthalmol Strab**, vol. 35, 1998, pp. 232-233.
- [4] CEMAS\_Working\_Group, "A National Eye Institute Sponsored Workshop and Publication on The Classification of Eye Movement Abnormalities and Strabismus (CEMAS). In The National Eye Institute Publications ([www.nei.nih.gov](http://www.nei.nih.gov))," National Institutes of Health, National Eye Institute, Bethesda, MD 2001.
- [5] R.W. Hertle, L.F. Dell'Osso, E.J. FitzGibbon, D. Thompson, D. Yang, and S.D. Mellow, "Horizontal rectus tenotomy in patients with congenital nystagmus. Results in 10 adults," **Ophthalmology**, vol. 110, 2003, pp. 2097-2105.
- [6] R.W. Hertle, L.F. Dell'Osso, E.J. FitzGibbon, D. Thompson, D. Yang, and S.D. Mellow, "Horizontal rectus muscle tenotomy in patients with infantile nystagmus syndrome: a pilot study," **JAPOS**, vol. 8, 2004, pp. 539-548.
- [7] R.L. Tomsak, L.F. Dell'Osso, J.C. Rucker, R.J. Leigh, D.C. Bienfang, and J.B. Jacobs, "Treatment of acquired pendular nystagmus from multiple sclerosis with eye muscle surgery followed by oral memantine," **DJO**, vol. 11, 2005, pp. 1-11.
- [8] L.F. Dell'Osso and J.B. Jacobs, "An expanded nystagmus acuity function: intra- and intersubject prediction of best-corrected visual acuity," **Doc Ophthalmol**, vol. 104, 2002, pp. 249-276.