

# 11

## Nystagmus and Saccadic Intrusions and Oscillations

LOUIS F. DELL'OSSO  
ROBERT B. DAROFF

Every truth passes through three stages before it is recognized. In the first it is ridiculed, in the second it is opposed, in the third it is regarded as self-evident.

Schopenhauer

### NYSTAGMUS

Nystagmus (derived from the Greek word, *νυσταγμος*, meaning drowsiness, is derived from *νυσταζειν*, meaning "to nod in one's sleep"), the rhythmic to-and-fro oscillation of the eyes, has been regarded as enigmatic. In fact, the distinguished neuro-ophthalmologist Wilbrand once advised "never write on nystagmus, it will lead you nowhere."<sup>1</sup>

Although technologic advances have permitted quantitative insights into nystagmus analysis, the clinician should not be daunted. Many useful, often diagnostic, observations can be made by physical examination alone. Figures 1 and 2 are examples of one convenient method of diagramming nystagmus. Also, nystagmus can be further described when the globes are inspected under slit-lamp magnification or when the fundus is viewed. However, due to the complexity of nystagmus waveforms and the possibility of combinations of different types of nystagmus, only ocular motility recordings can guarantee diagnosis that is both accurate and repeatable.

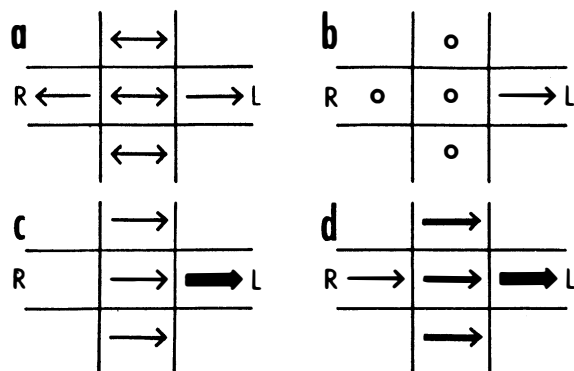
This chapter is a coalescence of the traditional neuro-ophthalmologic approach to nystagmus diagnosis and the impact of the newer capabilities of electronic eye movement recording and mathematical "biomodeling," specifically, top-down, behavioral models capable of simulating human ocular motor responses to known target inputs in the presence of nystagmus and saccadic disorders.

Eye movement recordings have allowed definition of 49 types of nystagmus (Table 1) and new insights into their pathophysiology. For precise analysis, special recording techniques are necessary, such as infrared, magnetic search-coil, or high-speed digital video recording systems, which can faithfully reproduce the eye-movement trajectories and provide accurate information on eye position without drift or noise. For quantitative purposes, all systems should record by way of direct current, with a bandwidth of 100 Hz. The eyes should be recorded separately in horizontal, vertical, and (if possible) torsional directions, with the tracing analogs written on rectilinear graph paper. Recording should be performed during fixation of visible targets and sometimes in the dark with eyes open (see Chapter 9). For detailed quantitative analysis, the data should be digitized at 200 Hz or higher.

Nystagmus has traditionally been divided into two types on the basis of the clinical impression of the waveform. Thus, if the eyes appeared to oscillate with equal speed in either direction, it was called "pendular" nystagmus; if movement in one direction was faster than in the other, it was called "jerk" nystagmus. True pendular nystagmus is sinusoidal, whereas jerk nystagmus has a slow phase away from the object of regard, followed by a fast (saccadic) phase toward the target. The direction of the fast component, by convention, defines the nystagmus direction. Only accurate recordings can often assess these criteria. Nystagmus should be described not only by its waveform and direction but also by its amplitude and frequency, the product of which is intensity. The examiner should also note the positions of gaze in which the nystagmus occurs and whether the intensity changes with gaze direction. Jerk nystagmus is usually accentuated in amplitude on gaze in the direction of the fast component, a characteristic referred to as Alexander's law.<sup>2</sup>

The field of gaze in which nystagmus intensity is minimal is termed the null zone. The neutral zone is that eye position in which a reversal of direction of jerk nystagmus occurs and in which no nystagmus, any of several bidirectional waveforms, or pendular nystagmus is present. The null and neutral zones usually, but not always, overlap. Gaze-angle nulls usually result in head postures that allow use of the null to fixate targets that are directly in front of the patient.<sup>3</sup>

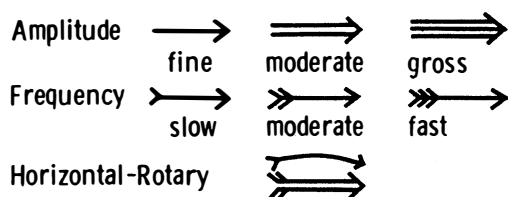
Based on quantitative eye-movement recordings, we identified three underlying mechanistic defects in the



**Fig. 1.** Simple diagrammatic method for depicting nystagmus. Two arrowheads indicate that velocity of nystagmus phases are equal (i.e., pendular). Single arrowhead indicates jerk nystagmus and points in direction of fast phase. Heavy lines indicate more intense nystagmus. **A.** Pendular nystagmus in primary position and up or down, converting to jerk on lateral gaze. **B.** First-degree jerk nystagmus present only on left lateral gaze. **C.** Second-degree jerk nystagmus beating leftward in primary position and increasing on left gaze. **D.** Third-degree leftward jerk nystagmus.

slow eye movement (SEM) subsystem (see Chapter 9) that produce nystagmus.

1. **High gain instability.** In some persons, because of abnormally high gain in the SEM subsystem, a runaway (increasing velocity) movement or a pendular oscillation is evoked. In this chapter, the term *high gain* can also imply excessive delay for the gain present (i.e., the control loop may have a normal gain, but an increased delay). Control theory suggests how particular changes in gain can result in either a pendular or a jerk nystagmus. Pendular nystagmus can be “congenital” (see section on Infantile Nystagmus Syndrome) or acquired, whereas horizontal jerk nystagmus with slow phases of increasing velocity usually is associated with congenital nystagmus; however, the latter may result from an Arnold-Chiari malformation.<sup>4</sup> Vertical nystagmus with an exponential slow phase of increasing velocity may be secondary to acquired cerebellar disease.<sup>5</sup>



**Fig. 2.** Nystagmus diagrams can be detailed and complex if one uses these symbols.

2. **Visual-vestibular tone imbalance.** The nystagmus of tone imbalance of the visual-vestibular subsystem results from the imposition of asymmetric input on an inherently normal horizontal gaze generator. This asymmetric input occurs if one vestibular apparatus (labyrinths, nerve, and brain stem nuclei) functions abnormally, if both sides are asymmetrically defective, or if there is a central imbalance of the optokinetic subsystem. The nystagmus recording always shows a linear (straight line) slow phase, reflecting a persistent tone to drive the eyes toward the side of the relatively damaged vestibular apparatus. The slow-phase amplitude is reduced by fixation and enhanced by darkness, Frenzel (high-plus) lenses, or closing the eyes. Fixation inhibition may be related to an opposing smooth-pursuit force and requires the integrity of the cerebellar flocculus.
3. **Integrator leak.** Nystagmus caused by a “leaky integrator” occurs only in an eccentric gaze position; thus, it is gaze evoked. The eyes are unable to maintain the eccentric position and drift back to the primary position with a decreasing velocity, reflecting a passive movement resisted by the viscous forces of orbital soft tissues. The defect may reside in the brain stem “neural integrator” or its connections, (such as in the cerebellum), which mediate eye deviation. This form of gaze-evoked nystagmus is called “gaze-paretic” nystagmus (see Chapter 9, Fig. 8 for an illustration of the gaze-paretic waveform).

One means of classification of nystagmus is based on whether it is a gaze-evoked or gaze-modulated type; the former category requires that there be no primary-position nystagmus. The nystagmus exhibited in two benign syndromes (infantile nystagmus and binocular maldevelopment nystagmus), physiologic types (vestibular), and symptomatic types (vestibular) fall in the gaze-modulated category. Some physiologic types (end-point) and symptomatic types (gaze-paretic) are gaze evoked. Although these concepts of a control mechanism represent useful approaches toward a more meaningful classification of nystagmus, they are far from inclusive. For practical reasons, an empirical nystagmus classification is presented that will aid the clinician in bedside and office evaluation, without the use of sophisticated recording instrumentation. This classification continues to change as our understanding of nystagmus advances. It must be emphasized, however, that such clinical diagnoses should be considered speculative and that definitive diagnosis is often only possible by means of accurate ocular motor recordings.

The localizing significance of nystagmus is often a mere indication of dysfunction somewhere in the posterior fossa (i.e., vestibular end-organ, brain stem, or cerebellum). However, certain nystagmus patterns are quite

TABLE 1. Forty-nine Types of Nystagmus\*

Acquired	Gaze-evoked	Pursuit-defect I
“fixation”	Deviational	Pursuit-system
Anticipatory	Gaze-paretic	Infantile
Induced	“Neurasthenic”	Pseudospontaneous
Arthrokinetic	“Seducible”	Induced
Induced	“Setting-in”	Rebound
Somatosensory	Horizontal	Reflex
Associated	Induced	Baer’s
Induced	Provoked	See-saw
Stransky’s	Infantile	Somatosensory
Audiokinetic	Congenital	Induced
Induced	“Fixation”	Spontaneous
Bartels’	Hereditary	Stepping around
Induced	Pursuit-system	Apparent/real
Bruns’	Intermittent vertical	Induced
Centripetal	Jerk	Somatosensory
Cervical	Lateral medullary	Torsional
Neck torsion	Lid	Rotary
Vertebral-basilar artery insufficiency	Miner’s <sup>1</sup>	Unocular
Circular/Elliptic/Oblique	Occupational	Upbeat
Alternating windmill	Muscle-paretic	Vertical
Circumduction	Myasthenic	Vestibular
Diagonal	Nucleus of the optic tract	A(po)geotropic/geotropic
Elliptic	Optokinetic	Alternating current
Gyratory	Induced	Bechterew’s
Oblique	“Kinetic”	Caloric/caloric-after
Radiary	“Optic”	Compensatory
Convergence	Optomotor	Electrical/faradic/galvanic
Convergence-evoked	Panoramic	Head-shaking
Dissociated	“Railway”	Induced
Disjunctive	Sigma	L-
Downbeat	“Train”	Labyrinthine
Drug-induced	Optokinetic after-	Perverted
Barbiturate	Induced	Pneumatic/compression
Bow tie	Post-optokinetic	Positional/alcohol
Induced	Reverse post-optokinetic	Positioning
Epileptic	Pendular	Pseudocaloric
Ictal	Talantropia	Rotational/perrotary
Fusion maldevelopment	Periodic/Aperiodic alternating	Secondary phase
Latent/manifest latent	Alternans	
Monocular “fixation”	Physiologic	
Unimacular	End-point	
Flash-induced	Fatigue	
Flicker-induced	Pursuit after-	
Induced	Induced	

\*Synonyms and other terms are indented under either the preferred or the more inclusive designation; some nystagmus types may be acquired or congenital; quoted terms are erroneous or nonspecific.

<sup>1</sup>May not exist.

specific and permit reasonably accurate neuroanatomic diagnosis. When possible, the specific and nonspecific forms are separated on the basis of clinical appearance and associated signs and symptoms.

#### NYSTAGMUS IN INFANCY

There are several types of benign nystagmus usually seen in infancy. The characteristic types of nystagmus in the Infantile Nystagmus Syndrome (INS, fka “congenital” nystagmus—CN) are the most common. Oth-

ers are the nystagmus of the Fusion Maldevelopment Nystagmus Syndrome (FMNS, fka latent/manifest latent nystagmus—LMLN) and the pendular nystagmus of the Spasmus Nutans Syndrome (SNS).<sup>6</sup> We have adopted the nomenclature recommended by the Classification of Eye Movement Abnormalities and Strabismus (CEMAS) Working Group in an attempt to eliminate the confusing and misleading terminology of some of the classical names found in the literature. The new terminology differentiates between a syndrome that includes nystagmus (often several different types of nys-

tagmus) and a specific type of nystagmus. For example, the nystagmus seen in the INS may be any combination of two or three *mechanistically different* types of nystagmus (see previous) resulting in 12 to 14 specific waveforms. Using this terminology facilitates more accurate descriptions of each type of nystagmus when required (e.g., pendular, pursuit-system nystagmus) while still allowing for the inclusion of several types found in each syndrome by simply appending the word *nystagmus* to the syndrome (e.g., INS nystagmus). Similarly, if the shorthand, "IN" is used, it too must be understood to be a *general* description encompassing all of the specific types of nystagmus possible in the INS; the same applies to "FMN."

### Infantile Nystagmus Syndrome

The nystagmus of the INS is usually present at birth or noted in early infancy at the time of development of visual fixation, and it persists throughout life. The syndrome consists of one or more types of nystagmus with characteristic waveforms, head turns, tilts, or oscillations. Rarely, the nystagmus becomes manifest later in life,<sup>7</sup> so the term *congenital* should be thought of as a congenital predisposition for this particular type of ocular motor instability, rather than taken literally. This syndrome may accompany primary visual defects, which led to the assumption that the nystagmus is secondary to poor vision and that both "sensory defect" and "motor defect" types existed. In fact, eye-movement recordings demonstrated that the specific types of nystagmus found in the INS had the same waveforms and underlying mechanism, regardless of the coincidental, perhaps facilitating, existence of a sensory deficit. The nystagmus itself is the *direct* result of an ocular motor control instability that may develop with or without an accompanying sensory deficit. Thus, for those cases in which a sensory deficit exists, it can only be a subordinate factor in the development of the nystagmus, perhaps interfering with the normal calibration of one or more of the ocular motor subsystems, thereby precipitating instability. The common association of "pendular" nystagmus with a sensory defect and "jerk" nystagmus with a primary motor abnormality was both simplistic and erroneous. Ocular motor studies of infants with INS showed no difference in waveforms associated with the presence or absence of sensory deficits; the infants exhibited the same waveforms that have been recorded in children and adults.<sup>8-10</sup> Specifically, the development of foveation periods in INS waveforms begins early in infancy as acuity and fixation develop. This is clearly seen in infrared recordings of infants when they are attending to a visual task. INS may appear spontaneously or be familial. Hereditary INS may be sex linked, recessive, or dominant; the dominant form has been linked with chromosome 6p12.<sup>11</sup>

The relationship of the visual defect to the nystagmus possibly represents simple genetic association. Although the visual problem is not causal, it may contribute to the intensity of the nystagmus. At least one form of INS nystagmus represents a high-gain instability in a SEM subsystem,<sup>12</sup> and fixation attempt (the effort to see) is its main driving force. Poor vision will increase fixation effort and increase the intensity of the nystagmus. Moreover, a subclinical motor instability may become manifest by this exaggerated visual effort. Although the exact anatomical location of the source of the instability present in INS nystagmus is unknown, we hypothesize that the various pendular waveforms (and some jerk waveforms) are due to a gain/delay problem in an internal (brain stem) feedback loop in the pursuit subsystem.<sup>12</sup> That is, the pendular nystagmus waveforms of INS stem from "pursuit-system" nystagmus, modified by the saccadic system's attempts to foveate the target and the fixation subsystem's attempt to extend foveation; this hypothesis is embodied in an ocular motor system model (see Chapter 9).<sup>13-16</sup> The much greater frequency of horizontal-torsional nystagmus, compared with vertical or diagonal nystagmus, probably reflects inherent differences in the stability of the respective pursuit subsystems (i.e., the horizontal is more unstable than the vertical). Although there is no torsional smooth pursuit system per se, the torsional component of the nystagmus reflects instability in torsional control.<sup>17</sup> Another factor in support of the hypothesis of pursuit-system nystagmus is that no oscillopsia is perceived from oscillations in pursuit velocity, not in normals and not in those with INS. Thus, no additional adaptation mechanism need be proposed to account for the absence of oscillopsia in INS; it is suppressed by the same mechanism by which normals suppress it during pursuit. Initially, we proposed that excessive positive feedback around the common neural integrator might be responsible for the accelerating slow phases of INS nystagmus.<sup>18</sup> We subsequently demonstrated that the common neural integrator is *not* the site of the INS instability.<sup>19</sup> However, several models have been proposed that attempt to explain the genesis of some INS waveforms, based on that premise.<sup>20-22</sup> Although each can generate limited, specific INS waveforms, the models exhibit behaviors inconsistent with data from individuals with INS and do not simulate the known broad range of human ocular motor responses (both normal and during nystagmus) to common stimuli (i.e., they are demonstrations of putative mechanisms to generate waveforms rather than models capable of simulating ocular motor system behavior). Because IN appears to be activated and intensified by fixation attempt, the deficit may also be linked to the fixation subsystem (see Chapter 9). The coexistence of a high-frequency pendular oscillation with a low-frequency jerk nystagmus (resulting in a

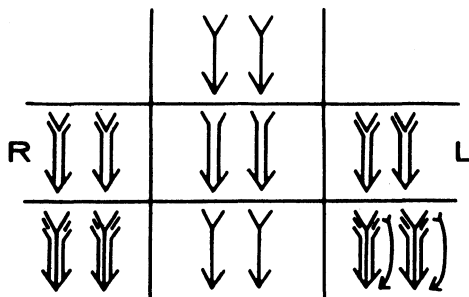
dual-jerk waveform) in some INS subjects and also in FMNS, suggests that the high-frequency pendular oscillation is due to an instability at a *different* site. Recent evidence points to the nucleus of the optic tract (NOT) as the site of this oscillation shared by patients with either the INS or FMNS.<sup>23</sup> Goldstein suggested that IN is caused by oscillations at two frequencies whose interactions may approximate some of the known INS waveforms.<sup>24</sup> However, such interactions do not produce the absolutely motionless (i.e., “flat”) periods of extended foveation (300–400 msec) recorded in many patients.

Distinguishing the lower frequency pendular nystagmus from jerk nystagmus may be difficult clinically, particularly in the INS. Certain forms of jerk nystagmus are invariably mislabeled as pendular, or the direction is misidentified. Even with oculographic recordings, the direction of the fast phase may be misinterpreted unless velocity tracings are obtained.<sup>25</sup> In the absence of oculography, clinicians should describe the nystagmus carefully or use diagrammatic methods (see Figs. 1–3). Monocular visual deprivation induced, in some monkeys, a diagonal nystagmus whose horizontal component initially looked like FMNS slow phases (see later discussion) and then developed to resemble INS slow phases. This deprivation took place from birth to 25 days and was followed by monocular deprivation of the other eye.<sup>26</sup> The role of the NOT in FMN in monkeys has been more clearly defined recently.<sup>27,28</sup>

The INS nystagmus usually damps significantly with convergence. Although the exact mechanism responsible for this damping is unknown, there was speculation that it might result from co-contraction of antagonist muscles of *each* eye during convergence. However, recent work by Miller found no co-contraction.<sup>29</sup> We hypothesized that damping during convergence might re-

sult from an effective increase in the stiffness of the ocular motor plant brought about by the increased innervation to the two medial recti. (i.e., co-contraction of antagonist muscles of the *two* eyes, rather than of *each* eye). The Orbit 1.8 simulation (J. M. Miller, personal communication), predicted that the 8 g primary-position tension in the medial rectus increased to 13 g at 20° adduction (40° of convergence) and to 18 g at 30° adduction (60° of convergence), 75% and 125% increases, respectively. Because convergence results in a change in the muscle pulley system,<sup>30,31</sup> the latter may be the mechanism by which the stiffness is increased. The observations of convergence-induced damping of other types of nystagmus support this peripheral mechanism in preference to one relying on an inherent property of the nystagmus. As previously mentioned, the intensity of INS nystagmus is related to the fixation attempt, which probably explains why it sometimes persists with eyes open in darkness (when the subject will probably attempt to “see”) and damps behind closed lids (when the subject will, unless instructed to the contrary, reduce any attempt to “see”).<sup>25</sup> The defining criterion is fixation attempt, *not* retinal illumination or lid position. Therefore, reports of the presence or absence of nystagmus with lid closure or darkness that lack a description of the instructions to the subject, provide little useful information.

The recognition of INS is of extreme importance, particularly in the adult patient, and may obviate unnecessary neurodiagnostic procedures; its characteristics are listed in Table 2. INS is almost always binocular and never shows more than minor amplitude dissociation between the two eyes. Clinically, the nystagmus usually appears uniplanar. Like vestibular end-organ nystagmus, horizontal nystagmus remains horizontal when the eyes are deviated vertically and does not convert to vertical nystagmus. Using new, sensitive techniques for recording torsional eye movements, we found small but significant torsional components in the nystagmus of subjects previously thought to have purely horizontal INS.<sup>17</sup> Because the prominent horizontal movement



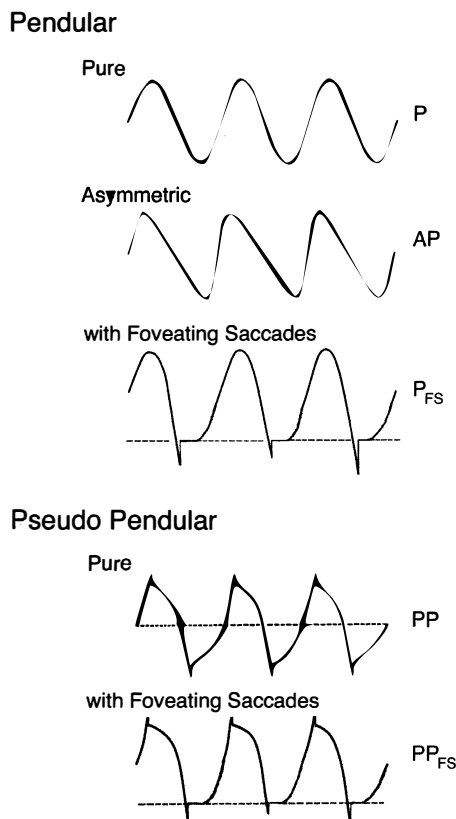
**Fig. 3.** A typical downbeat nystagmus that is maximum in frequency and amplitude on eccentric and downward gaze. The nystagmus is absent during up and left gaze and up and right gaze; it is minimal during straight up or straight down gaze. In primary position the downbeating nystagmus is moderate in amplitude and slow in frequency. The frequency but not the amplitude increases on gaze right and left. On oblique downward gaze both amplitude and frequency increase, and on down and left gaze the eyes have a mixed pattern combining vertical and rotary components.

**TABLE 2. Characteristics of Infantile Nystagmus**

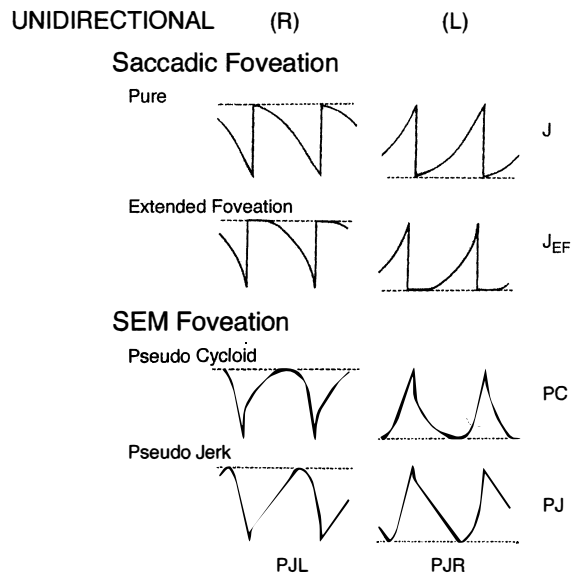
Binocular with similar amplitude in both eyes
Usually horizontal and torsional (vertical rare)
Pendular or increasing velocity slow phases
Distinctive waveforms with foveation periods and braking saccades
Asymmetric aperiodic alternation possible (Baclofen ineffective)
Provoked or increased by fixation attempt
Abolished in sleep or inattention to visual tasks
Gaze-modulated, not gaze-evoked
Diminished (damped) by gaze-angle or convergence nulls
Superimposition of latent component possible
“Inversion” of the optokinetic reflex (actually, reversal of the IN)
Associated head oscillation (not compensatory) or turn
No oscillopsia except under rare conditions

masks the usually smaller torsional component, the latter appears to be a common characteristic of “horizontal” INS. In most patients, rightward movements were accompanied by clockwise torsion and leftward movements by counterclockwise torsion.<sup>32</sup> We discuss later the superimposition of a latent component on an ongoing IN.

Eye-movement recordings of INS occasionally show a pure pendular waveform (sinusoidal) or a saw-toothed waveform (equiamplitude linear slow phase with foveating saccade) (see Fig. 8) typically seen in vestibular nystagmus. These pure forms are neither frequent nor pathognomonic for INS. More often, INS manifests distinctive waveforms that are not present in acquired nystagmus. These waveforms are an expression of the at-

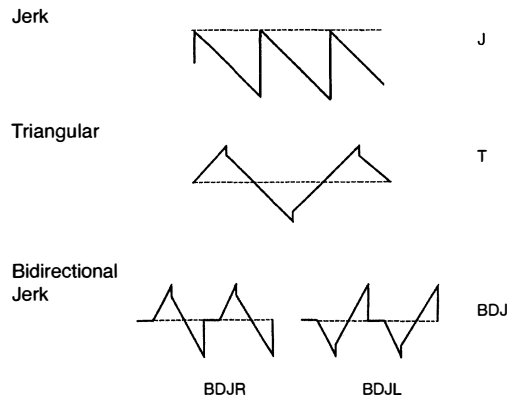


**Fig. 4.** Variations of pendular nystagmus due to pursuit-system instability: pure (P), asymmetric (AP), pendular with foveating saccades ( $P_{FS}$ ), pseudopendular (PP), and pseudopendular with foveating saccades ( $PP_{FS}$ ). Note that although foveating saccades vary in amplitude, all achieve foveation (i.e., they all return the eyes to same point, the target). Foveation takes place at the peaks that are more flattened; here shown as the leftmost peaks. In this and Figures 5 through 7 and Figure 16, dashed lines indicate target position (see text). In all figures, upward deflections indicate rightward, upward, or clockwise eye movement (all eye movements are from the patient's perspective).



**Fig. 5.** Unidirectional types of jerk nystagmus, mechanism unknown, including two with saccadic foveation (pure jerk and jerk with extended foveation) and two with slow eye movement (SEM) foveation (pseudocycloid and pseudojerk). The increasing velocity slow phases are common in IN. Note small and variable saccadic amplitude in pseudocycloid waveform and further reduction in pseudojerk waveform.

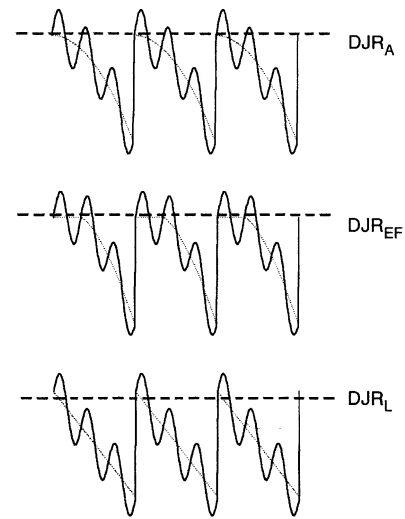
tempts by the ocular motor control system to increase foveation time, imposed on inherently unstable slow control. The INS waveforms shown in Figs. 4 through 7 (other than pure pendular or jerk) have never been recorded in acquired horizontal nystagmus.<sup>8,33</sup> The target position is indicated by a dashed line; target position is problematic for pure and asymmetric pendular waveforms. We have regrouped the original waveforms based on hypothesized mechanisms to emphasize the different types of nystagmus that may be recorded in an individual with INS. This resulted in differentiating linear slow phases from the more common accelerating slow phases of jerk nystagmus, based on presumed mechanisms (visual-vestibular and pursuit-system, respectively). The presence of dynamic overshoots in the fast phases (saccades) of IN waveforms is both idiosyncratic and variable; for simplicity, we have not included them in Figures 4 through 7. Because dynamic overshoots are not an abnormality, their presence does not represent a “different” waveform. Using our computer model,<sup>14,16</sup> we demonstrated how the pendular waveforms in Figure 4 could be generated from a pursuit-system instability, and we are investigating two possible sources for the unidirectional jerk waveforms in Figure 5. We hypothesize that the linear-slow-phase jerk waveforms in Figure 6 arise from a tonic imbalance in the



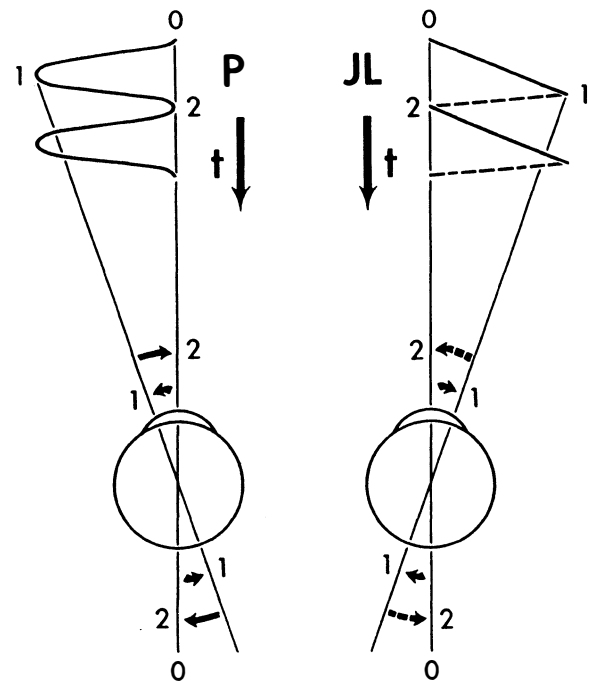
**Fig. 6.** Unidirectional (jerk, J) and bidirectional (triangular, T and bidirectional jerk, BDJ) nystagmus with linear slow phases hypothesized to be due to visual-vestibular imbalance. All saccades are in a corrective direction (i.e., toward target).

visual-vestibular subsystem. When the low-amplitude, high-frequency pendular oscillations, hypothesized to arise in the NOT, are present, they are superimposed on the basic IN waveforms as shown in Figure 7. Of the 15 waveforms shown in Figures 4 to 7, we hypothesize that nine are due to pursuit-system oscillation (Figs. 4, 5), three to visual-vestibular imbalance (Fig. 6), and the three in Figure 7 to NOT nystagmus added to either type. We have also recorded the high-frequency NOT nystagmus superimposed on a low-frequency pendular IN. Twelve of these waveforms are pathognomonic of IN; P, AP, and J<sub>L</sub> are not. One important feature of IN waveforms is the presence of “braking saccades” that act to stop runaway slow phases.<sup>34</sup> They are triggered by extraretinal eye-velocity information and, when properly measured, have the same velocity and duration characteristics as other types of saccades.<sup>35,36</sup> For pendular waveforms, the target is foveated at the peaks that are more flattened, indicating extended foveation. Extended foveation in an adult with lifelong nystagmus secondary to a congenital brain stem hamartoma and in an adult given gabapentin for treatment of nystagmus secondary to an arteriovenous malformation<sup>37</sup> supports the hypothesis that extended foveation periods in INS waveforms represent the action of a normal fixation system on the underlying INS oscillation. Figures 8 and 9 demonstrate how these waveforms serve to increase the time of foveal imaging.

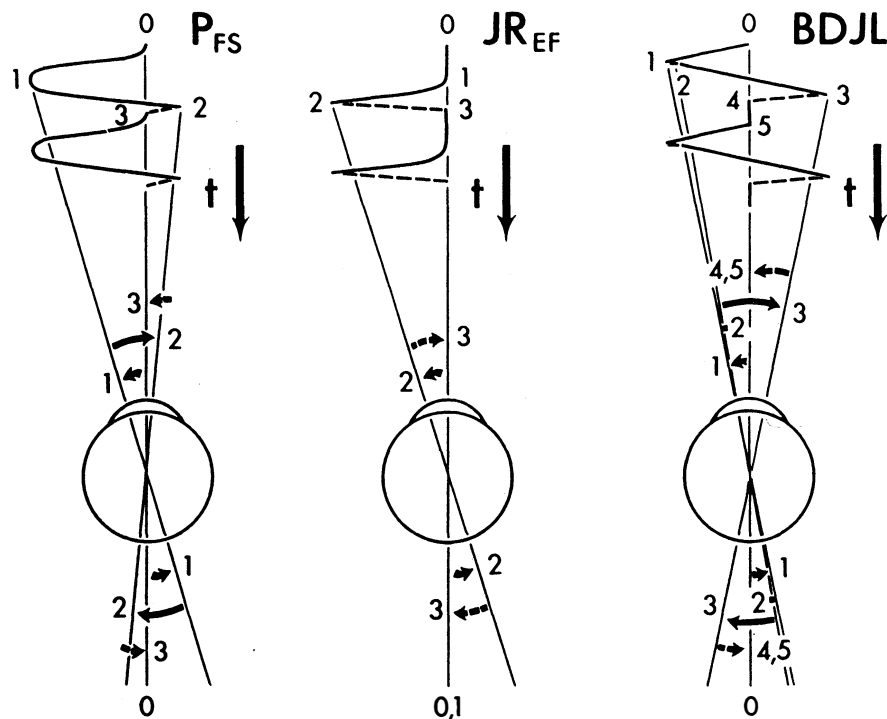
The pure pendular (P) and jerk (J) waveforms in Figure 8 are not conducive to good acuity because of the extremely short foveation time (instants 0 and 2 on the time axis). Although these are common acquired waveforms, when afflicted with INS, the developing nervous system modifies pendular and jerk waveforms; therefore, foveation time (and thus acuity) is increased. Ex-



**Fig. 7.** Dual jerk nystagmus hypothesized to be comprised of NOT nystagmus superimposed on IN waveforms shown in Figures 5 and 6. The resulting waveforms show sinusoidal modulation of the underlying slow eye movement off target. Depicted are dual jerk right with accelerating slow phases (DJR<sub>A</sub>), dual jerk right with extended foveation (DJR<sub>EF</sub>), and dual jerk right with linear slow phases (DJR<sub>L</sub>).



**Fig. 8.** Foveation “strategy” employed during pendular (P) and jerk left (JL) nystagmus. The target is only briefly foveated at points 0, 2, and so forth. *t*, time scale.



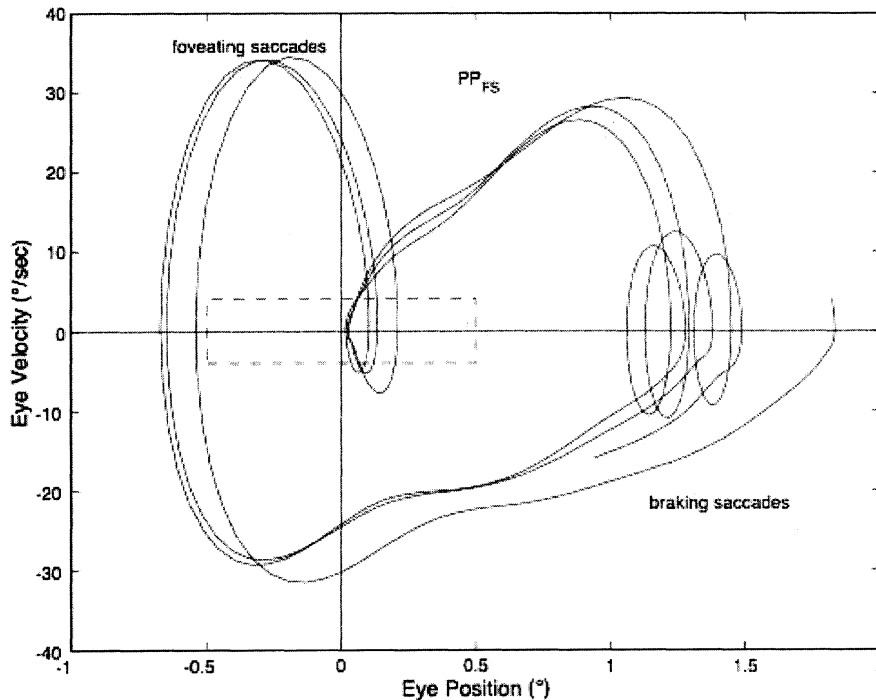
**Fig. 9.** Foveation “strategy” used during pendular nystagmus with foveating saccades ( $P_{FS}$ ), jerk right with extended foveation ( $JR_{EF}$ ) nystagmus, and bidirectional jerk left (BDJL) nystagmus. The longer the target is foveated, the better will be the good acuity.  $t$ , time scale.

amples of some resultant waveforms are shown in Figure 9. In the pendular nystagmus with foveating saccades waveform ( $P_{FS}$ ), there is usually a substantial period of time when the target is imaged on the fovea and the eye is motionless (instant 3 on the time axis). In jerk-right nystagmus with extended foveation ( $JR_{EF}$ ), the position from time 0 to 1 is when foveation takes place, and in the bidirectional jerk-left (BDJL) waveform, the position from instants 4 to 5 is conducive to good acuity. Waveform, gaze-angle nulls, and convergence nulls are affected by heredity.<sup>38</sup> Members of the same family show more specific combinations of waveforms or of either waveform, having only a convergence null or no convergence null (i.e., having only a gaze-angle null), than do members of the general INS population. We found greater damping of INS nystagmus with convergence than with gaze angle, in patients who exhibited both types of null, and this translated into acuity increases.<sup>39</sup> Comparison of the results of the Anderson-Kestenbaum and artificial divergence procedures also favored the latter.<sup>40</sup>

Increased foveation time is *the most effective* determinant of increased acuity.<sup>41–44</sup> In most INS subjects, the best waveform (i.e., most foveation time per cycle) is in the null region associated with a particular gaze or convergence angle, but in other subjects it is not; these latter subjects prefer the gaze or convergence angle that yields the best waveform, even if it is not the waveform

with the least amplitude. Decreased amplitude is, however, the major determining factor in cosmetic improvement and is appreciated by a young patient’s parents. Despite a nulling of the nystagmus, an individual with INS may not show an increase in acuity with convergence if the resulting waveform has little foveation time per cycle or if acuity is primarily limited by a visual deficit. The fixation system of someone with INS is able to repeatedly foveate a target within minutes of arc, almost as accurately as a normal person.<sup>39,42,45</sup> The use of phase-plane analysis allows definition of a “foveation window” ( $\pm 0.5^\circ$  by  $\pm 4.0^\circ/\text{second}$ ) for the study of fixation, smooth pursuit and the vestibulo-ocular reflex (VOR).<sup>39,46,47</sup> These studies demonstrate the extremely accurate fixation, pursuit, and VOR possible in individuals with INS. In Figure 10, the tight overlap of foveation periods within the foveation window in the phase plane demonstrates how accurate the cycle-to-cycle target foveation in IN can be. The foveation window defines the time when the eye is within  $\pm 0.5^\circ$  of the target and moving with less than  $\pm 4^\circ/\text{sec}$ . Thus, despite an ocular oscillation whose amplitude is well outside the foveal extent and whose velocity exceeds  $\pm 30^\circ/\text{sec}$ , the ocular motor system can foveate the target with extreme accuracy and allow normal visual acuity.

The nystagmus acuity function (NAF) provides an objective determination of potential visual acuity from



**Fig. 10.** Phase plane of the horizontal component of three cycles of a typical IN with a  $PP_{FS}$  waveform. The dashed rectangle indicates the  $\pm 0.5^\circ$  by  $\pm 4^\circ/\text{sec}$  boundaries of the foveation window. Note the accuracy ( $< 1$  minarc) of foveation. The vertical loops ("rabbit ears") are the foveating (rightward) and braking (leftward) saccades. Phase-plane trajectories move clockwise when conventional eye-movement directions are used (i.e., rightward is positive).

measurements of the key characteristics of the INS waveform: foveation time and the standard deviations of foveation position and velocity means (for NAF) or position mean alone (NAFP).<sup>48</sup> For those subjects whose foveation ability is not well developed (i.e., the target image always falls within the default foveation window), the window used for its calculation can be enlarged and the expanded NAF (NAFX) plotted versus gaze or convergence angle. Software is now available that calculates the NAFX from eye-movement data and provides a quantitative method for evaluating different therapies for their affect on potential visual acuity.<sup>49</sup> Plots of the NAF or NAFX versus visual acuity reveal the linear relationship that allows intersubject prediction of potential visual acuity. The NAFX can also be used to compare potential acuity across subjects with different types of nystagmus (INS or FMNS) or to predict the acuity increase possible after therapeutic intervention in a given subject. The latter is accomplished by plotting the NAFX versus gaze or convergence angle. Figure 11A shows the NAFX outputs during near and far fixation from a subject with achiasma, recorded in Laboratory of H. Collewijn in Rotterdam (see Albinism and Achiasma section following).<sup>50</sup> As the NAFX clearly shows, conditions for highest visual acuity occurred during near fixation where (as the bottom panels show) a smaller foveation window could be used to calculate the NAFX. Figure 11B shows the pre- and post-tenot-

omy NAFX outputs from an achiasmatic Belgian sheepdog, demonstrating the effectiveness of the treatment. As the bottom panels show, the post-tenotomy nystagmus is subclinical and well within the boundary of the area centralis; the nystagmus during the whole interval qualified as a foveation period. Figure 11C shows the NAFX versus potential (solid and dashed lines) and measured (symbols for the human data) visual acuity for two humans (S1 and S2) and a canine (S3). The NAFX (and, potential visual acuity) is higher at near than at far (S1 and S2) or while using base-out prisms at far (S1). For the canine, the post-tenotomy NAFX is higher than preoperatively, and the dashed line is inferred from veterinary data. Because of its direct relationship to potential visual acuity, the NAFX is the best available outcome measure of therapies designed to affect the IN waveform. Although amplitude is related to cosmetic appearance, neither it nor frequency is closely correlated with acuity.

We hypothesized a new type of surgery to damp the IN of subjects that do not have gaze-angle, convergence or static nulls (i.e., they have asymmetric (a)periodic alternating nystagmus—APAN) or do have a primary-position null.<sup>51</sup> The surgery consists of a simple tenotomy, dissection, and suture of the involved extraocular muscles in place, with neither recession nor resection. Results of a masked clinical trial of this surgery were positive in a phase 1 study of adults.<sup>52,53</sup> The putative

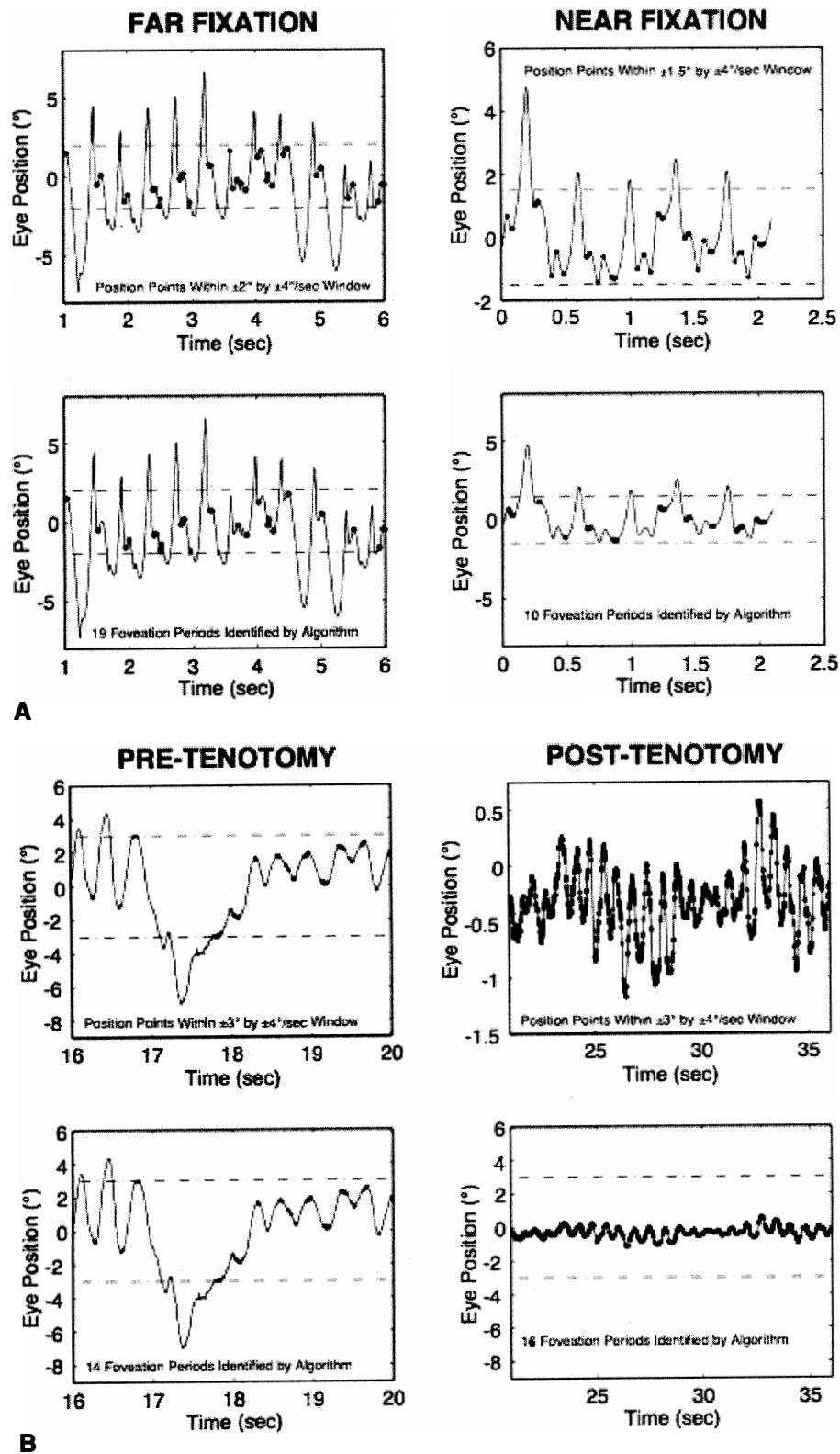
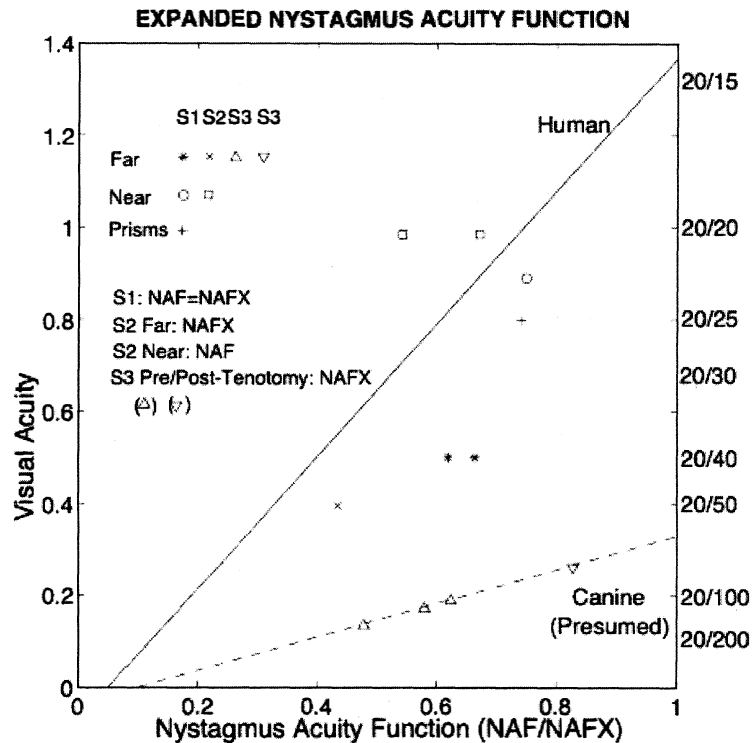


Fig. 11. A,B. See legend on opposite page.



**Fig. 11.** (A) The expanded nystagmus acuity function (NAFX) output for a subject with achiasma during far and near fixation, demonstrating improvement at near by the smaller foveation window and lower variation of foveation position. (B) The NAFX for an achiasmatic Belgian sheepdog demonstrating dramatic post-operative improvement by the relative sizes of the nystagmus and the  $\pm 3^\circ$  centralis window. (C) NAFX versus visual acuity for both humans and canines, demonstrating improvement at near fixation (humans S1 and S2), at far with base-out prisms (S1), and post-tenotomy (canine S3). In this and Figures 12, 13, and 18B, the dot-dashed lines indicate the extent of the foveal window (humans) or area centralis (canines). In this and Figure 12, the thickened areas identify foveation (human) or centralis (canine) periods.

mechanism responsible for the damping effects of tenotomy is alteration of a proprioceptive tension-control loop.<sup>51</sup> This is supported by the discoveries of the neural substrate for such a loop in both the musculotendon<sup>54-57</sup> and enthesial end of the tendon (where the surgery takes place).<sup>58</sup> Before any surgery is contemplated, IN should be definitively diagnosed using ocular motility recordings.<sup>59</sup> Figure 12 shows the improvement in NAFX output of a patient after four-muscle tenotomy. As the increased NAFX values indicate, tenotomy damped the IN and improved the waveform. Both the foveation time per cycle and the mean foveation position improved and the post-tenotomy foveation window was smaller in both position and velocity. The various therapies available for INS, based on the presence or absence of gaze and convergence nulls, is summarized in Table 3. Note that for patients with both convergence and gaze-angle nulls, exploitation of the former (surgically or with vergence prisms) usually damps the nystagmus and increases acuity most; it is necessary to add  $-1.00$  S (OU) to vergence prisms for prepresbyopic patients. Preliminary studies (at all gaze angles) of the broad damping effects of convergence on IN (see Fig. 14 and discussion of convergence following) suggest that composite prisms (unequal base-out) are not necessary in these cases; vergence prisms (equal base-out) will achieve the same damping.<sup>60</sup> As indicated in Table 3, regardless of

the presence of nulls, afferent stimulation can be used in all patients who exhibit nystagmus damping with active stimulation (see later discussion).

The so-called inversion of the optokinetic reflex seems to occur only with INS.<sup>61</sup> When optokinetic stimuli are presented to a patient with INS, a peculiar phenomenon may occur: the resulting nystagmus may be opposite in direction from what would be anticipated if the evoked optokinetic nystagmus (OKN) simply summed with the ongoing nystagmus. For example, in the presence of left-beating INS nystagmus, the response to right-going optokinetic targets (a leftward fast phase) should add to the left-beating INS nystagmus to produce enhancement of the nystagmus intensity. In "inversion," the nystagmus may either damp or be converted to right-beating nystagmus. If right-going targets are presented at a gaze angle at which the nystagmus is either absent or pendular, a right-beating nystagmus may result. Inversion of the optokinetic reflex is present in 67% of INS patients. The observation of optokinetic inversion establishes the nystagmus as IN. The phenomenon is, in reality, merely a reversal of the INS nystagmus direction due to a null shift; it is *not* a true inversion of the optokinetic response (see discussion of reversed pursuit later). The basic function of the optokinetic system is to stabilize slowly moving retinal images, but the rapidly moving retina of an INS patient may interfere

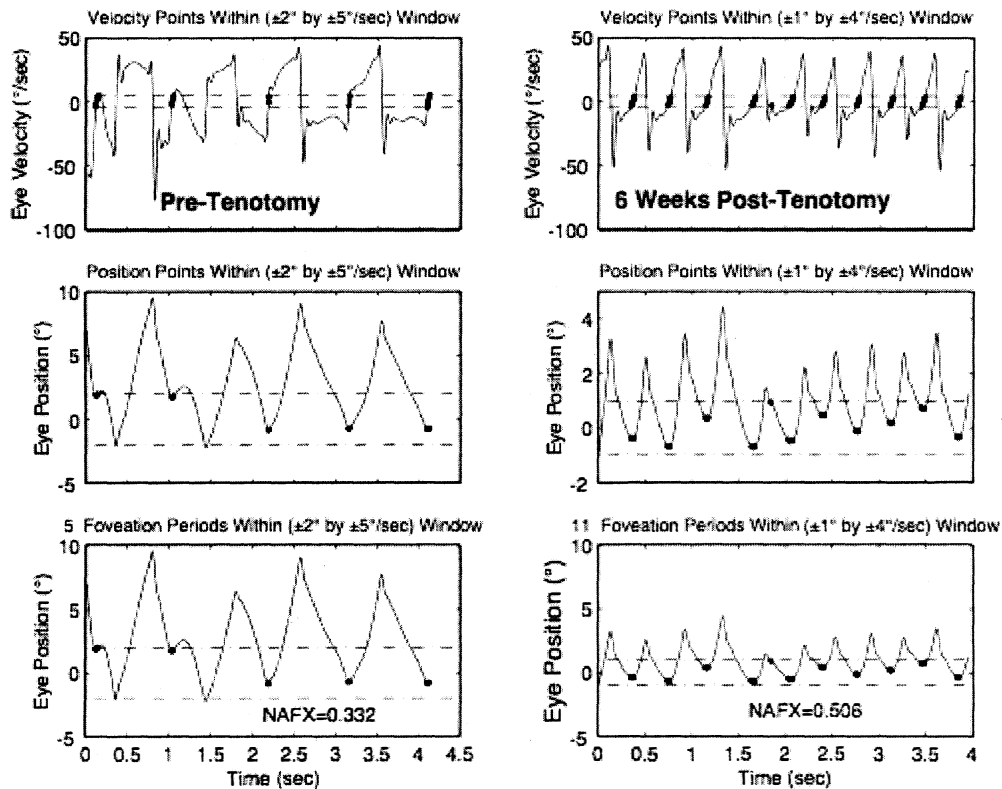


Fig. 12. Comparison of NAFX outputs in a patient who underwent a four-muscle tenotomy procedure. Both the foveation time per cycle and accuracy of foveations (smaller foveation window) improved, resulting in the 67% higher NAFX value.

TABLE 3. Therapies for Infantile Nystagmus

<i>If the IN nulls ONLY with lateral gaze:</i>	
Resection and recession (four-muscle)	
Version prisms	
Afferent stimulation (passive or active)	
<i>If the IN nulls ONLY with convergence:</i>	
Bimedial recession <sup>1</sup> (artificial divergence) plus bilateral tenotomy	
7D BO vergence prisms with (1.00 S <sup>1</sup> (OU)	
Afferent stimulation (passive or active)	
<i>If the IN nulls with BOTH lateral gaze and convergence:</i>	
Bimedial recession <sup>1</sup> plus bilateral tenotomy or combined with resection and recession	
7D BO vergence prisms with (1.00 S <sup>1</sup> (OU)	
Afferent stimulation (passive or active)	
<i>If the IN nulls with NEITHER lateral gaze nor convergence or is asymmetric aperiodic alternating IN:</i>	
Four-muscle tenotomy, dissection and suture	
Maximal recession (Four-muscle)*	
Afferent stimulation (passive or active)	

<sup>1</sup>Damps IN only for nonstrabismic, binocular patients.

\*This surgery should be replaced by the four-muscle tenotomy procedure that does not carry the risk of inducing diplopia.

with this function. The optokinetic response appears suppressed in some patients; however, the perceived circularvection is in the proper direction, and OKN dynamics appear to be normal in individuals with INS.

The head oscillations that often accompany INS increase with visual intent and have traditionally been regarded as compensatory. For compensation to be achieved, head movements would have to be equal in amplitude and opposite in direction to the eye movements. For such a mechanism to work, the VOR would have to be totally inhibited (gain reduced to 0). Accurate objective observations of the head movements in patients with INS do not support that hypothesis.<sup>62</sup> Rather, the head oscillation is merely an extension of the motor instability, and the VOR functions normally to cancel the effects of head oscillation during the periods of target foveation normally present in the INS waveform.<sup>47</sup> The head tremor in INS can be distinguished from that in acquired disease; it is easily suppressed voluntarily in the former but not in the latter.

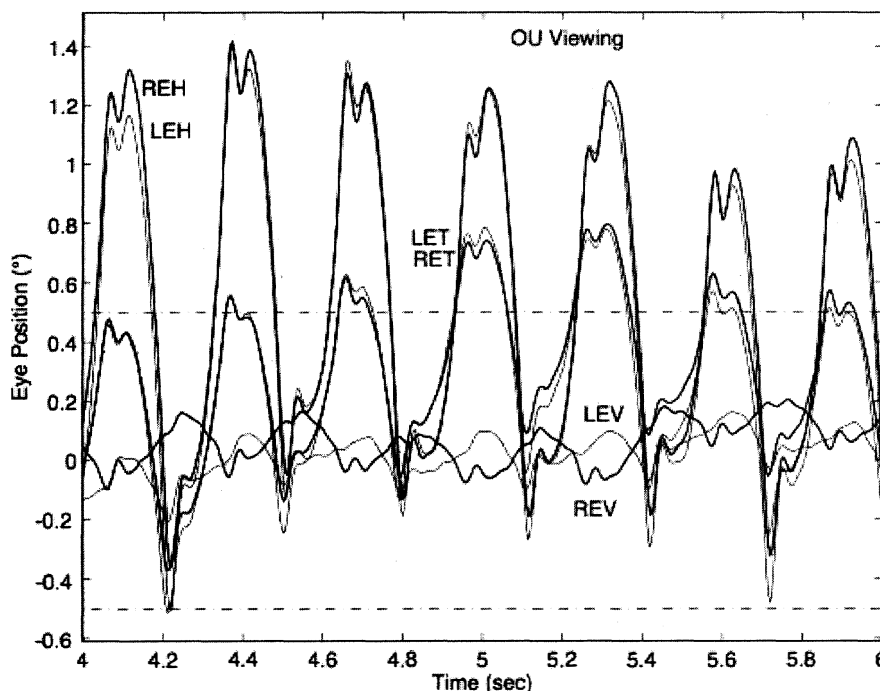
Point out the head tremor to the patient. If it stops, the nystagmus is IN; if it persists, both are acquired.

Individuals with INS usually do not experience an illusory oscillatory movement of their environment (oscillopsia).<sup>63,64</sup> This lack of oscillopsia in INS, and also in FMNS, suggests that both oscillations occur within an efference copy feedback loop that serves to nullify the effects of retinal-image oscillation induced by either of these instabilities.<sup>65</sup> Like most ocular oscillations (myoclonus being the exception), INS nystagmus disappears in sleep. In two patients with INS plus an acquired nystagmus, their acquired oscillopsia seemed to be related to an inability to maintain repeatable periods of good foveation in a particular plane.<sup>66,67</sup> However, that inability was an epiphenomenon caused by the addition of a transitory acquired nystagmus to the ever-present INS nystagmus.<sup>65</sup> Oscillopsia suppression in INS and other types of nystagmus appears to be accomplished by efference copy of the nystagmus signal.<sup>65,68-72</sup> Oscillopsia may occur in some patients with very poor foveation stability<sup>73</sup> or may occur in later life secondary to afferent deficits.<sup>74</sup> The thresholds for motion detection in INS differ from normal and may also play a role in oscillopsia suppression.<sup>75,76</sup> We reported oscillopsia of a migraine aura in an individual with INS,<sup>77</sup> as well as vertical oscillopsia secondary to a decompensated phoria; the latter event led to the discovery of subclinical see-saw nystagmus in the horizontal-torsional waveforms of IN.<sup>78</sup> As Figure 13 shows, the subclinical see-saw nystagmus is phase locked with the horizontal and torsional components allowing foveation periods to

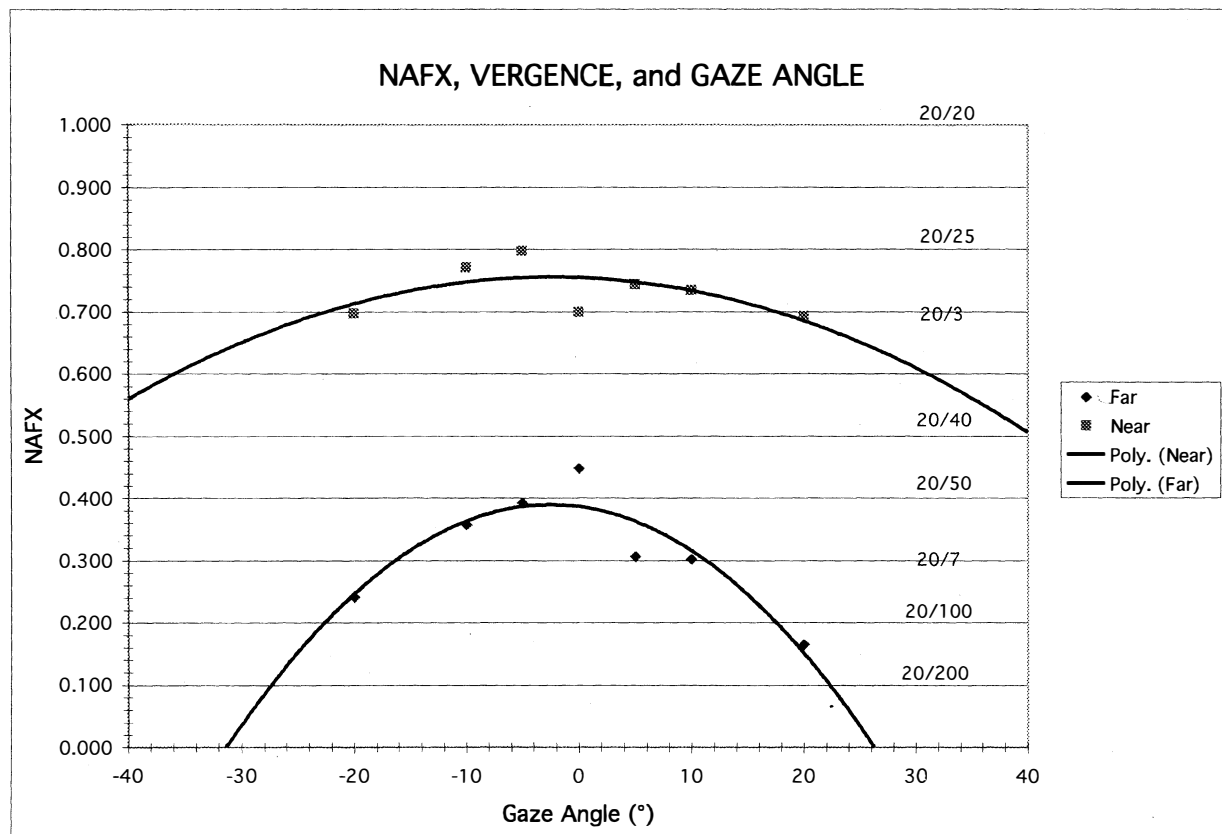
occur in all planes simultaneously. Torsional motion does not seem to impair orientation perception thresholds, perhaps due to extraretinal information.<sup>79</sup> We hypothesize that subclinical see-saw nystagmus results from slight mismatches between the forces exerted by the vertical recti and oblique muscles and does not represent a true vertical-system instability; this contrasts with the see-saw nystagmus accompanying achiasma (discussed later).

During fixation of stationary targets, many individuals with INS have a permanent null region representing the gaze angle at which the intensity of the nystagmus is the lowest and the waveform most conducive to highest NAFX and acuity. They often turn their heads to permit straight-ahead viewing with the eyes in the null region. Such patients benefit from appropriate version prism spectacles that alleviate the necessity for the head turn and the resulting increased fixation attempt.<sup>25,41</sup> However, as Figure 14 shows, if the IN damps with convergence, the higher NAFX values will persist over a broader range of gaze angles than during fixation on a far target. This allows higher acuity over most useful gaze angles and demonstrates the advantage of either base-out prisms or the bimedial rectus recession procedure over therapies aimed at moving a gaze-angle null to primary position.

Some INS patients may exhibit a superimposed latent component that induces null shifts toward an eye that is covered (Fig. 15).<sup>80</sup> Demonstration of such a shift



**Fig. 13.** Tri-planar recording of a typical IN with a PPFS waveform showing the relative size and phase relationship of the subclinical see-saw component of IN to the more prominent horizontal and torsional components. Note the correspondence of the foveation periods in all planes. In this and Figures 18 and 19, heavier lines indicate right-eye motion.



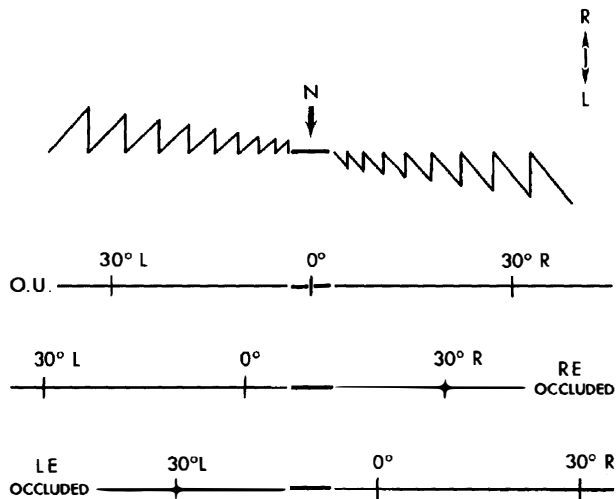
**Fig. 14.** NAFX versus gaze angle and fitted polynomial curves for both far and near fixation with best potential visual acuities indicated. Note the dramatic increase with convergence and the broader range of gaze angles with higher potential acuities.

and maintenance of any of the INS waveforms establish the nystagmus as belonging to INS rather than the FMNS (see later discussion). Rarely, a null shift is toward the viewing eye.<sup>25</sup>

Some studies of INS and smooth pursuit have led to confusion between the reversal of INS direction that may occur during pursuit and reversed pursuit. This confusion is similar to that discussed earlier for the optokinetic response. Accurate eye-movement recordings show that *neither* the optokinetic nor the pursuit subsystem responds in a reversed manner, as should be obvious both by the absence of any symptoms of such a grave deficit and the normal abilities of individuals with INS in sports. Also, their perceptions of both the direction and magnitude of movements in the periphery and on the fovea are normal. Just as the INS waveform is distorted by SEM (creating periods of extended foveation) during fixation of a stationary target, the pursuit system is able to generate pursuit movements with a direction and velocity that match those of a moving target during

these same periods of the INS waveform.<sup>46,68,81</sup> This ensures extended foveation of the moving target and results in accurate smooth pursuit during the periods when the target image is on the fovea. Pursuit during foveation is all that is necessary for good acuity; the same conditions are met during smooth pursuit as are met during fixation of a stationary target. During smooth pursuit (or during optokinetic or VOR stimuli) the gaze angle at which the INS null region occurs shifts in the direction opposite to the pursuit (optokinetic grating or VOR-induced eye motion).<sup>46,47</sup> The amount of null shift is a function of the pursuit or VOR velocity. This measurable shift in the INS null angle causes the INS nystagmus reversal that has been mistakenly equated with "reversed" responses of both the optokinetic and pursuit subsystems.

In many individuals with INS, afferent stimulation of the ophthalmic division of the trigeminal nerve or of the neck may damp the nystagmus and improve the waveform, allowing increased visual acuity.<sup>48,82</sup> Neck



**Fig. 15.** Depiction of shifts of neutral zone or null (N) in congenital nystagmus. Tracing demonstrates an idealized nystagmus pattern with both eyes open (OU). Neutral zone extends over several degrees on either side of 0°. When gaze is directed laterally, nystagmus of increasing amplitude develops with fast phase in direction of gaze. Occlusion of right eye (RE) shifts zone to the right; at 0° there is left-beating nystagmus. Occlusion of left eye (LE) shifts zone to the left; at 0° there is right-beating nystagmus.

or forehead vibration prolonged foveation periods, yielding higher values of the NAF and improved visual acuity in 9 of 13 patients with INS.<sup>48</sup> This noninvasive and benign therapy (active afferent stimulation) may prove useful in both INS and acquired nystagmus. The use of soft contact lenses to improve the acuity of individuals with INS takes advantage of the damping effect on nystagmus of (passive) afferent stimulation.<sup>83-86</sup>

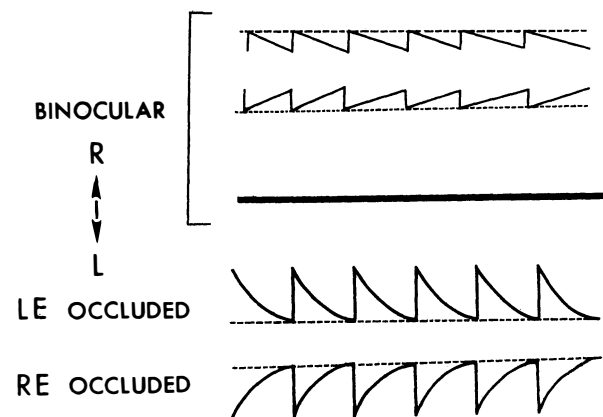
Soft contact lenses are not contraindicated in INS and can provide better acuity than spectacles in patients whose nystagmus damps with afferent stimulation. Plano soft contact lenses can be used if no refractive correction is required.

Both surgical and nonsurgical treatments for INS have been reviewed elsewhere.<sup>3,87</sup> Relatives of individuals with INS may have *saccadic* instabilities,<sup>88</sup> and carriers of blue-cone monochromatism may have vertical (upbeat and downbeat) nystagmus and FMNS.<sup>89</sup>

### Fusion Maldevelopment Nystagmus Syndrome

The FMNS consists of: a jerk nystagmus with either a linear or decreasing-velocity exponential slow phase identical to that of gaze-paretic nystagmus; strabismus; alternating hyperphoria/dissociated vertical deviation; and pendular torsional nystagmus in primary position. Occasionally, when both eyes are closed, a jerk nystagmus

with a linear slow phase is present. Classically, the nystagmus evoked by the “pure” or “true” latent condition (LN) occurs only with uniocular viewing. There is no nystagmus with both eyes viewing, but when one eye is occluded, nystagmus develops in both eyes, with the fast phase toward the uncovered eye (Fig. 16). The fast phases of FMN may contain dynamic overshoots,<sup>90</sup> whose characteristics in both FMN and IN are normal.<sup>91</sup> Dynamic overshoots are integral parts of the saccadic fast phases and not the beginnings of the slow phases. The occurrence of square-wave jerks (SWJ, see following) is also normal, and their presence during binocular viewing in FMN is unpredictable and variable. Thus, the presence of either does *not* represent a different “type” of FMN;<sup>92</sup> it is merely the *same* FMN including these common, normal saccadic dynamics or intrusions. This also applies to the occurrence of other types of nystagmus in addition to FMN (e.g., an undefined torsional nystagmus or the high-frequency pendular nystagmus thought to arise from the NOT, resulting in a dual-jerk waveform). In an individual patient, both FMN and IN may coexist with another type of nystagmus or saccadic intrusion/oscillation. The clearest way to delineate a group of patients with two mechanistically independent conditions is to describe them as having a syndrome consisting of two conditions (e.g., FMN with dynamic overshoots, FMN plus SWJ, or FMN plus torsional nystagmus). For simplicity, the basic FMN wave-



**Fig. 16.** Fusion maldevelopment nystagmus (FMN). With both eyes open there is either low-amplitude nystagmus (when only one eye is fixating) or, rarely, no nystagmus (when both eyes are fixating). Closure of either eye results in jerk nystagmus with fast phases toward the viewing (unoccluded) eye. When both eyes are open, the nystagmus fast phases are toward the fixating eye. Slow phases may be either linear (usually when both eyes are open) or decreasing-velocity exponentials (usually upon occlusion of one eye), unlike those of IN. Note that the fast phases may be foveating (for low-amplitude FMN with linear slow phases) or *defoveating* (for the higher amplitude FMN with decreasing velocity slow phases).

forms shown in Figure 16 do not contain dynamic overshoots in their fast phases nor the confounding addition of other types of nystagmus. When the additional pendular oscillation of NOT nystagmus is present, the resulting waveform would be the same as shown in Figure 7 for linear slow phases or consist of a pendular oscillation superimposed on decelerating slow phases.<sup>38</sup> FMN is always congenital. However, several cases have been recorded of the manifest form of FMN (MLN occurring with both eyes open), associated with retrolental fibroplasia.<sup>90</sup> FMN is common in Down syndrome, where it may coexist with IN.<sup>93</sup>

Early theories postulated that a unilateral retinal stimulus was the necessary condition for FMN, but this concept was discounted by observations of FMN in monocular fixation with a blind eye or with an acoustic stimulus in complete darkness. Similarly, the hypothesis that the FMNS is caused by nasal-temporal asymmetries in the optokinetic reflex is not supported by evidence that subjects with FMNS are able to use retinal slip information to adapt motion-detection sensitivities<sup>94</sup> and are able to pursue symmetrically.<sup>95</sup> Also, because nasal-temporal asymmetries exist in individuals with strabismus but not FMN,<sup>94</sup> this cannot be the primary causal factor in the genesis of the nystagmus. Asymmetries in the monocular optokinetic response of monkeys deprived of binocular input early in life may result from, rather than cause, their nystagmus. In normal monkeys, each nucleus of the optic tract (NOT) is driven binocularly; in these monkeys, they are driven by the contralateral eye.<sup>96</sup> Although the resulting imbalance may provide the tonic signal that produces the FMNS slow phases (inactivation of the NOT with muscimol abolishes the nystagmus), the cause of the imbalance appears to lie in higher centers. The spontaneous reversal of FMN in the dark has led to the speculation that eye dominance is predetermined.<sup>97,98</sup> Shallo-Hoffmann et al. identified an alternating vertical component to FMN,<sup>99</sup> and Brodsky linked the genesis of FMN and dissociated vertical divergence to the dorsal light reflex present in many animals.<sup>100</sup>

We relate the FMNS to the cortical switching that must occur in the calculation of egocentric direction when going from binocular to monocular viewing.<sup>90</sup> Under binocular conditions, the gaze angle of each eye is summed with the other and divided by two to obtain the egocentric direction, referenced to the "cyclopean eye." However, with monocular viewing, egocentric direction depends *only* on the viewing eye, and the cortical operation of summing and dividing by two must be altered to process unchanged information from the viewing eye. The shift in egocentric direction toward the nonviewing eye causes the slow drift of the eyes in that direction. Both eyes are then corrected by a saccade in the direction of the viewing eye, which brings the eyes

to the target (or, in darkness, to the intended gaze angle). This contention is supported by unilateral strabismus surgery causing central effects on egocentric localization.<sup>101</sup> Thus, FMNS nystagmus may be generated by this inability to properly alter the cortical mathematical operation normally used to define egocentric direction (i.e., this deficit in higher centers may result in a tonic imbalance in the visual-vestibular subsystem, producing the linear slow phases of FMN).

The shift to monocular egocentric localization can also produce a mode whereby the saccadic system generates defoveating saccades that momentarily carry the fixating eye past the target in a temporal direction, followed by a decelerating-velocity nasal drift back toward the target.<sup>102</sup> This results from generating a pulse, but not a step, of innervation to drive the fast phases of the FMNS nystagmus. Presumably, the common neural integrator is kept from integrating these defoveating pulses by the signal representing the correct eye position vis-à-vis the target. These hypotheses have been combined in an ocular motor system model (see Chapter 9) capable of simulating responses of an individual with FMNS.<sup>15,103,104</sup>

FMNS nystagmus occurs in patients with strabismus who, although viewing with both eyes open, are fixing monocularly. The slow phases are either linear or decelerating, and the fast phases are always in the direction of the viewing eye.<sup>90</sup> The nystagmus of patients with strabismus, alternating fixation, and FMNS nystagmus with both eyes open has fast phases always in the direction of the fixating eye. Such patients may be easily misdiagnosed as having INS, because the nystagmus is present with both eyes open. Recordings are required to document the decelerating or linear slow-phase waveforms characteristic of FMNS from the accelerating slow phases predominant in the INS.

Strabismus is a necessary (but not sufficient) condition for FMN.<sup>105</sup> That is, all individuals with FMN have strabismus, consisting of a phoria under cover and a tropia with both eyes open, if nystagmus is present under these respective conditions. Conversely, FMNS is not significantly associated with early-onset strabismus.<sup>106</sup> Rarely, on occlusion of a preferred eye, during which fixation with an amblyopic eye is forced, both eyes drift in the direction of the covered eye without corrections by fast phases; this is called latent deviation. Early surgical correction of infantile strabismus may convert the nystagmus of FMNS present with both eyes open (the manifest condition) to nystagmus present only upon occlusion of one eye (the latent condition),<sup>107</sup> thereby supporting a previous hypothesis.<sup>105</sup>

Because the good acuity of INS patients is related to the long, postsaccadic foveation periods of many waveforms, it was difficult to explain the equally good acuity of FMNS patients, given the absence of such periods.

However, accurate studies of FMNS foveation revealed a dual strategy.<sup>102</sup> During the low-amplitude, linear-slow-phase FMNS waveform, the saccadic fast phases foveate the target, and the low-velocity slow phases take the eye away from the target with little effect on acuity. During the higher amplitude, decelerating slow-phase FMNS waveform, the saccadic fast phases *defoveate* the target, allowing foveation during the low-velocity, tail ends of the slow phases (see Fig. 16); this ensures the best acuity possible.

Although most patients have nystagmus from either the INS or the FMNS, some have both; three unambiguous patient groups have been identified: INS, FMNS, and INS + FMNS.<sup>38,108,109</sup> The three groups exhibit different clinical signs and relations to strabismus; most INS patients do not have strabismus, but all FMNS patients do. Thus, INS and FMNS are specific, easily differentiated syndromes and do not, as has been suggested,<sup>110</sup> represent a unitary disorder with a broad spectrum of expression. Because no acquired, time-independent, primary-position jerk nystagmus reverses direction with alternate eye cover, a simple reverse-cover test can be a powerful clinical tool.

To distinguish between benign, infantile, primary-position, jerk nystagmus, and that which is acquired and symptomatic, first verify that there is no periodic alternation in direction and then perform a reverse-cover test. If the cover test causes a reversal in the nystagmus direction consistent with FMNS, the nystagmus is benign (FMNS or INS with a latent component). If not, attempt to rule out INS (by history, clinical signs [see Table 2], and waveforms).

### Nystagmus Blockage Syndrome

The nystagmus blockage syndrome (NBS) is both a poorly understood and an overdiagnosed phenomenon related to INS. As the name suggests, the nystagmus of these patients diminishes or disappears with the act of *willed esotropia* while fixating a distant target. This should not be confused with the damping of INS nystagmus during convergence on a near target. There are two mechanisms by which blockage of the ongoing nystagmus can be accomplished.<sup>111</sup> During the willed esotropia, some INS nystagmus merely damps or stops, in much the same way as with true convergence. In the second type of NBS, the INS waveform converts to a FMNS waveform with the onset of the strabismus. Normally, the substitution of the FMNS slow phases for the INS waveforms that allow for better foveation would not be advantageous. However, in these few patients, the small FMNS amplitude results in better acuity than the larger INS amplitude. NBS is often misdiagnosed

in FMNS patients with a strong Alexander's law variation of their nystagmus, which causes them to fixate with their adducting eye.<sup>111</sup>

### Spasmus Nutans Syndrome

Spasmus nutans syndrome (SNS) is a rare constellation of ocular oscillation, head nodding, and torticollis that begins in infancy (usually between 4 and 18 months of age) and disappears clinically in childhood (usually before 3 years of age). The nystagmus is generally bilateral (but can differ in each eye and may even be strictly monocular), and it oscillates in horizontal, torsional, or vertical directions. Hoyt reported an instance of SNS presenting with monocular nystagmus in monozygous twins.<sup>112</sup>

The nystagmus tends to be asymmetric in the two eyes, to vary in different directions of gaze, and to be rapid and of small amplitude. The head nodding is inconstant and irregular and can be horizontal, vertical, or both. The average duration of SNS is 12 to 24 months; rarely, it lasts a number of years. Studies of quantitative head- and eye-movement recordings indicate that the head movement may, using the normal VOR, actually serve to abolish the eye movements.<sup>113</sup> In some patients, it may be only compensatory with suppression of the VOR. Compare this to INS, where the head oscillation is an extension of the nystagmus and the VOR is normal (see preceding discussion).

The pendular oscillation of SNS is characterized by a variable phase difference between the oscillations of each eye.<sup>114</sup> These phase differences can appear from minute to minute and during the child's development. The dissociated nystagmus is usually of a higher frequency than INS nystagmus, and the result can be disjunctate, conjugate, or uniocular. We hypothesize that SNS reflects a yoking abnormality, perhaps due to delayed development. Recordings show that SNS nystagmus may not disappear completely but may recede to a subclinical level; neither INS nor FMNS nystagmus disappears with age.

### Acquired

SECONDARY TO VISUAL LOSS. Nystagmus occurring in early childhood consequent to progressive bilateral visual loss should not be classified as INS unless INS waveforms are documented. The conceptual problems in the classification were discussed earlier. Usually, nystagmus secondary to visual loss cannot be distinguished from INS in a patient with coexisting primary visual abnormalities.

The nystagmus associated with rod monochromacy

(complete congenital achromatopsia) is said to be distinguishable from other forms of nystagmus of infancy on the basis of slow buildup of the slow component velocity of OKN. This occurs during monocular stimulation with directional asymmetry of OKN when the temporal-to-nasal direction is compared with the nasal-to-temporal direction.<sup>115</sup> Patients with blindness from birth and nystagmus may have an impaired VOR and an inability to initiate saccades voluntarily, despite the presence of quick phases of nystagmus.<sup>116</sup> Adults with “eye movements of the blind” may exhibit features similar to those of patients with cerebellar disease<sup>116</sup> or may exhibit jerk nystagmus, see-saw nystagmus, or a combination of oscillations. Cats reared from birth in stroboscopic illumination develop low-amplitude nystagmus; this is believed to be an animal model for nystagmus secondary to visual loss.<sup>117</sup>

Monocular visual loss may produce monocular nystagmus, usually vertical, at any age from birth through adult life. That the nystagmus is monocular and usually vertical makes it distinguishable from INS, but it may mimic the nystagmus of spasmus nutans, particularly if there is associated head nodding.

**SPASMUS NUTANS.** The nystagmus of the benign spasmus nutans syndrome may sometimes be mimicked by tumors of the optic nerve, chiasm, or third ventricle,<sup>118</sup> although both the true SNS nystagmus and that secondary to tumor have been called spasmus nutans, we prefer to limit that term to the benign condition. Any child with nystagmus resembling SNS nystagmus should have brain imaging if tumor cannot be ruled out by other clinical signs. Retinal disease may mimic the clinical signs of the SNS,<sup>119</sup> as may opsoclonus-myoclonus.<sup>120</sup>

#### ACQUIRED PENDULAR NYSTAGMUS (ADULTS)

Acquired pendular nystagmus may reflect brain stem or cerebellar dysfunction, or both. It occurs in patients with vascular or demyelinating disease. In the latter, it has been regarded as a sign of cerebellar nuclear lesions. The nystagmus is multivectorial (i.e., horizontal, vertical, diagonal, elliptic, or circular) and usually is associated with a head tremor. Marked dissociation between the two eyes often exists and may not correlate with differences in visual acuity from coexisting optic neuropathy.<sup>121</sup> Despite the dissociation, the oscillations of the two eyes in a patient with MS are phase-locked, even though they may differ in their frequencies.<sup>122</sup> Das et al. postulated a neural-net model for acquired pendular nystagmus in MS; the model duplicated the resetting effect of saccades on the oscillation.<sup>123</sup> Acquired pendular nystagmus also occurs in an autosomal peroxisomal disorder.<sup>124</sup> Gabapentin is effective in treating some forms of acquired pendular nystagmus.<sup>124–126</sup> Aver-

buch-Heller et al. published a comprehensive review of the pathogenesis of acquired pendular nystagmus in 1995.<sup>127</sup>

Rarely, acquired pendular nystagmus in the adult becomes manifest with acquired amblyopia, as mentioned earlier. Scopolamine may be an effective treatment,<sup>128</sup> but botulinum toxin is of limited efficacy in treating acquired pendular nystagmus.<sup>129</sup> A review of current therapeutic approaches to various types of nystagmus and saccadic oscillations, based on known physiology and pharmacology, points out the need for more precise, double-blind studies.<sup>130</sup>

Miner’s nystagmus is a rarity limited presumably to mine workers in the United Kingdom. This historical anachronism was described as a small-amplitude, horizontal, and vertical nystagmus that is often more pronounced in upward gaze. The pathogenesis of this putative dysfunction is uncertain, but functional contamination with voluntary “nystagmus” is suspected; a secondary gain setting is usually present.

Except for the possible dissociation between the two eyes, acquired pendular nystagmus may be similar to a pendular INS waveform; both can have associated head tremor and characteristically damp with eyelid closure. Studies into the pathogenesis of acquired pendular nystagmus have ruled out delayed visual feedback and increased gain in the visually enhanced VOR as causal factors.<sup>127</sup>

#### ACQUIRED HORIZONTAL JERK NYSTAGMUS

##### Vestibular

We generally delimit vestibular nystagmus as being consequent to dysfunction of the vestibular end-organ, nerve, or nuclear complex within the brain stem. It is a horizontal-torsional or purely horizontal, primary-position jerk nystagmus with a linear slow phase. The nystagmus intensity increases with gaze toward the fast phase (obeying Alexander’s law); it decreases and, with central lesions, may reverse directions on gaze toward the direction of the slow phase. The symptom of vertigo usually coexists. As might be expected, acute lesions of the cerebellar flocculus (the vestibulocerebellum) can produce a similar nystagmus (see Chapter 10). For practical clinical purposes, the responsible lesion in vestibular nystagmus is located in either the end-organ, nerve, or brain stem. Such localization requires an appreciation of the manifestations of end-organ dysfunction. In normal subjects, some degree of nystagmus and vertigo develops when the labyrinth (end-organ) is stimulated with warm or cold water applied to the tympanic membrane. The direction of the resulting nystagmus, in terms of the fast (jerk) phase, can be remembered by the mnemonic “COWS” (Cold, Opposite; Warm, Same). Cold

water in the left ear (or warm water in the right) induces a right-beating nystagmus; cold water in the right ear (or warm water in the left) induces a left-beating nystagmus. In addition, the subject experiences vertigo and, with eye closure, past-points with an outstretched arm and falls in a consistent direction on Romberg testing. The apparent direction of the vertiginous movement, whether of the environment or self, is always in the direction of the fast phase of the nystagmus. The past-pointing and Romberg fall are always in the direction of the slow phase. For example, with cold water placed in the external canal of the left ear, the subject develops a right-beating jerk nystagmus and experiences environmental or bodily movement to the right (paradoxically appearing to move continuously in one direction).<sup>131</sup> With the eyes closed, the patient's attempts at pointing an outstretched finger at a target in front of him result in past-pointing to the left; on standing there is a tendency to fall to the left (in the direction of the slow phase of the nystagmus). This Romberg fall can be directionally altered by head turning: with the head turned to the left, the slow phase is directed toward the rear and the fall is backward; with the head turned to the right, the fall is forward.<sup>132</sup>

These manifestations of cold-water irrigation mimic the effects of a destructive lesion of the vestibular end-organ; warm-water irrigation mimics an irritative lesion. Clinically, most diseases of the end-organ create destructive effects. Irritative phenomena occur but are transient, often subclinical, and usually of interest only to the electronystagmographer. During an attack of Ménière's disease, there may be ipsilateral (jerk toward the affected side) nystagmus. Perhaps the most common cause of ipsilateral nystagmus secondary to end-organ disease is recovery nystagmus.<sup>133</sup> Here, spontaneous nystagmus that occurs after a unilateral labyrinthine lesion may transiently reverse direction as some function is restored in the damaged end-organ. This probably

reflects the compensatory "central rebalancing" of the vestibular nuclei. This compensation can also change a primary-position vestibular nystagmus (of peripheral or central etiology) to a paroxysmal positional nystagmus.<sup>134</sup>

A patient with unidirectional jerk nystagmus, vertigo in the direction of the fast-phase component, and past-pointing and Romberg fall in the direction of the slow component is suffering acute dysfunction of the vestibular end-organ on the side of the nystagmus *slow phase*. When the pattern of direction for the nystagmus, vertigo, past-pointing, and Romberg fall is not as just described but varies in some aspect, the symptom complex represents a central vestibular abnormality. Thus, in central vestibular disease, the vertigo may be in the direction of the slow phase of the nystagmus, and the past-pointing or Romberg fall may be toward the fast phase.

Other factors distinguish peripheral from central vestibular nystagmus. Pure vertical or pure torsional nystagmus is never peripheral and always represents central dysfunction. Similarly, pure horizontal nystagmus without a torsional component is suggestive of central disease.<sup>131</sup> Nystagmus that is reduced in intensity by visual fixation is peripheral, whereas nystagmus due to central lesions is usually not reduced, and may even be enhanced, by fixation. Peripheral vestibular nystagmus is best visualized clinically behind Frenzel lenses (+20 diopters), which eliminate the inhibiting effects of visual fixation and magnify the eyes.<sup>135</sup> A marked bidirectionality to the nystagmus (left-beating on left gaze and a similarly severe right-beating nystagmus on right gaze) is almost always central. Nystagmus may accompany episodic attacks of ataxia.<sup>136</sup> Evidence has been presented supporting a specific chromosomal abnormality in some cases<sup>137</sup> and brain stem lesions in others.<sup>138</sup> Table 4 presents the differential features of peripheral and central vestibular nystagmus.

TABLE 4. Vestibular Nystagmus

Symptom or Sign	Peripheral (End-Organ)	Central (Nuclear)
Direction of nystagmus	Unidirectional, fast phase opposite lesion	Bidirectional or unidirectional
Purely horizontal nystagmus without torsional component	Uncommon	Common
Vertical or purely torsional nystagmus	Never present	May be present
Visual fixation	Inhibits nystagmus and vertigo	No inhibition
Severity of vertigo	Marked	Mild
Direction of spin	Toward fast phase	Variable
Direction of pastpointing	Toward slow phase	Variable
Direction of Romberg fall	Toward slow phase	Variable
Effect of head turning	Changes Romberg fall	No effect
Duration of symptoms	Finite (minutes, days, weeks) but recurrent	May be chronic
Tinnitus and/or deafness	Often present	Usually absent
Common causes	Infection (labyrinthitis), Ménière's disease, neuronitis, vascular, trauma, toxicity	Vascular, demyelinating, and neoplastic disorders

### Gaze-Evoked (Gaze-Paretic) Nystagmus

Gaze-evoked nystagmus is elicited by the attempt to maintain an eccentric eye position, and it is the most common form of nystagmus encountered in clinical practice. Patients recovering from a central gaze palsy show a phase in which lateral gaze movement is possible but cannot be maintained in the deviated position; that is, the eyes drift back slowly toward primary position (see Chapter 10). A corrective saccade repositions the eyes eccentrically, and repetition of this pattern produces nystagmus, aptly designated "gaze-paretic." This was a clinical description that was not based on oculographic findings. Information about the role of the brain stem neural integrators (see Chapter 9) led to the presumption that a defective integrator would result in the inability of the eyes to maintain an eccentric position, causing them to drift toward the center with a decreasing-velocity exponential waveform. This is indeed the waveform that defines the "gaze-paretic" subtype of gaze-evoked nystagmus, which is particularly prevalent in patients with cerebellar disease that especially involves the flocculus (see Chapter 10). There appears to be an inherent "leakiness" of the brain stem neural integrators, namely, a tendency to drift from a given firing level. The cerebellar flocculus normally corrects for this drift. With a floccular lesion, the leakiness and drift are unchecked, and gaze-paretic nystagmus develops. If the integrator leak is small and the time-constant long, a gaze-paretic nystagmus could have a slow phase shape that is linear rather than a decreasing-velocity exponential. Such nystagmus cannot be designated as gaze-paretic with any degree of certainty and may only be described as gaze-evoked.

In summary, the term *gaze-paretic nystagmus* is restricted to a subgroup of gaze-evoked nystagmus with a decreasing-velocity exponential slow phase. It is integrator nystagmus with a defect in the step function of neural firing frequency constituting the pathophysiologic mechanism. The same integrators are probably responsible for smooth-pursuit eye movements, which seem to be invariably abnormal in patients with gaze-paretic nystagmus.

The most common cause of pathologic, bidirectional, gaze-evoked nystagmus is sedative or anticonvulsant medication. The nystagmus fast phase is always in the direction of gaze (toward the right on right gaze, left-beating on left gaze, and upbeating on upward gaze; downgaze is usually without nystagmus). In the absence of drugs, horizontal gaze-evoked nystagmus with linear slow phases can be localized only enough to indicate brain stem or, if unilateral, labyrinthine dysfunction. Analysis of the associated neurologic signs and symptoms would be required for more precise localization.

Gaze-evoked vertical nystagmus almost always coex-

ists with the horizontal variety. Primary-position vertical jerk nystagmus (upbeat and downbeat) is discussed later.

### SPECIAL NYSTAGMUS TYPES

#### Physiological (End-Point)

There are three basic types of nystagmus that are regarded as normal (physiological) phenomena.<sup>139</sup>

Fatigue nystagmus begins during extended maintenance of an extreme gaze position and occurs in up to 60% of normals when horizontal gaze is maximally deviated for a time exceeding 30 seconds. It may become increasingly torsional with prolonged deviation effort and may be greater in the adducting eye. Fatigue nystagmus is not a clinically important phenomenon, because routine examinations do not include the maintenance of far eccentric gaze.

Unsustained end-point nystagmus is certainly the most frequently encountered physiologic nystagmus. Its characteristics have never been studied quantitatively. All experienced clinicians recognize that a few beats of nystagmus are within perfectly normal limits at gaze deviations of 30° or more.

Sustained end-point nystagmus begins immediately upon, or within several seconds of, reaching an eccentric lateral-gaze position. It occurs in more than 60% of normal subjects with horizontal-gaze maintenance greater than 40°. Quantitative oculography reveals that physiologic nystagmus can begin with only a 20° deviation<sup>139</sup> and is almost universal at deviations of 40° or more.<sup>140</sup> The slow phase is linear, except with an extreme 40° to 50° deviation, in which a decreasing-velocity exponential may develop. The nystagmus may be different in the two eyes, but it is symmetric in the two lateral directions. The amplitude of physiologic nystagmus does not exceed 3°. <sup>139</sup> Thus, small-amplitude gaze-evoked nystagmus may be a normal phenomenon, provided the slow phase, with gaze angles up to 40°, is linear. The onset of end-point nystagmus is related to slow drift velocity,<sup>141</sup> and the reduction of drift velocity during fixation (probably by the fixation subsystem) inhibits the nystagmus. Gaze-evoked nystagmus is by necessity "pathologic" if any of three features are present: (1) asymmetry in the two directions, (2) amplitude of 4° or more, or (3) exponential slow phase within a gaze angle of less than 40°.

#### Dissociated

Nystagmus in which the two eyes show a significant asymmetry in either amplitude or direction is designated "dissociated." The most common type of dissociation is in internuclear ophthalmoplegias where it is most

marked in the abducting eye (see Chapter 10). Abduction nystagmus, which is sometimes designated by the confusing term ataxic nystagmus, is not really a nystagmus. This saccadic oscillation is secondary to lesions of the medial longitudinal fasciculus and is discussed under Saccadic Pulses/Pulse Trains later in this chapter and in Chapter 10.

The pendular nystagmus in patients with multiple sclerosis is usually dissociated. There are a variety of nystagmus dissociations with lesions of the posterior fossa (e.g., asymmetric vertical nystagmus greater in one eye on looking up and in the other eye on looking down).

### Torsional

Torsional nystagmus describes a torsional movement of the globe about its anteroposterior axis; the term *rotary nystagmus* is used interchangeably. Most nystagmus consequent to vestibular end-organ dysfunction has a torsional component admixed with a major horizontal or vertical nystagmus. A purely torsional nystagmus never occurs with vestibular end-organ disease. When of small amplitude, torsional nystagmus may reflect a medullary lesion. Larger-amplitude torsional nystagmus may be congenital, but when it is acquired it often indicates diencephalic (thalamic) involvement, in which case it is the underlying pattern in see-saw nystagmus. Torsional nystagmus can be classified into two groups.<sup>142</sup> In one the nystagmus is in primary position, and in the other it is gaze evoked. The etiologies of both are demyelinating, vascular, or neoplastic.

For consistency, nystagmus in the torsional plane should be defined with respect to the subject, *not* the observer. When a subject's nystagmus beats to the right, it is called jerk-right nystagmus; if it beats toward the forehead, it is upbeat (even if the subject is in the head-hanging position). Therefore, when the nystagmus fast phases bring the top of the eye toward the subject's right shoulder, it is *clockwise* nystagmus. Clinical descriptions of torsional nystagmus, made from the observer's point of view, deviate from the accepted convention that applies to both horizontal and vertical movements. Maintaining the subject-based directions reduces confusion, eases understanding of anatomic substrates, and anchors the subject's perception of oscillopsia to the direction of his nystagmus. Just as leftward horizontal slow phases cause rightward, perceived world motion, clockwise torsional slow phases cause counterclockwise, perceived world motion (see elliptic nystagmus, discussed later).

### See-Saw

See-saw nystagmus is characterized by a conjugate, pendular, torsional oscillation with a superimposed dis-

junctive vertical vector. The intorting eye rises, and the opposite, extorting eye falls. Repetition of this sequence in the alternate direction provides the see-saw effect. The torsional movements predominate in all fields of gaze, but the see-saw feature may be restricted to the primary position or, more commonly, to downward or lateral gaze. See-saw nystagmus can be of the jerk type (with one phase being slow and the other fast) with unilateral meso-diencephalic lesions.<sup>143</sup> Most patients with acquired pendular see-saw nystagmus have bi-temporal hemianopias consequent to large parasellar tumors expanding within the third ventricle. It is occasionally evoked transiently after blinks or saccades.<sup>144</sup> Upper brain stem vascular disease and severe head trauma are the next most common etiologies. Posttraumatic see-saw may be temporarily abolished by ingestion of alcohol.<sup>145</sup> Rarely, the nystagmus is associated with septo-optic dysplasia, an Arnold-Chiari malformation,<sup>146</sup> multiple sclerosis,<sup>147</sup> or loss of vision alone.<sup>148</sup> See-saw nystagmus probably reflects diencephalic (thalamic) dysfunction possibly of a pathway or pathways from the zona incerta to the interstitial nucleus of Cajal. A study of visual-vestibular interaction concluded that see-saw nystagmus resulted from a loss of retinal error signals secondary to disruption of chiasmal crossing fibers.<sup>149</sup>

Congenital see-saw nystagmus manifests either in constant vertical disjugacies without a significant torsional component or in conjugate torsional nystagmus with a vertical component said to be opposite that of the acquired variety; that is, the intorting eye falls while the extorting eye rises. However, all cases of congenital see-saw nystagmus that have been recorded follow the rule that the rising eye intorts while the falling eye extorts. Congenital see-saw nystagmus is also seen in canine and human achiasma (see Albinism and Achiasma section later in the chapter). An unusual instance of congenital see-saw nystagmus in two mentally retarded adult siblings, associated with retinitis pigmentosa, also had the typical vertical/torsional relationship associated with acquired see-saw.<sup>150</sup>

The ocular tilt reaction, described in Chapter 10, is actually one-half of a see-saw cycle.

### Convergence/Convergence-Evoked

The act of convergence usually damps nystagmus, particularly the congenital type.<sup>151</sup> Convergence can also damp<sup>151</sup> or evoke<sup>152</sup> lid nystagmus and may damp or enhance downbeat nystagmus.<sup>153</sup> Upbeat nystagmus may change to downbeat with convergence.<sup>154</sup>

Repetitive divergence is a term describing a slow divergence movement followed by a rapid convergence to the primary position. The movements occur at irregular intervals, distinguishing this from nystagmus.<sup>155</sup> In the

single reported instance of this phenomenon in a patient with hepatic encephalopathy, an entire cycle lasted from 4 to 10 seconds, and the interval between cycles was 1 to 15 seconds.

Conjugate nystagmus evoked by convergence (convergence-evoked nystagmus) must be distinguished from convergence nystagmus. Convergence-retraction nystagmus as a manifestation of the dorsal midbrain syndrome is discussed in Chapter 10; here, the initiating convergence movements are saccadic<sup>156</sup> and, thus not a true nystagmus. Fast divergent movements, followed by a slow convergence associated with epileptic electroencephalographic activity, occurred in a neonate with an intraventricular hemorrhage.<sup>157</sup>

With the exception of pure convergence nystagmus in infants with spasmus nutans, true pendular convergence nystagmus is uncommon. We observed it in a patient with presumed progressive supranuclear palsy who had paralysis of all volitional eye movements. In retrospect, however, the patient probably had central nervous system Whipple's disease, perhaps the most common cause of pendular convergence nystagmus (see Chapter 10). We studied three patients with convergence nystagmus with phase shifts of about 180° in both the horizontal and torsional planes with conjugate nystagmus in the vertical plane.<sup>158</sup> Convergence increased the nystagmus in two of the patients. The waveforms were either sinusoidal or complex sums of sinusoids, and in one patient they were cycloidal. Unlike the pseudocycloid waveform of INS, there were no initiating saccades to these cycloidal movements. We hypothesized that the low-frequency convergence nystagmus resulted from a visually mediated vergence instability, whereas high-frequency forms might have arisen from instability of brain stem pathways associated with vergence.

Nystagmus evoked by convergence is unusual and may be either conjugate or disjunct, congenital or acquired.<sup>159</sup> In two cases reported, no definite clinical correlation could be made with a specific lesion. The neuro-pathologic examination revealed no morphologic explanation for nystagmus in the patient with congenital convergence-evoked nystagmus; the patient with the acquired form had demyelinating disease with a spastic paraparesis and no cranial nerve abnormality other than the ocular motor findings.<sup>159</sup> Horizontal pendular nystagmus rarely is evoked by accommodative vergence.<sup>160</sup> This is to be distinguished from psychogenic flutter (the so-called voluntary nystagmus discussed later), which is often best induced when the eyes are slightly converged.

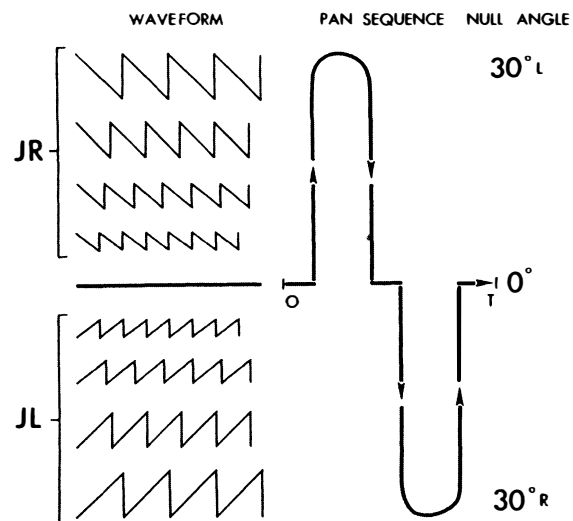
### Periodic Alternating

Periodic alternating nystagmus (PAN) is an extraordinary ocular motor phenomenon in which a persisting horizontal jerk nystagmus periodically changes direc-

tions. PAN may be congenital or acquired. The congenital variety (i.e., INS nystagmus), which may be associated with albinism,<sup>161,162</sup> has slow-phase waveforms of both linear and increasing velocity, usually lacks the well-defined stereotyped periodicity seen in acquired PAN (i.e., it is asymmetric (*a*)periodic alternating nystagmus—APAN), and can persist for many minutes in either direction or spontaneously change direction after a few seconds.<sup>163,164</sup> The addition of variable pendular nystagmus to these APAN jerk waveforms can produce complex waveforms that may mimic those of FMNS nystagmus.<sup>165–167</sup> The periodicity of INS APAN is markedly influenced by changes in gaze position, supporting the hypothesis that the direction reversals are a result of a temporal shift in the null zone (Fig. 17).<sup>80</sup>

Patients with INS and a varying head turn should be examined for APAN.

In contrast, the usual, fixed sequence in acquired PAN consists of about 90 seconds of nystagmus beating in one direction, 10 seconds of a neutral phase in which the eyes stop or beat downward irregularly, and 90 seconds of beating in the opposite direction. This periodic-



**Fig. 17.** Periodic alternating nystagmus (PAN) sequence is depicted in relation to waveform and null angle. Sequence reflects one PAN period (from 0 to T). Period begins in a neutral phase; null is at 0°. As null shifts to the left, jerk right (JR) nystagmus develops and gradually increases in amplitude to maximum when null is at extreme left (e.g., 30°L). Null then shifts back toward 0°, and JR nystagmus decreases, finally stopping and forming the next neutral phase when null reaches 0°. The same sequence of null shifting to right and back accounts for jerk left (JL) phase. The diagram is idealized and does not reflect the asymmetries of the true clinical state. (Daroff RB, Dell'Osso LF: Periodic alternating nystagmus and the shifting null. *Can J Otolaryngol* 3:367, 1974)

ity is continuous during waking hours and may prevail during sleep. Some patients demonstrate asymmetries in the timing of the two major phases, but the basic pattern for each patient is usually invariable.

In a detailed clinical and control-system study, Leigh and colleagues<sup>168</sup> proposed that PAN arises from: (1) a defect in the brain stem neural networks that generates slow phases of vestibular and optokinetic nystagmus, (2) the action of an adaptive network that normally acts to null prolonged, inappropriate nystagmus, and (3) an inability to use retinal-error velocity information. They proposed a control system model that denied access of visual signals to the OKN-vestibular system. This model is particularly appealing because of the occasional relationship between impaired vision and PAN. Support for their hypothesis of impairment in the velocity storage element was presented by Furman et al.,<sup>169</sup> who studied four PAN patients. PAN has occurred after bilateral vitreous hemorrhages (associated with a massive subarachnoid hemorrhage) and after cataracts and disappeared after bilateral vitrectomy and cataract surgery, respectively. Ablation of the nodulus and ventral uvula of the cerebellum in monkeys produces PAN.<sup>170</sup>

Although numerous conditions have been associated with PAN, including INS, head trauma, vascular insufficiency, encephalitis, syphilis, multiple sclerosis, spinocerebellar degenerations, and posterior fossa tumors, particular attention should be directed to an abnormality of the craniocervical junction, such as a Chiari malformation. PAN may coexist with downbeat nystagmus, which also suggests an abnormality in the same location.

Campbell described PAN secondary to phenytoin intoxication in a patient with alcoholic cerebellar degeneration.<sup>171</sup> The antispasticity drug baclofen abolishes acquired PAN but has no effect on the INS variety.<sup>172</sup> The drug abolished experimentally created PAN in the monkey,<sup>170</sup> as well as a single case of aperiodic alternating nystagmus in a patient with vertebrobasilar insufficiency.<sup>173</sup>

PAN may be associated with a periodic alternating skew deviation.<sup>174</sup> Periodic alternating gaze deviations, with and without associated alternating nystagmus or alternating head turning, are rare, related phenomena.<sup>175</sup>

### Downbeat

Downbeat nystagmus is defined as nystagmus in primary gaze position, with the fast phase beating in a downward direction. Patients with brain stem disease or drug intoxications usually lack gaze-evoked downward nystagmus despite nystagmus in all other fields of gaze. Thus, nystagmus beating downward in the primary position is a striking phenomenon and is highly suggestive of a craniocervical junction lesion, such as a Chiari malformation.<sup>176,177</sup> Downbeat nystagmus is usually of suf-

ficient amplitude in primary position to cause oscillopsia, and, contrary to Alexander's law,<sup>2</sup> it is not maximum at the extreme of downward gaze. Rather, it is usually of maximal intensity when the eyes are deviated laterally and slightly below the horizontal;<sup>177</sup> the nystagmus may be intermittent.

The other major cause of downbeat nystagmus is spinocerebellar degeneration. A variety of miscellaneous conditions may also be associated with downbeat nystagmus,<sup>153,177</sup> including anticonvulsants, alcohol and lithium intoxication, magnesium deficiency, B<sub>12</sub> deficiency, brain stem encephalitis, alcoholic cerebellar degeneration, and brain stem or cerebellar infarcts.<sup>178</sup> Rarely, downbeat nystagmus is secondary to upper brain stem or supratentorial lesions; or as a form of INS nystagmus. Schmidt's<sup>179</sup> article is an excellent clinical review of downbeat nystagmus.

Downbeat nystagmus was regarded as the prototype of nystagmus secondary to a "pursuit defect," but studies have cast serious doubt as to whether a unidirectional pursuit defect is a cause of any form of nystagmus.<sup>176</sup> The slow-phase waveform of downbeat nystagmus can vary from a linear, to an increasing-velocity, to a decreasing-velocity exponential in the same patient, presumably reflecting short-term gain changes by cerebellar compensation for leaky brain stem neural integrators.<sup>5</sup> One patient with a pseudocycloid waveform damped with convergence, prompting treatment with base-out prism spectacles,<sup>153</sup> This has subsequently proved superior to retinal image stabilization as a means of reducing oscillopsia.<sup>180</sup> Downbeat is usually increased in intensity with head-hanging<sup>176</sup> as well as linear acceleration, and occasionally convergence. The mechanism of downbeat is postulated to be disruption of central vestibular pathways,<sup>176</sup> possibly involving specific connections from the otoliths or an asymmetry of the vertical semicircular canal gains.<sup>181</sup>

### Upbeat

Primary-position nystagmus with the fast phase beating upward may reflect drug or other intoxications<sup>182</sup> but usually indicates structural disease, usually of the brain stem.<sup>183-185</sup> The location of the lesions in patients with upbeat nystagmus after meningitis or Wernicke's encephalopathy is uncertain. Büttner et al. discussed the localizing value of upbeat and other types of nystagmus.<sup>186</sup> With convergence, upbeat may enhance<sup>184</sup> or convert to downbeat.<sup>154</sup> The slow-phase waveform is usually linear but may be an increasing-velocity exponential.

Upbeat may be enhanced<sup>184</sup> or suppressed<sup>187</sup> by head tilt. Therefore, it is conceptualized hypothetically as secondary to a disruption of central otolithic pathways; the effects of convergence on the nystagmus are presumed

to reflect vergence effects on these pathways. Tobacco smoking causes upbeat nystagmus in normal human subjects in darkness, but the nystagmus is suppressed by visual fixation.<sup>188</sup> The mechanism is presumed to be the excitatory effects of nicotine on central vestibular pathways.

### Rebound

Rebound nystagmus is either the diminution and direction change of gaze-evoked horizontal nystagmus during sustained ocular deviation or a horizontal gaze-evoked nystagmus that, on refixation to primary position, transiently beats in the opposite direction. The sign is often present in patients with cerebellar disease.<sup>189</sup> Rebound nystagmus is conceptualized as a smooth eye movement bias generated to oppose gaze-evoked centripetal drift of the eyes. Normal subjects may demonstrate rebound nystagmus after prolonged far lateral gaze if the lights are shut off the moment the eyes are returned to primary position and may even occur in normals during fixation in a fully lit room.<sup>140</sup> Rebound and centripetal nystagmus may occur in Creutzfeldt-Jakob disease.<sup>190</sup>

### Circular, Elliptic, and Oblique

Circular nystagmus, sometimes confusingly mislabeled as “rotary,” is a form of pendular nystagmus in which the globe oscillates continuously in a fine, rapid, circular path. Unlike torsional nystagmus, in which the 12 o’clock meridian of the limbus torts laterally, this point maintains its position in circular nystagmus. The nystagmus represents the summation of simultaneous, equal-amplitude, horizontal, and vertical pendular oscillations that are 90° out of phase. Elliptic nystagmus is produced when the horizontal and vertical oscillations are 90° out of phase but are of unequal amplitude. Analysis of the vertical and horizontal pendular nystagmus movements, which summate to form circular and elliptic nystagmus, indicates that a true circular pattern is rarely sustained. More often, the nystagmus varies between elliptic and circular. Unlike all other types of nystagmus, the oscillopsia induced by elliptical nystagmus is in the *same* direction as the slow phases.<sup>191</sup> Thus, if the subject’s eye moves in a clockwise, circular-elliptic manner (from the subject’s point of view), the direction of perceived world motion will also be clockwise. Acquired circular-elliptic nystagmus occurs in multiple sclerosis, is often dissociated in the two eyes, and almost always coexists with truncal or extremity ataxia. Drug treatment with isoniazid may be effective.<sup>191</sup> This type of nystagmus is often part of the INS and is identical in the two eyes in patients otherwise free of neurologic signs.

Oblique or diagonal nystagmus results when simul-

taneous pendular, horizontal, and vertical vectors are either in phase or 180° out of phase. The angle of the diagonal vector depends on the relative amplitudes of the horizontal and vertical components. This type is more often acquired than infantile and has the same significance as acquired circular-elliptic nystagmus.

### Cervical

The literature on cervical (cord) nystagmus contains numerous examples of spontaneous or positional nystagmus allegedly secondary to lesions of the cervical spinal cord or roots.<sup>192–194</sup> Although this form of positional nystagmus occurs only rarely, it is claimed to support the “legitimacy” of dizziness in patients who have sustained “whiplash” injuries and are involved in litigation. For that reason, the entire concept of cervical nystagmus has become highly suspect.<sup>193,194</sup> We have never seen a patient with convincing cervical nystagmus.

### Muscle-Paretic (Myasthenic)

A paretic eye muscle, from whatever cause, can fatigue quickly during contraction, and muscle-paretic nystagmus can be observed. This is often evident as gaze-evoked nystagmus in myasthenia gravis, in which there is usually asymmetry between the two eyes.<sup>195</sup> Another form of oscillation in myasthenia is nystagmus of the abducting eye (may be saccadic pulse trains, discussed below), coexisting with paresis of adduction; this mimics an internuclear ophthalmoplegia. Here the oscillation is not due to lateral rectus paresis, but rather to excessive innervation by increased central gain, the result of paresis of the contralateral yoke medial rectus. Cessation of both muscle-paretic and contralateral yoke nystagmus in myasthenia usually follows administration of anticholinesterase medication.

### Lid

Lid nystagmus is a rhythmic, upward jerking of the upper eyelids that usually consists of the normally coordinated movements of the lids and eyes during vertical ocular nystagmus. Several types of pathologic lid nystagmus are recognized. Type I, with no specific localizing value coexists synchronously with vertical ocular nystagmus, but the amplitude of the lid movements exceeds significantly that of the eyes. Type II is evoked by lateral gaze and is characterized by rapid phasic twitches of the lids that are synchronous with the fast phases of horizontal ocular nystagmus. This second type may be a sign of the lateral medullary syndrome and can be inhibited by near-effort.<sup>151</sup> Type III lid nystagmus is provoked by ocular convergence.<sup>152,196</sup> In a patient with

this type of nystagmus studied pathologically, there was a large area of subacute demyelination in the rostral medulla. Lid nystagmus, differing from Types I–III, may occur with midbrain lesions.<sup>197</sup>

### Epileptic

Nystagmus associated with epileptic activity includes retraction, pendular, torsional, and divergent-convergent forms.<sup>157</sup> At times, the pupils may constrict and dilate synchronously with the nystagmus.<sup>198</sup> The usual form of epileptic nystagmus is horizontal jerk with the fast phase contralateral to a posterior parietal focus, but a vertical nystagmus may also be present.<sup>199</sup> The eyes may tonically deviate toward or away from the side of the epileptic focus.<sup>200</sup> The decreasing-velocity slow phases suggest that a gaze-holding failure<sup>201</sup> causes the slow phases, and the relationship of the ictal activity suggests activation of the saccadic system (see Chapter 10).<sup>199</sup>

### INDUCED NYSTAGMUS

#### Caloric

We previously described the characteristics of caloric-induced vestibular nystagmus. With unilateral irrigation, the nystagmus is horizontal, torsional, or oblique, depending on the position of the head. Bilateral simultaneous caloric stimulation produces vertical nystagmus; the direction of the fast (jerk) phase can be remembered by the mnemonic CUWD (pronounced “cud” and designating Cold, Up; Warm, Down).

Traditionally, caloric nystagmus was regarded as being evoked entirely by thermal convection of the endolymph. However, the fact that such nystagmus exists in the zero-gravity conditions of outer space indicates the necessity of an alternative mechanism,<sup>202</sup> which, in addition to the convection mechanism, is a direct temperature effect on the canal’s sensory apparatus that is independent of head orientation. A review of the technique of quantitative bithermal caloric testing for evaluating vestibular function is provided elsewhere. Caloric and head rotation (doll’s) are useful tests in the evaluation of comatose patients.<sup>204</sup>

#### Rotational

Rotating or accelerating head movements induce motion of endolymph in the semicircular canals, with a resultant jerk nystagmus. If the axis of rotation passes through the upright head, as happens with the Bárány chair, the nystagmus fast phase is in the same direction as head (or chair) rotation. After cessation of the rotation, the postrotary nystagmus is in the opposite direction. Rota-

tional nystagmus is used in evaluating the ocular motor system in infants (see Chapter 3, Fig. 2), and to evaluate vestibulo-ocular gain and other aspects (visual suppression of the VOR) of the vestibular system.

### Positional

In patients complaining of vertigo related to shifts in position of the head or body, positional nystagmus should be considered. The test is performed by observing for nystagmus produced when the patient rapidly reclines from a sitting to a supine position, with the head either turned alternately to one side and then the other, or hyperextended (hanging). Two types of nystagmus, peripheral and central, can be differentiated (Table 5).

Peripheral positional nystagmus is associated with marked vertigo, which begins after a delay of 2 to 20 seconds. The nystagmus and vertigo eventually fatigue, usually within 1 minute. A rapid return to the sitting position causes another brief burst of nystagmus and vertigo (“rebound”). Repositioning in the provocative supine posture again induces nystagmus and vertigo, but to a lesser extent. Repetition of the shifts of posture ultimately results in diminution and disappearance of the nystagmus and vertigo. Characteristic of the peripheral variety is variable reproducibility: the nystagmus and vertigo may not be present every time the offending position is attained. Whereas latency, fatigability, and habituation have traditionally been regarded as the major features distinguishing peripheral from central positional nystagmus, Baloh et al.<sup>205</sup> emphasize that the nystagmus vector is the critical determinant. Positional nystagmus with a torsional-vertical vector, with the torsional component greater in the undermost eye and the vertical component (upbeating) greater in the uppermost eye, is *always* peripheral, irrespective of the nature of latency, fatigability, and habituation. The torsional component increases when gaze is directed toward the down eye, and the upbeating component increases with gaze directed toward the upper eye.<sup>205</sup> With head hanging (extended), a downbeating nystagmus (fast phase beat-

TABLE 5. Positional Nystagmus

Features	Peripheral	Central
Latency	3–40 sec	None; nystagmus begins immediately
Fatigability	Yes	No
Rebound	Yes	No
Habituation	Yes	No
Intensity of vertigo	Severe	Mild
Reproducibility	Poor	Good
Directionality and Waveforms	Stereotyped	Variable

ing toward the chin) probably has the same significance as downbeating nystagmus with the patient upright.

Central positional nystagmus, which is invariably reproducible, begins immediately on movement to the provoking position; the nystagmus neither fatigues nor habituates, and the vertigo is usually mild. Positional nystagmus that changes direction while the head position remains fixed has long been regarded as a central sign, also with peripheral disease and even in normal subjects.<sup>206</sup>

The peripheral variety, designated “benign paroxysmal positional vertigo” (BPPV), is indicative of labyrinthine disease, and neuroradiologic procedures are rarely indicated. The most common specific etiology is head trauma. However, no cause is found in most cases. The malady increases in prevalence with age. Nystagmus, identical to the benign peripheral variety, may result from the slow drift produced by central vestibular compensation consequent to either peripheral or central vestibular dysfunction.<sup>134</sup>

The most reasonable etiology of BPPV is “canalolithiasis.” The hypothesis is that otoconia detach from a utricle, congeal to form a “plug,” and float freely in the endolymph of a posterior semicircular canal. Because the plug is of greater specific gravity than the endolymph, the canal becomes a gravity receptor, and symptoms and signs are produced when the head is in a particular position. This concept has led to a form of “physical therapy” in which repetitive movement, or a single provocative movement, dislodges the displaced otoconia.<sup>207</sup> Most patients with the disorder recover spontaneously after several weeks. However, if a person has persistent symptoms and the attacks are consistently evoked with the head in the offending position, a liberatory maneuver is performed. With BPPV, in addition to positional vertigo, patients develop symptoms on arising, bending over, leaning forward, and with head movements while upright.

The central type of positional nystagmus is often associated with neoplastic, vascular, demyelinating, or degenerative disorders involving the brain stem or cerebellum.<sup>208</sup> Intermediate forms of positional nystagmus, such as those that fatigue and habituate but have no noticeable latency, should raise suspicions of central disease. The difference between central paroxysmal positioning nystagmus and that of BPPV is in the direction; the latter beats in the direction aligned with the affected canal plane and any other direction indicates a central origin.<sup>209</sup>

Testing for positional nystagmus is fairly standardized and does not require electronystagmography. We prefer self-illuminated Frenzel glasses (highly convex lenses, +20 D, which blur vision), but testing can also be performed in a completely darkened room, with the examiner periodically observing the eyes with a dim

light. Routine testing for positional nystagmus in patients without the specific symptom of positional vertigo does not generally yield useful results.

The BPPV just mentioned is due to dysfunction of a posterior semicircular canal. Some patients have horizontal-canal BPPV<sup>210</sup> or anterior-canal BPPV,<sup>211</sup> which have different liberatory maneuvers.<sup>212</sup> The term *positional nystagmus* is often used interchangeably with *positional vertigo* in designating a syndrome, and *positional* and *positioning* are used interchangeably to describe nystagmus.

### Optokinetic

The localizing value of OKN with cerebral hemispheric lesions is discussed in Chapter 10. OKN is used for several other important functions in clinical neuro-ophthalmology. It provides evidence of at least gross levels of visual function in infants or patients with functional visual loss. As mentioned in Chapter 10, OKN in the downward direction is used to induce convergence-retraction “nystagmus,” and horizontal OKN is used to demonstrate the adduction insufficiency in internuclear ophthalmoparesis. “Inversion” of OKN is diagnostic of INS. OKN can also be used to diagnose oculomotor nerve misdirection.

### Drug/Toxin-Induced

Drug-induced nystagmus is a common sequela of barbiturate, tranquilizer, phenothiazine, and anticonvulsant therapy.<sup>213</sup> The nystagmus is generally gaze evoked and is usually horizontal or horizontal-torsional in direction. Vertical nystagmus is often present on upward gaze and only rarely on downward gaze. At times the nystagmus may be dissociated in the two eyes despite the lack of structural disease to account for the asymmetry. Although primary-position nystagmus is usually indicative of severe drug intoxication, it may persist for 10 hours after the oral ingestion of only 100 mg of secobarbital.<sup>134</sup> In addition, this amount of secobarbital can produce positional nystagmus. As mentioned, lithium can produce downbeat nystagmus,<sup>214,215</sup> tobacco can induce upbeat nystagmus,<sup>188</sup> and severe alcohol intoxication can produce downbeat nystagmus.<sup>216</sup> Toluene (glue-sniffing) can induce pendular nystagmus with both horizontal and vertical components.<sup>217</sup>

Unfortunately, that alcohol can produce horizontal gaze-evoked nystagmus has led to a “roadside sobriety” test conducted by law-enforcement officers.<sup>218</sup> Nystagmus as an indicator of alcohol intoxication is fraught with extraordinary pitfalls: many normal individuals have physiologic end-point nystagmus; small doses of tranquilizers that wouldn’t interfere with driving ability can also produce nystagmus; nystagmus may

be congenital or consequent to structural neurologic disease; and often a neuro-ophthalmologist or sophisticated oculographer is required to determine whether nystagmus is pathologic. Such judgments are difficult for experts to make under the best conditions and impossible to make accurately under roadside conditions. It is unreasonable to have cursorily trained law officers using the test, no matter how intelligent, perceptive, and well meaning they might be. As noted, meticulous history taking and drug-screening blood studies are often essential in evaluating patients with nystagmus.

### SPECIAL ANATOMIC CATEGORIES

#### Acoustic Neuroma

Schwannomas of the eighth nerve grow so slowly that adaptive mechanisms often obscure clinical vestibular manifestations. Vestibular nystagmus beating contralateral to the lesion may be present, particularly if fixation is eliminated. As the tumor expands to compress the brain stem, a slow, gaze-evoked ipsilateral nystagmus is often added. The combination of a small-amplitude, rapid primary-position jerk nystagmus beating contralateral to the lesion and a slower, larger-amplitude, gaze-evoked (Bruns') nystagmus ipsilateral to the lesion also occurs with other extra-axial masses, including cerebellar tumors, compressing the brain stem. Rarely, Bruns' nystagmus is inverted.<sup>219</sup>

#### Lateral Medullary Syndrome

The lateral medullary syndrome (Wallenberg) is a distinctive constellation of signs. The nystagmus in this syndrome tends to be stereotyped. With the eyes open there is horizontal-torsional jerk nystagmus beating contralateral to the lesion; when recorded with the eyes closed, the nystagmus beats ipsilateral to the lesion. Other rare manifestations, confined to single cases, are gaze-evoked eyelid and ocular nystagmus inhibited by the near reflex<sup>151</sup> and horizontal gaze-evoked monocular downbeat nystagmus.

An extraordinarily dramatic eye-movement abnormality, "saccadic lateropulsion," may occur with lateral medullary infarction. Eye movements as well as body and limb movements are biased toward the side of the lesion (ipsipulsion). The ocular motor abnormality is most striking during shifts of fixation; all ipsilateral saccades are too large (hypermetric), whereas those to the opposite side are too small (hypometric). Spontaneous drifts to the side of the lesion are gaze dependent and may reflect disruptions of the gaze-holding mechanism.<sup>220</sup> There is also reduced capability to adjust saccadic gain in response to the dysmetria,<sup>221</sup> significant tilt in the subjective vertical, with ipsilateral excyclo-

tropia,<sup>222</sup> and torsional nystagmus and torsipulsion.<sup>223,224</sup> Upward or downward refixations veer ipsilaterally along an oblique rather than a vertical line. Lateropulsion away from the side of the lesion (contrapulsion) has occurred with a unilateral disorder of the rostral cerebellum.<sup>225</sup> Both types of lateropulsion are regarded as saccadic instabilities (Table 6). The gaze deviation may reflect increased inhibition of the ipsilateral vestibular nucleus and ipsipulsion may reflect decreased excitation of contralateral premotor areas in the pontine paramedian reticular formation.<sup>226</sup>

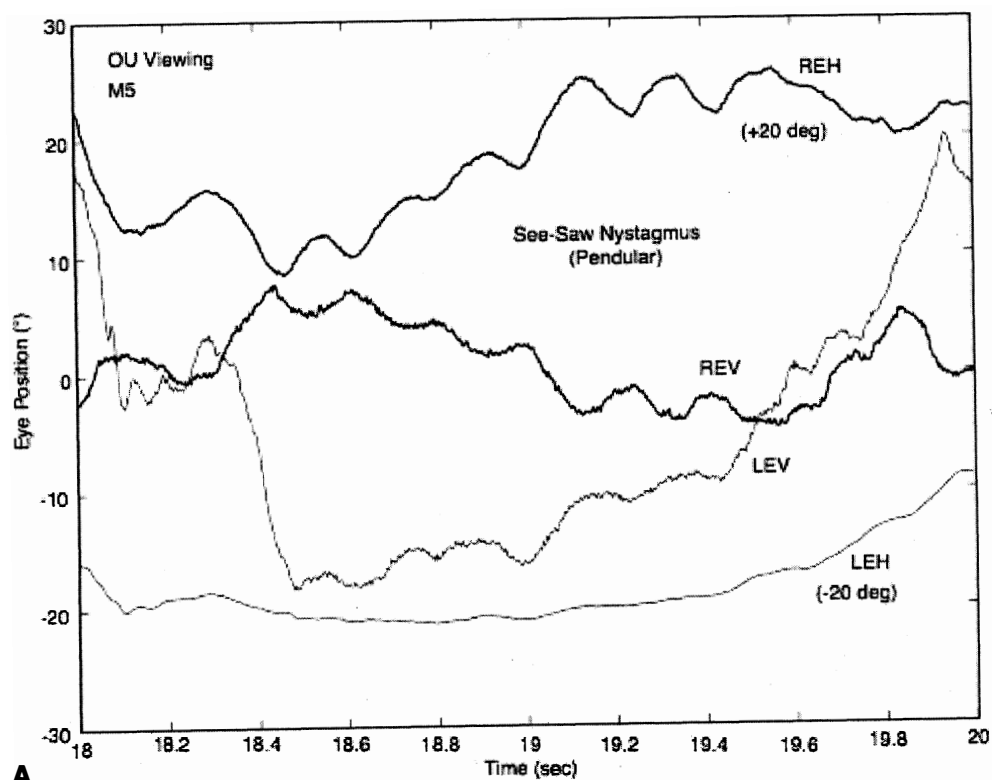
### ALBINISM AND A(HEMI)(HYPO)CHIASMA

Ocular albinism is associated with anomalous visual projections that result in a variety of eye movement disturbances, with considerable intersubject variability. These individuals may have pendular or jerk nystagmus, absent OKN, "inverted" pursuit, or "defective" pursuit (see section on INS) when targets are projected onto

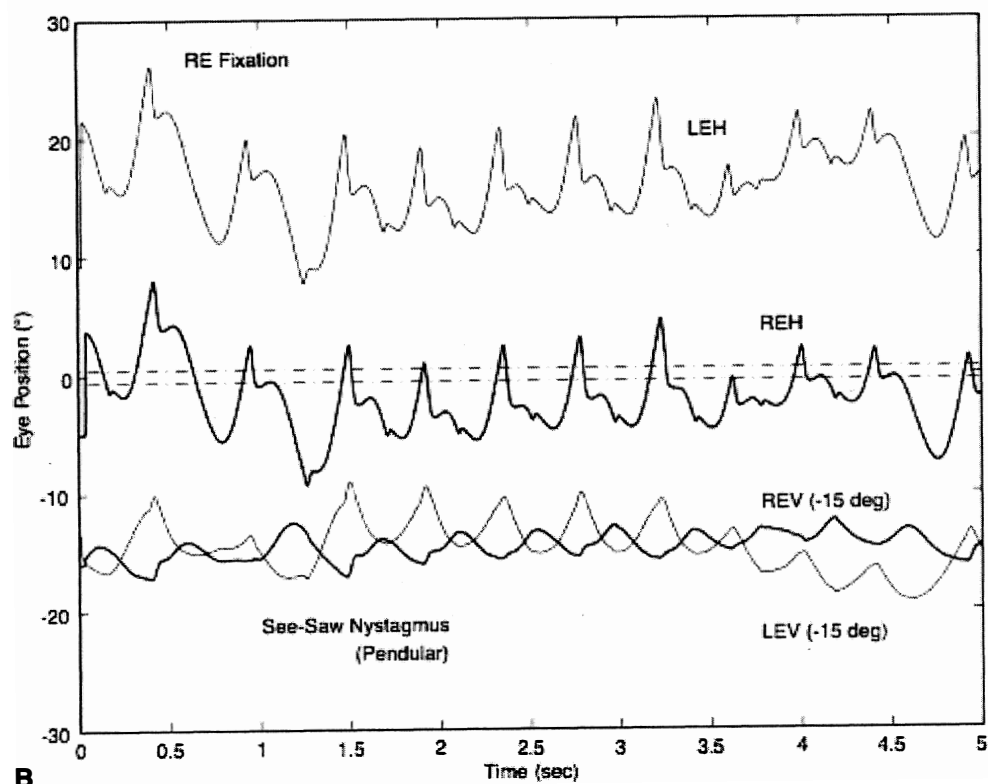
TABLE 6. Saccadic Intrusions and Oscillations\*

Bobbing/dipping	Saccadic lateropulsion
inverse bobbing	ipsipulsion
reverse bobbing	contrapulsion
Convergence-retraction	Saccadic pulses/pulse trains
"nystagmus"	
"nystagmus" retractoris	abduction "nystagmus"
Double saccadic pulses	ataxic "nystagmus"
(single/multiple)	
saccadic intrusions/	saccadic intrusions/
oscillations	oscillations
Dynamic overshoot	stepless saccades
"quiver"	Square-wave jerks/oscillations
Dysmetria	Gegenrucke
Flutter	hopping "nystagmus"
Flutter dysmetria	"lightening eye movements"
Macro saccadic oscillations	myoclonus
Myoclonus	saccadic intrusions/oscillations
laryngeal "nystagmus"	Zickzackbewegungen
"lightning eye movements"	Square-wave pulses
	(bursts/single)
pharyngeal "nystagmus"	"macro square-wave jerks"
Opsoclonus	Kippdeviationen/
	"Kippnystagmus"
"dancing eyes"	"pendular macro-oscillations"
"lightning eye movements"	saccadic "nystagmus"
saccadomania	saccadic oscillations/
	intrusions
Psychogenic flutter	Staircase saccadic intrusions
hysterical flutter	Superior oblique myokymia
hysterical "nystagmus"	
"ocular fibrillation"	
"ocular shuddering"	
psychological "nystagmus"	
voluntary flutter	
voluntary "nystagmus"	

\*Synonyms and other terms are indented under either the preferred or the more inclusive designation; quoted terms are erroneous or misleading.



A



B

the temporal half-retina.<sup>227</sup> Periodic alternating nystagmus may also occur.<sup>161,162</sup> Albinism may also exist in the absence of any nystagmus.<sup>228,229</sup>

Achiasma is a very rare condition, first recognized in dogs (ca. 1974) and then in humans (ca. 1992). It is associated with the combination of INS and see-saw nystagmus; we first diagnosed the see-saw nystagmus from videotape (in canines in 1991 and in a human in 1993) and subsequently studied it using eye-movement recordings.<sup>50,230–235</sup> In achiasma, all retinal fibers remain ipsilateral, passing to the ipsilateral lateral geniculates and visual cortexes. Thus, each visual cortex has a representation of the entire visual field, but stereopsis is impossible; there is no bitemporal hemianopia. Figure 18 shows both the horizontal INS nystagmus and the vertical component of the see-saw nystagmus in an achiasmatic canine (Fig. 18A) and an achiasmatic human (Fig. 18B). The horizontal and vertical waveforms of the canines' nystagmus and the human's vertical nystagmus were pendular, whereas the human's horizontal waveforms were pendular with foveating saccades ( $P_{FS}$ ) or pseudopendular with foveating saccades ( $PP_{FS}$ ). Because the achiasmatic human subject was not always able to achieve well-developed foveation, as shown by her inability to repeatedly foveate the target with her fixating right eye, a larger than normal foveation window for the NAFX would be required to assess the best potential visual acuity for this segment. Unlike INS, which may or may not be associated with a particular sensory deficit, the see-saw nystagmus appears to be directly associated with achiasma in both species. In achiasma, there is no lesion, indeed no chiasm, and disruption of thalamic inputs to the nucleus of Cajal, postulated as the cause of acquired see-saw nystagmus, cannot be causal. In hemichiasma, abnormalities at the chiasm prevent decussation of the retinal fibers from one eye, the other decussating normally.<sup>236</sup> Whereas achiasma appears to be sufficient for see-saw nystagmus, hemichiasma is not. Ocular motility and retinal studies of humans with achiasma and hypochiasma (a maldeveloped chiasm) revealed INS, see-saw nystagmus, strabismus, reduced vision, optic nerve dysplasia.<sup>237</sup> Because of the rarity of congenital see-saw nystagmus and its identification in both canines and humans with achiasma and in one of two canines with hemichiasma, we regard its presence in infants as a diagnostic sign of possible achiasma or hemichiasma.<sup>238</sup> The

presence of see-saw nystagmus in an infant is a strong indication for imaging of the optic chiasm to rule out achiasma or structural abnormalities (hypochiasma) conducive to hemichiasma.

### Leber's Congenital Amaurosis

Leber's congenital amaurosis may be caused by several abnormalities, among which is a defect in retinal pigment epithelium due to absence of the RPE65 gene. Recent studies of a new genetic treatment for this blinding disease conducted on members of a colony of RPE65-deficient canines have shown initial success.<sup>239</sup> Within several weeks of a subretinal injection of healthy RPE65 genetic material in an adenovirus solution, the previously absent ERG and pupillary responses were markedly improved, as was the visually guided behavior of the injected dogs. Comparisons of the pre- and postinjection ocular motility recordings revealed that the INS nystagmus damped to such an extent that it was clinically absent.<sup>240</sup> The nystagmus scanpaths in Figure 19 show the dramatic difference between the INS nystagmus in two litter mates, one untreated and the other genetically treated. Note that the elliptical trajectories of the untreated nystagmus were in opposite directions; prior to treatment, the clinical appearance of the treated dog's nystagmus was judged to be equal to that of the untreated litter mate. Further studies are being conducted to assess both the effectiveness and safety of this promising genetic treatment to prevent blindness in affected children.

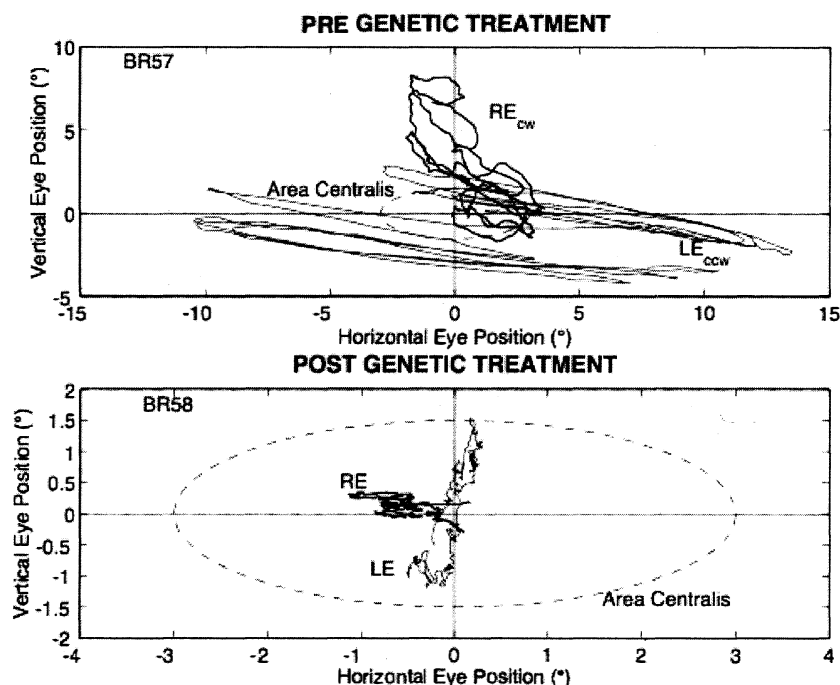
### Cerebellum

Some of the various eye signs seen with cerebellar system disease are discussed in previous sections and in Chapter 10. Descriptions of others will follow.

## SACCADIC INTRUSIONS AND OSCILLATIONS

Nonnystagmic (i.e., saccadic) ocular oscillations and intrusions represent specific and classifiable eye movement anomalies (see Table 6). Many reflect cerebellar dysfunction. In Table 6, 17 types of saccadic intrusions and oscillations are identified, the most important of which are discussed following.

**Fig. 18.** The horizontal IN and vertical component of see-saw nystagmus in (A) an achiasmatic Belgian sheepdog, during binocular (OU) viewing and (B) an achiasmatic human, during right-eye fixation. Note that the left eye in (B) was approximately 15° esotropic. Where indicated, traces were shifted for clarity. REH—right eye horizontal, LEH—left eye horizontal, REV—right eye vertical, and LEV—left eye vertical. In (B), REV and LEV were shifted -15° for clarity.



**Fig. 19.** Nystagmus scan-path comparison of the pre- (BR57) and postgenetic (BR58) treatment of IN in canine litter mates. The dashed ellipses indicate the  $\pm 6^\circ$  (horizontal) by  $\pm 3^\circ$  (vertical) area centralis of each dog. CW—clockwise, CCW—counter-clockwise.

### SQUARE-WAVE JERKS/OSCILLATIONS

Square-wave jerks (SWJ), so named because of their rectangular appearance on eye-movement records (Fig. 20), are usually small-amplitude ( $0.5^\circ$  to  $5^\circ$ ), conjugate saccadic eye movements that spontaneously move the eyes away from, and back to, a fixation point. Between the two saccades that constitute this saccadic intrusion is a latent period of about 200 milliseconds (the visual reaction time). SWJ have a maximum frequency of about 2 Hz and occur in normals (especially with eyelid closure) as well as individuals with nystagmus (e.g., IN or FMN). When they are prominent during fixation, they should be considered abnormal, although lacking diagnostic specificity, much like saccadic pursuit. SWJ are a subtle disturbance that is easily missed clinically. However, they are obvious with eye-movement recordings, which also allow other types of saccadic intrusions to be identified.<sup>241</sup> Because the individual saccades in SWJ are usually small, they may contain dynamic overshoots (see Chapter 9). Clinically, they are often best identified during slit-lamp biomicroscopy or funduscopy, but they may be difficult to distinguish from other intrusions (e.g., square-wave pulses).

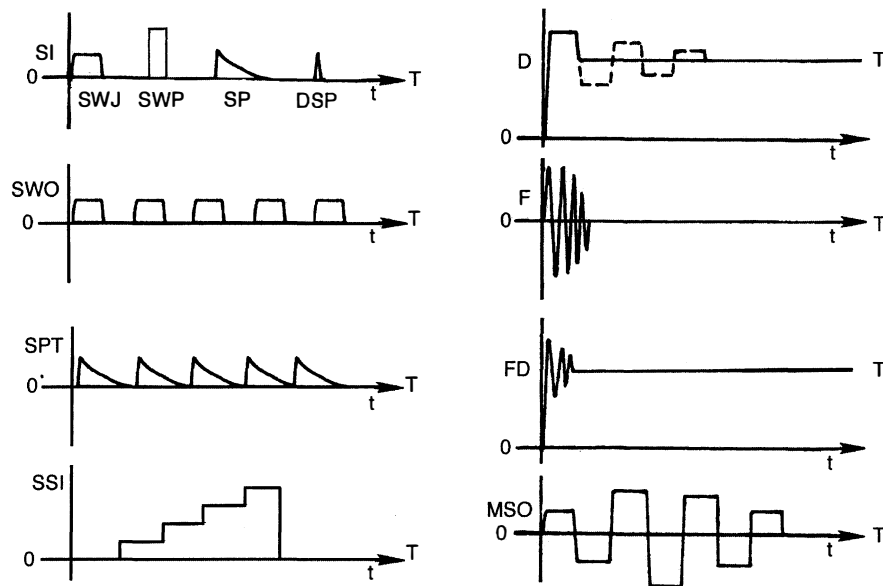
SWJ is significantly more common in the elderly population than in young subjects. Their appearance at a rate greater than 9/minute in young patients is considered abnormal. SWJ also are found in 70% of patients with acute or chronic focal cerebral lesions and are the rule in

progressive supranuclear palsy and Parkinson's disease. Schizophrenic patients and their parents<sup>242</sup> exhibit SWJ, which are also present during smooth pursuit and have been mistaken for a deficit in the pursuit system. The frequency and metrics of SWJ are also influenced by the task being performed.<sup>243</sup>

Square-wave oscillations (SWO) are continuously occurring SWJ and have been recorded in patients with a variety of neurologic deficits (see Fig. 20). The characteristics are identical to those of SWJ (Table 7). In a patient with progressive supranuclear palsy, SWO appeared to be part of a continuum with SWJ; at times, single or several SWJ occurred, and at other times there were long runs of SWJ that were identified as SWO.<sup>244</sup>

### SQUARE-WAVE PULSES

Square-wave pulses (SWP), originally called "macro square-wave jerks," are usually larger in amplitude than SWJ, are related to fixation, and have a frequency of about 2 Hz.<sup>245</sup> They generally occur in bursts but may appear as a single saccadic intrusion. Both eyes suddenly and conjugately move off target with a saccade, and after a latent period of only about 80 milliseconds, a nonvisually evoked reflex saccade brings them back on target (see Fig. 20). SWP are not merely large SWJ; the characteristics of both are summarized in



**Fig. 20.** Schematic illustrations of: saccadic intrusions (SI) including square-wave jerks (SWJ), square-wave pulses (SWP), saccadic pulses (SP), double saccadic pulses (DSP), and staircase saccadic intrusions (SSI); saccadic oscillations including square-wave oscillations (SWO), saccadic pulse trains (SPT), and macro saccadic oscillations (MSO); dysmetria (D); flutter (F); and flutter dysmetria (FD). T, Target; 0, primary position; *t*, time.

Table 7. SWP usually occur in patients with marked extremity ataxia suggestive of cerebellar outflow disease, especially when the patient has demyelinating lesions.<sup>245</sup> A unique variety of SWP, present with binocular fixation at distance but stopping when either eye was closed, prompted the designation “inverse latent SWP.”<sup>246</sup>

#### STAIRCASE SACCADIC INTRUSIONS

We identified a unique type of saccadic intrusion in a patient with cerebellar atrophy, named, staircase saccadic intrusions because of its appearance in eye-movement recordings.<sup>247</sup> Fixation would be interrupted by a series of saccades in one direction or the other with normal intersaccadic intervals (see Fig. 20). The individual saccades could be of equal amplitude or could vary. Staircase saccadic intrusions were also present during smooth pursuit. In normals, such “staircase” eye movements can be generated by feeding back the eye-

movement signal and allowing it to move the target in the same direction; this produces a constant retinal error signal that drives the saccadic system. We modelled staircase saccadic intrusions using a behavioral OMS model<sup>15</sup> by interfering with the retinal error signal and creating a constant reconstructed error signal.

#### MACRO SACCADIC OSCILLATIONS

Macro saccadic oscillations (MSO) increase and then damp in amplitude, bypassing the fixation angle with each saccade (see Fig. 20).<sup>248</sup> Unlike SWJ, SWO, and SWP, MSO are not present in darkness and have a longer latency for the return saccade than do SWP. MSO may occur among a constellation of saccadic intrusions and oscillations including SWJ, saccadic pulses (SP), double saccadic pulses (DSP), flutter, and flutter dysmetria (FD)<sup>241</sup> (see following for descriptions of these latter eye signs).

A comparison of the features of the four saccadic

**TABLE 7. Characteristics of Saccadic Instabilities**

	Square-Wave Jerks	Square-Wave Oscillations	Square-WavePulses*	Macro Saccadic Oscillations
Amplitude	0.5°–5° <sup>1</sup>	0.5°–5° <sup>1</sup>	4°–30°	1°–30°
Time course	Constant	Constant	Variable	Increasing then decreasing
Latency	Sporadic/bursts	Bursts	Bursts/sporadic	Bursts
Foveation	200 msec	200 msec	50–150 msec	200 msec
Presence in darkness	Yes	Yes	Yes	No

\*Previously designated macro square-wave jerks.

<sup>1</sup>Occasionally up to 10°.

instabilities described earlier (SWJ, SWO, SWP, and MSO) appears in Table 7.

### SACCADIC PULSES/PULSE TRAINS

Saccadic pulses, originally called “stepless saccades,” are intrusions on fixation caused by a spurious pulse of innervation, provided by the burst cells without the usual accompanying step. The resultant eye movement is a saccade off-target followed immediately by a glissadic drift back to the target (see Fig. 20). The glissadic drift in SP represents failure of the neural integrator to produce a step of innervation from the burst producing the SP. This difference from SWJ suggests dysfunction in the pause cell/burst cell circuitry for SP and a more central dysfunction for SWJ.

Saccadic pulse trains (SPT) are continuous runs of SP and, as Figure 20 shows, may be easily confused with nystagmus. Even on good eye-movement records, SPT cannot be distinguished from jerk nystagmus with decreasing-velocity slow phases, unless both eye position and target position are known. The initiation of an SP is a saccade off-target, whereas jerk nystagmus is initiated by the slow phase off-target, with the saccadic fast phase bringing the eye back to the target. The so-called abduction “nystagmus” of internuclear ophthalmoplegia is a SPT.<sup>249</sup> We recorded several patients with congenital achromatopsia thought to have INS, but their oscillations did not contain any of the known INS waveforms and were most consistent with SPT. The waveforms mimicked those of FMNS, but there were no evident effects of monocular fixation.

### DOUBLE SACCADIC PULSES

Double saccadic pulses (DSP) are intrusions on fixation, consisting of two back-to-back saccades without latency between them (see Fig. 20).<sup>241</sup> Small DSP are common in normals and also occur occasionally with INS. Multiple DSP (mDSP) are runs of DSP.<sup>241</sup> There is a continuum between the saccadic intrusion DSP, mDSP, and the saccadic oscillation, flutter.<sup>244</sup> Vertical DSP has occurred superimposed on the pendular nystagmus of ocular flutter.<sup>250</sup>

### DYSMETRIA

Strictly speaking, dysmetria refers to any inaccurate saccadic eye movement. With small saccades, normal subjects may undershoot or overshoot; with large saccades, small undershooting is the rule. Consistent overshooting during small refixations ( $10^\circ$  or less), or more than occasional overshooting during refixations greater than  $30^\circ$ , is abnormal and indicative of cerebellar dysfunction (see Fig. 20).<sup>251</sup> The term *ocular dysmetria* is used to denote

pathologic hypermetria. In experimental animals with cerebellar lesions, dysmetria may be unequal in the two eyes.<sup>252</sup> The components of the oscillation are usually flat at the peaks, indicating an intersaccadic latency,<sup>251</sup> but they may also be triangular or sinusoidal in appearance; the latter are probably cycles of flutter dysmetria (FD) (see following).

Quantitative studies can differentiate normal from pathologic saccadic dysmetria,<sup>253</sup> especially for saccades of  $20^\circ$  or more. Saccadic dysmetria with preserved smooth pursuit may result from midline cerebellar lesions.<sup>254</sup> This occurs despite the known involvement of the cerebellar vermis in the control of smooth pursuit. A patient with a dorsal cerebellar vermis angioma had dysmetria of all types of saccades (visually guided and visually, vestibularly, and cervically remembered);<sup>255</sup> the observation that final eye position was normal in the memory-guided saccades, suggests that this area is involved in the neural integration of the saccadic pulse for such saccades.

### FLUTTER

Ocular flutter was originally defined clinically as any brief, intermittent, binocular, horizontal ocular oscillation occurring spontaneously during straight-ahead fixation. It differs from the oscillation of dysmetria, which always follows a saccadic refixation. In eye-movement recordings, flutter is triangular or sinusoidal in appearance, consisting of several back-to-back saccades (see Fig. 20).

Flutter represents a disturbance of the pause cells in the pontine paramedian reticular formation subserving horizontal eye movements.<sup>256</sup> Inappropriate inhibition of the pause cells leads to the burst cell activity that produces the flutter. Rarely, a blink will initiate a large-amplitude ocular flutter in patients with neurologic disease and short bursts of low-amplitude flutter in normal subjects.<sup>257</sup> Ashe et al. described microflutter (“microsaccadic” flutter) in five patients with no identifiable neurological disorders,<sup>258</sup> attributed to malfunction of the omnipause neurons. There are also reports of flutter with the AIDS-related complex<sup>259</sup> and with opsoclonus in patients with anti-Ri antibodies.<sup>260</sup>

Flutter and opsoclonus represent a continuum of ocular motor instability. Patients recovering from opsoclonus often develop a picture of flutter in which opsoclonus emerges, especially during upward gaze. As with opsoclonus, flutter may be a manifestation of a paraneoplastic syndrome,<sup>261</sup> and it may remit spontaneously even before the neoplasm is diagnosed.<sup>262</sup>

### FLUTTER DYSMETRIA

Flutter dysmetria (FD) is the occurrence of flutter immediately after a saccade (Fig. 20).<sup>256</sup> Although it superfi-

cially resembles dysmetria, eye-movement recordings reveal that FD is an oscillation about the intended fixation angle and consists of back-to-back saccades with no intersaccadic latencies. This contrasts with dysmetria in which the saccadic oscillation has normal intersaccadic latencies. FD is seen in a setting of cerebellar disease.

### OPSOCLONUS

Opsoclonus is a bizarre ocular motor oscillation consisting of rapid, involuntary, chaotic, repetitive, unpredictable, conjugate saccadic eye movements in all directions (and planes) and persisting during sleep.<sup>263</sup> The movements are usually continuous except during recovery and in mild forms, during which brief paroxysms interrupt stable fixation. In this instance, the continuum between opsoclonus and ocular flutter, mentioned earlier, is readily apparent. Some paroxysms have characteristic oblique or half-circle vectors,<sup>264</sup> whereas others are entirely horizontal and indistinguishable from flutter.

Opsoclonus, usually associated with extremity myoclonus and ataxia, occurs in a number of clinical settings. In children, opsoclonus and generalized limb myoclonus may continue enigmatically for years, except when suppressed by adrenocorticotrophic hormone (ACTH) therapy, which seems to be more effective than corticosteroids. Opsoclonus and acute cerebellar ataxia may represent the sole manifestations of occult neuroblastoma, and the eye movements usually, but not always, remit after tumor removal. This variety of opsoclonus may also respond to ACTH. Hattori et al. reported opsoclonus only on eye closure in two brothers with hereditary cerebellar ataxia.<sup>265</sup>

Rarely, opsoclonus is a self-limiting phenomenon that occurs in otherwise normal neonates. The so-called ocular tics seen in children usually occur with other types of tics, may be imitated on request, and may be associated with stress.<sup>266</sup> They appear to be bursts of opsoclonus when recorded.<sup>267</sup> In adults, opsoclonus can be secondary to a postinfectious syndrome (which has an excellent prognosis for a complete recovery); brain stem encephalitis; toxicity due to amitriptyline, lithium, haloperidol, chlordecone, thallium, toluene, chlorophenothane, phenytoin or diazepam; hyperosmolar nonketotic coma; and degenerative diseases.<sup>268,269</sup> It also occurs as a nonmetastatic, paraneoplastic complication of visceral carcinoma; some of these patients have anticerebellar antibodies in the serum and cerebrospinal fluid,<sup>270,271</sup> and their manifestations may improve with steroid<sup>260,272</sup> or immunoabsorption<sup>273</sup> therapy. Brain stem pause cell dysfunction is the presumed etiology, but these cells are normal pathologically in this syndrome.<sup>274</sup> Radiologic and pathologic correlation in a patient suggests involvement of both cerebellum and

brain stem.<sup>275</sup> Electrophysiologic data suggest brain stem and cerebellar circuits are involved in idiopathic opsoclonus-myoclonus.<sup>276</sup> Extensive reviews of the literature are available.<sup>130,277,278</sup>

### MYOCLONUS

Ocular myoclonus is a pendular oscillation that conforms to our definition of nystagmus and is indeed regarded as nystagmus by European writers. However, the eye movement is usually classified separately as “myoclonus” because of associated rhythmic movements of nonocular muscles in synchrony with the eyes. The soft palate is most commonly involved, but the tongue, facial muscles, pharynx, larynx, and diaphragm may also participate.

The term *myoclonus* is used, often confusingly, to describe several movement disorders. It may refer to spontaneous, episodic, single, or multiple jerks of the extremities that constitute a form of seizure particularly prevalent in infants. The same movement provoked by a loud noise is termed *startle myoclonus* and occurs in adults with specific types of cerebral dysfunction, such as anoxic encephalopathy or Creutzfeldt-Jakob disease. Similar movements occur in normal subjects before falling asleep and represent a physiologic phenomenon, probably of spinal origin. Myoclonus also describes the arrhythmic, asymmetric, sudden, brief, involuntary jerks of one or more muscles of the extremities, often reflecting a metabolic derangement or degenerative central nervous system disease with cerebellar involvement.

Ocular myoclonus is characterized by continuous, rhythmic, to-and-fro pendular oscillation, usually in the vertical plane, with a rate of 1.5 to 5 beats per second. Only the coexisting movements of other structures, such as the palate, distinguish “ocular myoclonus” from pendular nystagmus. At times the eye movements have an oblique and rotary vector.<sup>279</sup> Actually, isolated palatal myoclonus (symptomatic or essential)<sup>280</sup> is more common than the oculopalatal variety and may be a benign, self-limited process that variably responds to anticonvulsants.

Oculopalatal myoclonus has a rather specific pathologic correlate—hypertrophy of the inferior olivary nucleus in the medulla. The myoclonic triangle involves three structures: the red nucleus in the midbrain, the ipsilateral inferior olive in the medulla, and the contralateral dentate nucleus of the cerebellum. The connecting pathways are the central tegmental tract, the inferior cerebellar peduncle, and the superior cerebellar peduncle. Pathologic involvement of the central tegmental tract produces hypertrophy of the ipsilateral inferior olive after a latency of two to 49 months, with a mean at about 10.5 months.<sup>281</sup> Damage to a dentate nucleus

results in contralateral olivary hypertrophy after a similar latency. Oculopalatal myoclonus develops as a consequence of the olivary hypertrophy and, therefore, is not a manifestation of acute lesions. The mechanism for the hypertrophy is believed to be denervation supersensitivity<sup>281</sup> related to transneuronal degeneration.<sup>282</sup> Once established, myoclonus ordinarily persists, even during sleep, as a chronic sign until the death of the patient.<sup>283</sup> Occasionally, isolated palatal myoclonus disappears during sleep.<sup>284</sup> A single case of ocular myoclonus responded dramatically to valproic acid<sup>285</sup> and another to chronic one-eye patching.<sup>286</sup> Trihexyphenidyl seems to be the most effective therapy.<sup>287</sup>

### SUPERIOR OBLIQUE MYOKYMIA

Superior oblique myokymia is an intermittent, small-amplitude, monocular, torsional eye movement ("microtremor") evoking oscillopsia, which appears spontaneously in otherwise healthy adults and only rarely, perhaps even coincidentally, with other neurologic disease.<sup>288</sup> The oscillation is rapid in rate (12 to 15 per second) and reflects phasic contraction of the superior oblique muscle.<sup>289</sup> The movement is detected most readily during ophthalmoscopy or by use of the slit lamp. Eye-movement recordings reveal either slow, sustained tonic intorsion and depression, or a phasic intorsion with superimposed high-frequency oscillations in both the vertical and torsional planes; each intorsion is followed by a decreasing-velocity return.<sup>290,291</sup> The spectrum of the oscillations includes low-amplitude components up to 50 Hz and high-amplitude components from 1 to 6 Hz.

Recognition of the entity and reassurance of the patient are essential. Rosenberg and Glaser<sup>292</sup> have presented an extensive longitudinal study of patients and emphasize that the disorder may have varying clinical manifestations and that spontaneous remissions and relapses occur. Treatment with carbamazepine provides short-term benefit to most patients.<sup>292</sup> There is disagreement as to the appropriateness of the term *myokymia*,<sup>293</sup> but the usual benignity of the condition can no longer remain unquestioned.<sup>290</sup> The source of the oscillation is uncertain.<sup>294,295</sup> A review of the history and results of treatment is available.<sup>296</sup>

### BOBBING/DIPPING

Ocular bobbing is a distinctive spontaneous vertical eye-movement disturbance, readily distinguished from downbeat nystagmus and ocular myoclonus. Bobbing refers to fast downward jerks of both eyes followed by a slow drift to midposition. The downward jerks may be disjunct in the two eyes, and often the eyes remain deviated for several seconds before returning to midposi-

tion. Bobbing usually occurs in comatose patients with extensive destruction of the pons, but extrapontine compressions, obstructive hydrocephalus, metabolic encephalopathy, and encephalitis occasionally are causative.<sup>297</sup>

Bobbing can be divided into three types. Typical bobbing involves both eyes and appears in patients with paralysis of horizontal conjugate eye movements. A monocular type reflects coexisting contralateral third-nerve palsy. The third category, atypical bobbing, includes downward bobbing with convergence movements, asymmetric bobbing without an associated oculomotor palsy, and bobbing with intact spontaneous or reflex horizontal eye movements; the latter variety suggests diffuse encephalopathy, hydrocephalus, or organophosphate poisoning, rather than severe intrinsic pontine disease. The pathophysiology of all forms of ocular bobbing is uncertain, but imaginative hypotheses abound. In two cases, a pontine lesion plus an oculomotor lesion resulted in uniocular bobbing,<sup>298</sup> but in another, no explanation could be found.<sup>299</sup>

In addition to these three types of bobbing (typical, monocular, and atypical), we described a phenomenon designated "reverse bobbing," in which the eyes jerked upward with a fast movement and then slowly returned to the horizontal; the patients were deeply comatose as a result of metabolic encephalopathy. Reverse bobbing may coexist with typical bobbing with lesions of the dorsal median portion of the pontine tegmentum.<sup>300</sup>

There are two reports of comatose patients who demonstrated a slow downward eye movement, followed, after a variable delay, by a quick saccade up to midposition. This disorder was called "inverse bobbing" in one report<sup>301</sup> and "ocular dipping" in the other.<sup>302</sup> The latter term (dipping) seems to have achieved favor.<sup>303,304</sup> The upward jerking of the eyes is occasionally associated with contraction of the orbicularis oculi.<sup>305</sup> The phenomenon is regarded as mechanistically similar to the sustained down-gaze deviation seen occasionally in comatose patients and has occurred in a patient with a pinealoblastoma.<sup>306</sup> A depressed level of consciousness is not a prerequisite for its appearance. Some patients in coma may demonstrate all three types of spontaneous vertical movements: ocular bobbing, ocular dipping, and reverse bobbing.<sup>307</sup>

### PSYCHOGENIC FLUTTER (VOLUNTARY "NYSTAGMUS")

Psychogenic flutter consists of bursts of an extremely rapid, conjugate, horizontal oscillation that appears pendular but actually consists of back-to-back saccades.<sup>306</sup> As shown in Table 6, voluntary "nystagmus" is actually flutter.<sup>256</sup> It may be used as a party trick or as a conscious attempt to feign illness. The oscillation is

readily identified by the extreme rapidity (approximately 20 Hz, with a range of 8 to 23 Hz) and brevity of each burst (maximum duration usually less than 30 seconds). Most subjects do not sustain the oscillation for more than 10 seconds and manifest facial distortions with eyelid closure to “rest” their eyes in preparation for another outburst. The ability to perform this stunt may be hereditary and is present in about 5% of the population.<sup>308</sup> Rarely, psychogenic flutter is in the vertical plane<sup>309</sup> or is multidirectional, mimicking opsoclonus.<sup>310</sup>

## REFERENCES

1. Wartenberg R: Diagnostic tests in neurology. A selection for office use. Chicago: Yearbook, 1953:42
2. Doslak MJ, Dell'Osso LF, Daroff RB: Alexander's law: A model and resulting study. *Ann Otol Rhinol Laryngol* 91:316, 1982
3. Hertle RW, Zhu X: Oculographic and clinical characterization of thirty-seven children with anomalous head postures, nystagmus, and strabismus: The basis of a clinical algorithm. *J AAPOS* 4(1):25, 2000
4. Barton JJS, Sharpe JA: Oscillopsia and horizontal nystagmus with accelerating slow phases following lumbar puncture in the Arnold-Chiari malformation. *Ann Neurol* 33:418, 1993
5. Abel LA, Traccis S, Dell'Osso LF, et al: Variable waveforms in downbeat nystagmus imply short-term gain changes. *Ann Neurol* 13:616, 1983
6. CEMAS Working Group: A national eye institute sponsored workshop and publication on the classification of eye movement abnormalities and strabismus (CEMAS). In *The National Eye Institute Publications* (www.nei.nih.gov). National Institutes of Health, National Eye Institute, Bethesda, MD, 2001
7. Gresty MA, Bronstein AM, Page NG, et al: Congenital-type nystagmus emerging in later life *Neurology* 41:653, 1991
8. Dell'Osso LF, Daroff RB: Congenital nystagmus waveforms and foveation strategy. *Doc Ophthalmol* 39:155, 1975
9. Hertle RW, Dell'Osso LF: Clinical and ocular motor analysis of congenital nystagmus in infancy. *J AAPOS* 3(2):70, 1999
10. Hertle RW, Maldonado VK, Maybodi M, et al: Clinical and ocular motor analysis of the infantile nystagmus syndrome in the first 6 months of life. *Br J Ophthalmol* 86(6):670, 2002
11. Kerrison JB, Koenekoop RK, Arnould VJ, et al: Clinical features of autosomal dominant congenital nystagmus linked to chromosome 6p12. *Am J Ophthalmol* 125:64, 1998
12. Dell'Osso LF, Gauthier G, Liberman G, et al: Eye movement recordings as a diagnostic tool in a case of congenital nystagmus. *Am J Optom Arch Am Acad Optom* 49:3, 1972
13. Jacobs JB: An ocular motor system model that simulates congenital nystagmus, including braking and foveating saccades. (Ph.D. Dissertation). In: *Biomedical Engineering. Case Western Reserve University, Cleveland*, 2001:1
14. Dell'Osso LF, Jacobs JB: A robust, normal ocular motor system model with congenital nystagmus (CN) including braking and foveating saccades. In Sharpe JA (ed): *Neuro-Ophthalmology at the beginning of the new millennium*. Englewood: Medimond Medical Publications, 2000:107
15. Dell'Osso LF: Nystagmus basics. Normal models that simulate dysfunction. In Hung GK, Ciuffreda KJ (eds): *Models of the visual system*. New York: Kluwer Academic / Plenum Publishers, 2002:711
16. Dell'Osso LF: A hypothetical fixation system capable of extending foveation in congenital nystagmus. *J Neuro-Ophthalmol* 22:185, 2002
17. Averbuch-Heller L, Dell'Osso LF, Leigh RJ, et al: The torsional component of “horizontal” congenital nystagmus. *J Neuro-Ophthalmol* 22:22, 2002
18. Dell'Osso LF, Daroff RB: Clinical disorders of ocular movement. In Zuber BL (ed): *Models of Oculomotor Behavior and Control*. West Palm Beach: CRC Press Inc, 1981:233
19. Dell'Osso LF, Weissman BM, Leigh RJ, et al: Hereditary congenital nystagmus and gaze-holding failure: The role of the neural integrator. *Neurology* 43:1741, 1993
20. Optican LM, Zee DS: A hypothetical explanation of congenital nystagmus. *Biol Cyber* 50:119, 1984
21. Tusa RJ, Zee DS, Hain TC, et al: Voluntary control of congenital nystagmus. *Clin Vis Sci* 7:195, 1992
22. Harris CM: Problems in modeling congenital nystagmus: Towards a new model. In Findlay JM, Walker R, Kentridge RW (eds): *Eye movement research: Mechanisms, processes and applications*. Amsterdam: Elsevier, 1995:239
23. Tusa RJ, Mustari MJ, Das VE, et al: Animal models for visual deprivation-induced strabismus and nystagmus. In Kaminsky HJ, Leigh RJ (ed): *Neurobiology of eye movements-Ann NY Acad Sci* 956 New York: NYAS, 2002:346
24. Goldstein HP: Extended slow phase analysis of foveation, waveform and null zone in infantile nystagmus. *Invest Ophthalmol Vis Sci* 36:S174, 1995
25. Dell'Osso LF, Flynn JT, Daroff RB: Hereditary congenital nystagmus: An intrafamilial study. *Arch Ophthalmol* 92:366, 1974
26. Tusa RJ, Smith CB, Herdman SJ: The development of nystagmus in infant monkeys following visual deprivation. *Soc Neurosci Abstr* 13:172, 1987
27. Tusa RJ, Mustari MJ, Burrows AF, et al: Gaze-stabilizing deficits and latent nystagmus in monkeys with brief, early-onset visual deprivation: eye movement recordings. *J Neurophysiol* 86:651, 2001
28. Mustari MJ, Tusa RJ, Burrows AF, et al: Gaze-stabilizing deficits and latent nystagmus in monkeys with brief, early-onset visual deprivation: role of the pretectal NOT. *J Neurophysiol* 86:662, 2001
29. Miller JM, Bockisch CJ, Pavlovski DS: Missing lateral rectus force and absence of medial rectus co-contraction in ocular convergence. *J Neurophysiol* 87(5):2421, 2002
30. Demer JL, Poukens V, Micevych P: Nitroxiidergic and catecholaminergic innervation of the smooth muscle of the medial rectus pulley in humans. *Invest Ophthalmol Vis Sci* 36:S959, 1995
31. Demer JL, Miller JM, Poukens V, et al: Evidence for fibromuscular pulleys of the recti extraocular muscles. *Invest Ophthalmol Vis Sci* 36:1125, 1995
32. Bedell HE, White JM: The torsional component of idiopathic congenital nystagmus. *Invest Ophthalmol Vis Sci* 36:S174, 1995
33. Abadi RV, Dickinson CM: Waveform characteristics in congenital nystagmus. *Doc Ophthalmol* 64:153, 1986
34. Dell'Osso LF, Daroff RB: Braking saccade-A new fast eye movement. *Aviat Space Environ Med* 47:435, 1976
35. Jacobs JB, Dell'Osso LF, Erchul DM: Generation of braking saccades in congenital nystagmus. *Neuro Ophthalmol* 21:83, 1999

36. Jacobs JB, Dell'Osso LF, Leigh RJ: Characteristics of braking saccades in congenital nystagmus. *Doc Ophthalmol* 107(2): 137-154, 2003
37. Stahl JS, Rottach KG, Averbuch-Heller L, et al: A pilot study of gabapentin as treatment for acquired nystagmus. *Neuro Ophthalmol* 16:107, 1996
38. Dell'Osso LF: Congenital, latent and manifest latent nystagmus-similarities, differences and relation to strabismus. *Jpn J Ophthalmol* 29:351, 1985
39. Dell'Osso LF, Van der Steen J, Steinman RM, et al: Foveation dynamics in congenital nystagmus I: Fixation. *Doc Ophthalmol* 79:1, 1992
40. Zubcov AA, Stärk N, Weber A, et al: Improvement of visual acuity after surgery for nystagmus. *Ophthalmology* 100:1488, 1993
41. Dell'Osso LF: Fixation characteristics in hereditary congenital nystagmus. *Am J Optom Arch Am Acad Optom* 50:85, 1973
42. Bedell HE, White JM, Abplanalp PL: Variability of foveations in congenital nystagmus. *Clin Vision Sci* 4:247, 1989
43. Abadi RV, Worfolk R: Retinal slip velocities in congenital nystagmus. *Vision Res* 29:195, 1989
44. Guo S, Reinecke RD, Goldstein HP: Visual acuity determinants in infantile nystagmus. *Invest Ophthalmol Vis Sci* 31:83, 1990
45. Abadi RV, Pascal E, Whittle J, et al: Retinal fixation behavior in human albinos. *Optom Vis Sci* 66:276, 1989
46. Dell'Osso LF, Van der Steen J, Steinman RM, et al: Foveation dynamics in congenital nystagmus II: Smooth pursuit. *Doc Ophthalmol* 79:25, 1992
47. Dell'Osso LF, Van der Steen J, Steinman RM, et al: Foveation dynamics in congenital nystagmus III: Vestibulo-ocular reflex. *Doc Ophthalmol* 79:51, 1992
48. Sheth NV, Dell'Osso LF, Leigh RJ, et al: The effects of afferent stimulation on congenital nystagmus foveation periods. *Vision Res* 35:2371, 1995
49. Dell'Osso LF, Jacobs JB: An expanded nystagmus acuity function: Intra- and intersubject prediction of best-corrected visual acuity. *Doc Ophthalmol* 104:249, 2002
50. Dell LF: See-saw nystagmus in dogs and humans: An international, across-discipline, serendipitous collaboration. *Neurology* 47:1372, 1996
51. Dell'Osso LF, Hertle RW, Williams RW, et al: A new surgery for congenital nystagmus: Effects of tenotomy on an achiasmatic canine and the role of extraocular proprioception. *J AAPOS* 3:166, 1999
52. Dell'Osso LF, Hertle RW, FitzGibbon EJ, et al: Preliminary results of performing the tenotomy procedure on adults with congenital nystagmus (CN)-a gift from "man's best friend." In Sharpe JA (ed): *Neuro-ophthalmology at the beginning of the new millennium*. Englewood: Medimond Medical Publications, 2000:101
53. Hertle RW, Dell'Osso LF, FitzGibbon EJ, et al: Horizontal rectus tenotomy in patients with congenital nystagmus (CN): Results in ten adults. *Ophthalmology*, 2003 (in press)
54. Büttner-Ennever JA, Horn AKE, Scherberger H, et al: Motoneurons of twitch and non-twitch extraocular fibres in the abducens, trochlear and oculomotor nuclei of monkeys. *J Comp Neurol* 438:318, 2001
55. Büttner-Ennever JA, Horn AKE, Graf W, et al: Modern concepts of brainstem anatomy. From extraocular motoneurons to proprioceptive pathways. In Kaminski HJ, Leigh RJ (eds): *Neurobiology of eye movements. From molecules to behavior*. Ann NY Acad Sci 956. New York: NYAS, 2002:75
56. Blumer R, Lukas J-R, Aigner M, et al: Fine structural analysis of extraocular muscle spindles of a two-year-old human infant. *Invest Ophthalmol Vis Sci* 40:55, 1999
57. Chaum EHM: Congenital nystagmus associated with multiple congenital anomalies of the extraocular muscles. *J Pediatr Ophthalmol Strab* 36:155, 1999
58. Hertle RW, Chan C, Galita DA, et al: Neuroanatomy of the extraocular muscle tendon entheses in macaque, normal human and patients with congenital nystagmus. *J AAPOS* 6:319, 2002
59. Shallo-Hoffmann JA, Visco Jr. F, Tusa RJ: Mis-use of the artificial divergence operation to treat congenital nystagmus in a patient with infantile strabismus and acromatopsia: Analysis of eye movement recordings. In Sharpe JA (ed): *Neuro-ophthalmology at the beginning of the new millennium*. Englewood: Medimond Medical Publications, 2000:125
60. Serra A, Dell'Osso LF, Jacobs JB: Effects on congenital nystagmus (CN) of combined gaze-angle and vergence variation: therapeutic implications. p. ARVO Abstr 2656. Annual Meeting Abstract and Program Planner [on CD-ROM or accessed at [www.arvo.org](http://www.arvo.org)], 2002
61. Halmagyi GM, Gresty MA, Leech J: Reversed optokinetic nystagmus (OKN): Mechanism and clinical significance. *Ann Neurol* 7:429, 1980
62. Gresty MA, Halmagyi GM, Leech J: The relationship between head and eye movement in congenital nystagmus with head shaking: objective recordings of a single case. *Br J Ophthalmol* 62:533, 1978
63. Bedell HE, Bollenbacher MA: Perception of motion smear in normal observers and in persons with congenital nystagmus. *Invest Ophthalmol Vis Sci* 37:188, 1996
64. Bedell HE: Perception of a clear and stable visual world with congenital nystagmus. *Optom Vis Sci* 77:573, 1999
65. Dell'Osso LF, Leigh RJ: Oscillopsia suppression: Efference copy or foveation periods? *Invest Ophthalmol Vis Sci* 36:S174, 1995
66. Dell'Osso LF, Leigh RJ: Foveation period stability and oscillopsia suppression in congenital nystagmus. An hypothesis. *Neuro Ophthalmol* 12:169, 1992
67. Dell'Osso LF, Leigh RJ: Ocular motor stability of foveation periods. Required conditions for suppression of oscillopsia. *Neuro Ophthalmol* 12:303, 1992
68. Dell'Osso LF: Evaluation of smooth pursuit in the presence of congenital nystagmus. *Neuro Ophthalmol* 6:383, 1986
69. Leigh RJ, Dell'Osso LF, Yaniglos SS, et al: Oscillopsia, retinal image stabilization and congenital nystagmus. *Invest Ophthalmol Vis Sci* 29:279, 1988
70. Goldstein HP, Gottlob I, Fendick MG: Visual remapping in infantile nystagmus. *Vision Res* 32:1115, 1992
71. Bedell HE, Currie DC: Extraretinal signals for congenital nystagmus. *Invest Ophthalmol Vis Sci* 34:2325, 1993
72. Bedell HE: Perception of a clear and stable visual world with congenital nystagmus. *Optom Vis Sci* 77(11):573, 2000
73. Abel LA, Williams IM, Levi L: Oscillopsia suppression in congenital nystagmus: Dependence on foveation stability and duration. *Invest Ophthalmol Vis Sci* 31:122, 1990
74. Hertle RW, FitzGibbon EJ, Avallone JM, et al: Onset of oscillopsia after visual maturation in patients with congenital nystagmus. *Ophthalmol* 108:2301, 2001
75. Shallo-Hoffmann J, Bronstein AM, Acheson J, et al: Vertical and horizontal motion perception in congenital nystagmus. *Neuro-Ophthalmol* 19:171, 1998
76. Shallo-Hoffmann J, Wolsley CJ, Acheson JF, et al: Reduced

- duration of a visual motion aftereffect in congenital nystagmus. *Documenta Ophthalmologica* 95(3-4):301, 1998
77. Dell'Osso LF, Daroff RB, Tomsak RL: Migraine aura and diplopia phenomenology associated with congenital nystagmus. *Neuro-Ophthalmol* 26:79, 2001
78. Jacobs JB, Serra A, Dell'Osso LF: Oscillating scotomas of migraine auras or "induced" see-saw nystagmus (SSN) with loss of vertical fusion in congenital nystagmus (CN). p. ARVO Abstr 2657. Annual Meeting Abstract and Program Planner [on CD-ROM or accessed at [www.arvo.org](http://www.arvo.org)], 2002
79. Ukwade MT, Bedell HE, White JM: Orientation discrimination and variability of foveal eye position in congenital nystagmus. *Vision Res* 42:2395, 2002
80. Daroff RB, Dell'Osso LF: Periodic alternating nystagmus and the shifting null. *Can J Otolaryngol* 3:367, 1974
81. Kurzan R, Büttner U: Smooth pursuit mechanisms in congenital nystagmus. *Neuro Ophthalmol* 9:313, 1989
82. Dell'Osso LF, Leigh RJ, Daroff RB: Suppression of congenital nystagmus by cutaneous stimulation. *Neuro Ophthalmol* 11: 173, 1991
83. Abadi RV: Visual performance with contact lenses and congenital idiopathic nystagmus. *Br J Physiol Optics* 33:32, 1979
84. Allen ED, Davies PD: Role of contact lenses in the management of congenital nystagmus. *Br J Ophthalmol* 67:834, 1983
85. Dell'Osso LF, Traccis S, Abel LA, et al: Contact lenses and congenital nystagmus. *Clin Vision Sci* 3:229, 1988
86. Matsubayashi K, Fukushima M, Tabuchi A: Application of soft contact lenses for children with congenital nystagmus. *Neuro Ophthalmol* 12:47, 1992
87. Dell'Osso LF: Development of new treatments for congenital nystagmus. In Kaminski HJ, Leigh RJ (eds): *Neurobiology of eye movements. From molecules to behavior*-Ann NY Acad Sci 956. New York: NYAS, 2002:361
88. Shallo-Hoffmann J, Watermeier D, Petersen J, et al: Fast-phase instabilities in normally sighted relatives of congenital nystagmus patients-autosomal dominant and x-chromosome recessive modes of inheritance. *Neurosurg Rev* 11:151, 1988
89. Gottlob I: Eye movement abnormalities in carriers of blue-cone monochromatism. *Invest Ophthalmol Vis Sci* 35:3556, 1994
90. Dell'Osso LF, Schmidt D, Daroff RB: Latent, manifest latent and congenital nystagmus. *Arch Ophthalmol* 97:1877, 1979
91. Abadi RV, Scallan CJ, Clement RA: The characteristics of dynamic overshoots in square-wave jerks, and in congenital and manifest latent nystagmus. *Vision Research* 40:2813, 2000
92. Abadi RV, Scallan CJ: Waveform characteristics of manifest latent nystagmus. *DF Investigative Ophthalmology and Visual Science* 41:3805, 2000
93. Averbuch-Heller L, Dell'Osso LF, Jacobs JB, et al: Latent and congenital nystagmus in Down syndrome. *J Neuro-Ophthalmol* 19:166, 1999
94. Shallo-Hoffmann J, Faldon ME, Acheson JF, et al: Temporally directed deficits for the detection of visual motion in latent nystagmus: Evidence for adaptive processing. *Neuro Ophthalmol* 16:343, 1996
95. Dickinson CM, Abadi RV: Pursuit and optokinetic responses in latent/manifest latent nystagmus. *Invest Ophthalmol Vis Sci* 31:1599, 1990
96. Fuchs AF, Mustari MJ: The optokinetic response in primates and its possible neuronal substrate. In Wallman J, Miles FA (eds): *Reviews of oculomotor research. Vol. 5. Visual motion and its role in stabilization of the gaze*. Amsterdam: Elsevier, 1993:343
97. Dell'Osso LF, Abel LA, Daroff RB: Latent/manifest latent nystagmus reversal using an ocular prosthesis. Implications for vision and ocular dominance. *Invest Ophthalmol Vis Sci* 28: 1873, 1987
98. Shawkat FS, Harris CM, Taylor DS: Spontaneous reversal of nystagmus in the dark. *Br J Ophthalmol* 85:428, 2001
99. Shallo-Hoffmann JA, Visco Jr. F, Ficarra A, et al: Alternating vertical component associated with manifest latent nystagmus. In Sharpe JA (ed): *Neuro-Ophthalmology at the beginning of the new millennium*. Englewood: Medimond Medical Publications, 2000:119
100. Brodsky MC: Dissociated vertical divergence. A righting reflex gone wrong. *Arch Ophthalmol* 117:1216, 1999
101. Steinbach MJ, Smith D, Crawford JS: Egocentric localization changes following unilateral strabismus surgery. *J Pediatr Ophthalmol Strab* 25:115, 1988
102. Dell'Osso LF, Leigh RJ, Sheth NV, et al: Two types of foveation strategy in "latent" nystagmus. Fixation, visual acuity and stability. *Neuro Ophthalmol* 15:167, 1995
103. Dell'Osso LF, Jacobs JB: A robust, normal ocular motor system model with latent/manifest latent nystagmus (LMLN) and dual-mode fast phases. In Sharpe JA (ed): *Neuro-ophthalmology at the beginning of the new millennium*. Englewood: Medimond Medical Publications, 2000:113
104. Dell'Osso LF, Jacobs JB: A normal ocular motor system model that simulates the dual-mode fast phases of latent/manifest latent nystagmus. *Biological Cybernetics* 85:459, 2001
105. Dell'Osso LF, Traccis S, Abel LA: Strabismus-A necessary condition for latent and manifest latent nystagmus. *Neuro Ophthalmol* 3:247, 1983
106. Schor CM, Wilson N, Fusaro R: Prediction of early onset esotropia from components of the infantile squint syndrome. *Invest Ophthalmol Vis Sci* 36:S645, 1995
107. Zubcov AA, Reinecke RD, Gottlob I, et al: Treatment of manifest latent nystagmus. *Am J Ophthalmol* 110:160, 1990
108. Abadi RV, Scallan C: Manifest latent and congenital nystagmus waveforms in the same subject. *Neuro-Ophthalmol* 21: 211, 1999
109. Abadi RV, Bjerre A: Motor and sensory characteristics of infantile nystagmus. *Br J Ophthalmol* 86:1152, 2002
110. Gresty MA, Metcalfe T, Timms C, et al: Neurology of latent nystagmus. *Brain* 115:1303, 1992
111. Dell'Osso LF, Ellenberger JC, Abel LA, et al: The nystagmus blockage syndrome: Congenital nystagmus, manifest latent nystagmus or both? *Invest Ophthalmol Vis Sci* 24:1580, 1983
112. Hoyt CS, Aicardi E: Acquired monocular nystagmus in monozygous twins. *J Pediatr Ophthalmol Strab* 16:115, 1979
113. Gresty MA, Leech J, Sanders MD, et al: A study of head and eye movement in spasmus nutans. *Br J Ophthalmol* 160:652, 1976
114. Weissman BM, Dell'Osso LF, Abel LA, et al: Spasmus nutans: A quantitative prospective study. *Arch Ophthalmol* 105:525, 1987
115. Yee RD, Baloh RW, Honrubia V: Eye movement abnormalities in rod monochromacy. *Ophthalmology* 88:1010, 1981
116. Leigh RJ, Zee DS: Eye movements of the blind. *Invest Ophthalmol Vis Sci* 19:328, 1980
117. Melvill JG, Mandl G, Cynader M, et al: Eye oscillations in strobe reared cats. *Brain Res* 209:47, 1981
118. Lavery MA, O'Neill JF, Chu FC, et al: Acquired nystagmus in early childhood: A presenting sign of intracranial tumor. *Ophthalmology* 91:425, 1984

119. Lambert SR, Newman NJ: Retinal disease masquerading as spasmus nutans. *Neurology* 43:1607, 1993
120. Allarakchia IN: Opsoclonus-myoclonus presenting with features of spasmus nutans. *J Child Neurol* 10:67, 1995
121. Barton JJS, Cox TA: Acquired pendular nystagmus: Its characteristics, localizing value and pathophysiology. *J Neurol Neurosurg Psychiatr* 56:262, 1993
122. Barton JJS: Is acquired pendular nystagmus always phase locked? *J Neurol Neurosurg Psychiatr* 57:1263, 1994
123. Das VE, Oruganti P, Kramer PD, et al: Experimental tests of a neural-network model for ocular oscillations caused by disease of central myelin. *Exp Brain Res* 133:189, 2000
124. Kori AA, Robin NH, Erchul DM, et al: Pendular nystagmus in autosomal peroxisomal disorder. *Arch Neurol* 55:554, 1998
125. Averbuch-Heller L, Tusa RJ, Fuhry L, et al: A double-blind controlled study of gabapentin and baclofen as treatment for acquired nystagmus. *Ann Neurol* 41:818, 1997
126. Stahl JS, Averbuch-Heller L, Leigh RJ: Acquired nystagmus. *Arch Ophthalmol* 118:544, 2000
127. Averbuch-Heller L, Zivotofsky AZ, Das VE, et al: Investigations of the pathogenesis of acquired pendular nystagmus. *Brain* 118:369, 1995
128. Barton JS, Huaman AG, Sharpe JA: Muscarinic antagonists in the treatment of acquired pendular and downbeat nystagmus: A double-blind, randomized trial of three intravenous drugs. *Ann Neurol* 35:319, 1994
129. Tomsak RL, Remler BF, Averbuch-Heller L, et al: Unsatisfactory treatment of acquired nystagmus with retrobulbar injection of botulinum toxin. *Am J Ophthalmol* 119:489, 1995
130. Averbuch-Heller L, Remler B: Opsoclonus. *Seminars Neurol* 16:21, 1996
131. Brandt T, Daroff RB: The multisensory physiological and pathological vertigo syndromes. *Ann Neurol* 7:195, 1980
132. Holtmann S, Clarke A, Scherer H: Cervical receptors and the direction of body sway. *Arch Otorhinolaryngol* 246:61, 1989
133. Zee DS, Preziosi TJ, Proctor LR: Bechterew's phenomenon in a human patient. *Ann Neurol* 12:495, 1982
134. Dayal VS, Farkashidy J, Mai M, et al: Vestibular compensation and nystagmus. *Acta Otolaryngol (Stockh) Suppl* 406:105, 1984
135. Reker U: Peripheral-vestibular spontaneous nystagmus. Analysis of reproducibility and methodologies. *Arch Otorhinolaryngol* 226:225, 1980
136. Baloh RW, Winder A: Acetazolamide-responsive vestibulocerebellar syndrome: Clinical and oculographic features. *Neurology* 41:429, 1991
137. Kramer PL, Yue Q, Ganchar ST, et al: A locus for the nystagmus-associated form of episodic ataxia maps to an 11 cM region on chromosome 19p. *Am J Hum Genet* 57:182, 1995
138. Lawden MC, Bronstein AM, Kennard C: Repetitive paroxysmal nystagmus and vertigo. *Neurology* 45:276, 1995
139. Abel LA, Parker L, Daroff RB, et al: Endpoint nystagmus. *Invest Ophthalmol Vis Sci* 17:539, 1978
140. Shallo-Hoffmann J, Schwarze H, Simonsz HJ, et al: A reexamination of end-point and rebound nystagmus in normals. *Invest Ophthalmol Vis Sci* 31:388, 1990
141. Eizenman M, Cheng P, Sharpe JA, et al: End-point nystagmus and ocular drift: An experimental and theoretical study. *Vision Res* 30:863, 1990
142. Lopez L, Bronstein AM, Gresty MA, et al: Torsional nystagmus. A neuro-otological and MRI study of thirty-five cases. *Brain* 115:1107, 1992
143. Halmagyi GM, Aw ST, Dehaene I, et al: Jerk-waveform seesaw nystagmus due to unilateral meso-diencephalic lesion. *Brain* 117:789, 1994
144. Barton JJS: Blink- and saccade-induced seesaw nystagmus. *Neurology* 45:831, 1995
145. Frisén L, Wikkelsö C: Posttraumatic seesaw nystagmus abolished by ethanol ingestion. *Neurology* 36:841, 1986
146. Zimmerman CF, Roach ES, Troost BT: See-saw nystagmus associated with Chiari malformation. *Arch Neurol* 43:299, 1986
147. Samkoff LM, Smith CR: See-saw nystagmus in a patient with clinically definite MS. *Eur Neurol* 34:228, 1994
148. May EF, Truxal AR: Loss of vision may result in seesaw nystagmus. *J Neuro-Ophthalmol* 17:84, 1997
149. Nakada T, Kwee IL: Role of visuo-vestibular interaction in pathological ocular oscillation: New model and control system analysis. *Med Hypotheses* 38:261, 1992
150. Bergin DJ, Halpern J: Congenital see-saw nystagmus associated with retinitis pigmentosa. *Ann Ophthalmol* 18:346, 1986
151. Daroff RB, Hoyt WF, Sanders MD, et al: Gaze-evoked eyelid and ocular nystagmus inhibited by the near reflex: Unusual ocular motor phenomena in a lateral medullary syndrome. *J Neurol Neurosurg Psychiatr* 31:362, 1968
152. Safran AB, Berney J, Safran E: Convergence-evoked eyelid nystagmus. *Am J Ophthalmol* 93:48, 1982
153. Lavin PJM, Traccis S, Dell'Osso LF, et al: Downbeat nystagmus with a pseudocycloid waveform: improvement with base-out prisms. *Ann Neurol* 13:621, 1983
154. Cox TA, Corbett JJ, Thompson HS, et al: Upbeat nystagmus changing to downbeat nystagmus with convergence. *Neurology* 31:891, 1981
155. Noda S, Ide K, Umezaki H, et al: Repetitive divergence. *Ann Neurol* 21:109, 1987
156. Oohira A, Goto K, Ozawa T: Convergence nystagmus. *Neuro Ophthalmol* 6:313, 1986
157. Nelson KR, Brenner RP, Carlow TJ: Divergent-convergent eye movements and transient eyelid opening associated with an EEG burst-suppression pattern. *Neuro Ophthalmol* 6:43, 1986
158. Averbuch-Heller L, Zivotofsky AZ, Remler BF, et al: Convergent-divergent pendular nystagmus: Possible role of the vergence system. *Neurology* 45:509, 1995
159. Sharpe JA, Hoyt WF, Rosenberg MA: Convergence-evoked nystagmus: Congenital and acquired forms. *Arch Neurol* 32:191, 1975
160. Hara T, Kawazawa S, Abe Y, et al: Conjugate pendular nystagmus evoked by accommodative vergence. *Eur Neurol* 25:369, 1986
161. Guyer DR, Lessell S: Periodic alternating nystagmus associated with albinism. *J Clin Neuro Ophthalmol* 6:82, 1986
162. Abadi RV, Pascal E: Periodic alternating nystagmus in humans with albinism. *Invest Ophthalmol Vis Sci* 35:4080, 1994
163. Shallo-Hoffmann J, Faldon M, Tusa RJ: The incidence and waveform characteristics of periodic alternating nystagmus in congenital nystagmus. *Invest Ophthalmol Vis Sci* 40:2546, 1999
164. Shallo-Hoffmann J, Riordan-Eva P: Recognizing periodic alternating nystagmus. *Strabismus* 9(4):203, 2001
165. Dell'Osso LF, Shallo-Hoffmann J: Congenital, periodic alternating nystagmus with unusual slow-phase waveforms [ARVO Abstract]. *Invest Ophthalmol Vis Sci* 41:S702, 2000
166. Dun S, Shallo-Hoffmann J, Dell'Osso LF: Two time-varying components can produce anomalous slow-phase appearances

- in congenital nystagmus (CN) [ARVO Abstract]. Invest Ophthalmol Vis Sci 42:S165, 2001
167. Shallo-Hoffmann J, Dell'Osso LF, Dun S: Time-varying, slow phase component interaction in congenital nystagmus. Vision Res, 2003 (in press)
168. Leigh RJ, Robinson DA, Zee DS: A hypothetical explanation for periodic alternating nystagmus: Instability in the optokinetic-vestibular system. Ann NY Acad Sci 374:619, 1981
169. Furman JMR, Wall IIIC, Pang D: Vestibular function in periodic alternating nystagmus. Brain 113:1425, 1990
170. Waespe W, Cohen B, Raphan T: Dynamic modification of the vestibulo-ocular reflex by the nodulus and uvula. Science 228:199, 1985
171. Campbell JWW: Periodic alternating nystagmus in phenytoin intoxication. Arch Neurol 37:178, 1980
172. Halmagyi GM, Rudge P, Gresty MA, et al: Treatment of periodic alternating nystagmus. Ann Neurol 8:609, 1980
173. Nuti D, Ciacci G, Giannini F, et al: Aperiodic alternating nystagmus: Report of two cases and treatment by baclofen. Ital J Neurol Sci 7:453, 1986
174. Lewis JM, Kline LB: Periodic alternating nystagmus associated with periodic alternating skew deviation. J Clin Neuro Ophthalmol 3:115, 1983
175. Kennard C, Barger G, Hoyt WF: The association of periodic alternating nystagmus with periodic alternating gaze. J Clin Neuro Ophthalmol 1:191, 1981
176. Baloh RW, Spooner JW: Downbeat nystagmus: A type of central vestibular nystagmus. Neurology 31:304, 1981
177. Halmagyi GM, Rudge P, Gresty MA, et al: Downbeating nystagmus. A review of 62 cases. Arch Neurol 40:777, 1983
178. Rosengart A, Hedges IIITR, Teal PA, et al: Intermittent downbeat nystagmus due to vertebral artery compression. Neurology 43:216, 1993
179. Schmidt D: Downbeat nystagmus. A clinical review. Neuro Ophthalmol 11:247, 1991
180. Egan DJ: Optical treatment of downbeat nystagmus induced oscillopsia. Invest Ophthalmol Vis Sci 36:S351, 1995
181. Gresty MA, Barratt H, Rudge P, et al: Analysis of downbeat nystagmus. Arch Neurol 43:52, 1986
182. Albera R, Luda E, Machetta G, et al: Cyclosporine A as a possible cause of upbeating nystagmus. Neuro Ophthalmol 17:163, 1997
183. Ranalli PJ, Sharpe JA: Upbeat nystagmus and the ventral tegmental pathway of the upward vestibulo-ocular reflex. Neurology 38:1329, 1988
184. Fisher A, Gresty MA, Chambers B, et al: Primary position upbeating nystagmus: A variety of central positional nystagmus. Brain 106:949, 1983
185. Keane JR, Itabashi HH: Upbeat nystagmus: Clinicopathologic study of two patients. Neurology 37:491, 1987
186. Büttner U, Helmchen C, Büttner-Ennever JA: The localizing value of nystagmus in brainstem disorders. Neuro Ophthalmol 15:283, 1995
187. Kattah JC, Dagi TF: Compensatory head tilt in upbeating nystagmus. J Clin Neuro Ophthalmol 10:27, 1990
188. Sibony PA, Evinger C, Manning KA: Tobacco-induced primary-position upbeat nystagmus. Ann Neurol 21:53, 1987
189. Bondar RL, Sharpe JA, Lewis AJ: Rebound nystagmus in olivocerebellar atrophy: A clinicopathological correlation. Ann Neurol 15:474, 1984
190. Helmchen C, Büttner U: Centripetal nystagmus in a case of Creutzfeldt-Jakob disease. Neuro Ophthalmol 15:187, 1995
191. Tracis S, Rosati G, Monaco MF, et al: Successful treatment of acquired pendular elliptical nystagmus in multiple sclerosis with isoniazid and base-out prisms. Neurology 40:492, 1990
192. De Jong JMBV, Bles W, Bovenkerk G: Nystagmus, gaze shift, and self-motion perception during sinusoidal head and neck rotation. Ann NY Acad Sci 374:590, 1981
193. Hamann KF: Kritische Anmerkungen zum sogenannten zervikogenen Schwindel. Laryngol Rhinol Otol 64:156, 1985
194. Norre ME, Stevens A: Diagnostic and semiological problem with special emphasis upon "cervical nystagmus." Acta Otorhinolaryngol (Belgium) 41:436, 1987
195. Schmidt D, Dell'Osso LF, Abel LA, et al: Myasthenia gravis: Dynamic changes in saccadic waveform, gain and velocity. Exp Neurol 68:365, 1980
196. Howard RS: A case of convergence evoked eyelid nystagmus. J Clin Neuro Ophthalmol 6:169, 1986
197. Brodsky MC, Boop FA: Lid nystagmus as a sign of intrinsic midbrain disease. J Neuro-Ophthalmol 15:236, 1995
198. Lavin PJM: Pupillary oscillations synchronous with ictal nystagmus. Neuro Ophthalmol 6:113, 1986
199. Kaplan PW, Tusa RJ: Neurophysiologic and clinical correlations of epileptic nystagmus. Neurology 43:2508, 1993
200. Tusa RJ, Kaplan PW, Hain TC, et al: Ipsiversive eye deviation and epileptic nystagmus. Neurology 40:662, 1989
201. Thurston SE, Leigh RJ, Osorio I: Epileptic gaze deviation and nystagmus. Neurology 35:1518, 1985
202. Von Baumgarten R, Benson A, Brand U, et al: Effects of rectilinear acceleration and optokinetic and caloric stimulations in space. Science 225:208, 1984
203. Paige GD: Caloric responses after horizontal canal inactivation. Acta Otolaryngol (Stockh) 100:321, 1985
204. Büttner UW, Zee DS: Vestibular testing in comatose patients. Arch Neurol 46:561, 1989
205. Baloh RW, Honrubia V, Jacobson K: Benign positional vertigo: Clinical and oculographic features in 240 cases. Neurology 37:371, 1987
206. Lin J, Elidan J, Baloh RW, et al: Direction-changing positional nystagmus. Am J Otolaryngol 7:306, 1986
207. Brandt T, Stedden S, Daroff RB: Therapy for benign paroxysmal positioning vertigo, revisited. Neurology 44:796, 1994
208. Kattah JC, Kolsky MP, Luessenhop AJ: Positional vertigo and the cerebellar vermis. Neurology 34:527, 1984
209. Büttner U, Brandt T, Helmchen C: The direction of nystagmus is important for the diagnosis of central paroxysmal positioning nystagmus (cPPV). Neuro-Ophthalmol 21:97, 1999
210. Baloh RW, Jacobson K, Honrubia V: Horizontal semicircular canal variant of benign positional vertigo. Neurology 43:2542, 1993
211. Korres S, Balatsouras DG, Kaberos A, et al: Occurrence of semicircular canal involvement in benign paroxysmal positional vertigo. Otol Neurotol 23(6):926, 2002
212. Lempert T: Horizontal benign positional vertigo. Neurology 44:2213, 1994
213. Esser J, Brandt T: Pharmakologisch verursachte Augenbewegungsstörungen-Differentialdiagnose und Wirkungsmechanismen. Fortschr Neurol Psychiat 51:41, 1983
214. Coppeto JR, Monteiro MLR, Lessell S, et al: Downbeat nystagmus. Arch Neurol 40:754, 1983
215. Corbett JJ, Jacobson DM, Thompson HS, et al: Downbeating nystagmus and other ocular motor defects caused by lithium toxicity. Neurology 39:481, 1989

216. Rosenberg ML: Reversible downbeat nystagmus secondary to excessive alcohol intake. *J Clin Neuro Ophthalmol* 7:23, 1987
217. Maas EF, Ashe J, Spiegel BA, et al: Acquired pendular nystagmus in toluene addiction. *Neurology* 41:282, 1991
218. Kattah JC, Schilling R, Liu SJ, et al: Oculomotor manifestations of acute alcohol intoxication. In Smith JL, Katz RS (eds): *Neuro-ophthalmology enters the nineties*. Miami: Dutton Press, 1988:233
219. Yokota JJ, Imai H, Okuda O, et al: Inverted Bruns' nystagmus in arachnoid cysts of the cerebellopontine angle. *Eur Neurol* 33:62, 1993
220. Waespe W, Wichmann W: Oculomotor disturbances during visual-vestibular interaction in Wallenberg's lateral medullary syndrome. *Brain* 113:821, 1990
221. Waespe W, Baumgartner R: Enduring dysmetria and impaired gain adaptivity of saccadic eye movements in Wallenberg's lateral medullary syndrome. *Brain* 115:1125, 1992
222. Dieterich M, Brandt T: Wallenberg's syndrome: Lateropulsion, cyclorotation, and subjective visual vertical in thirty-six patients. *Ann Neurol* 31:399, 1992
223. Morrow MJ, Sharpe JA: Torsional nystagmus in the lateral medullary syndrome. *Ann Neurol* 24:390, 1988
224. Brazis PW: Ocular motor abnormalities in Wallenberg's lateral medullary syndrome. *Mayo Clin Proc* 67:365, 1992
225. Ranalli PJ, Sharpe JA: Contrapulsion of saccades and ipsilateral ataxia: A unilateral disorder of the rostral cerebellum. *Ann Neurol* 20:311, 1986
226. Solomon D, Galetta SL, Grant TL: Possible mechanisms for horizontal gaze deviation and lateropulsion in the lateral medullary syndrome. *J Neuro-Ophthalmol* 15:26, 1995
227. Collewijn H, Apkarian P, Spekreijse H: The oculomotor behaviour of human albinos. *Brain* 108:1, 1985
228. Apkarian P, Shallo-Hoffmann J: VEP projections in congenital nystagmus; VEP asymmetry in albinism: A comparison study. *Invest Ophthalmol Vis Sci* 32:2653, 1991
229. Cheong PYY, King RA, Bateman JB: Oculocutaneous albinism: Variable expressivity of nystagmus in a sibship. *J Pediatr Ophthalmol Strab* 29:185, 1992
230. McCarty JW, Demer JL, Hovis LA, et al: Ocular motility anomalies in developmental misdirection of the optic chiasm. *Am J Ophthalmol* 113:86, 1992
231. Williams RW, Hogan D, Garraghty PE: Target recognition and visual maps in the thalamus of achiasmatic mutant dogs. *Nature* 367:637, 1994
232. Apkarian P, Dell'Osso LF, Ferraresi A, et al: Ocular motor abnormalities in human achiasmatic syndrome. *Invest Ophthalmol Vis Sci* 35:1410, 1994
233. Dell'Osso LF: Evidence suggesting individual ocular motor control of each eye (muscle). *J Vestib Res* 4:335, 1994
234. Dell'Osso LF, Williams RW: Ocular motor abnormalities in achiasmatic mutant Belgian sheepdogs: Unyoked eye movements in a mammal. *Vision Res* 35:109, 1995
235. Dell'Osso LF, Williams RW, Jacobs JB, et al: The congenital and see-saw nystagmus in the prototypical achiasma of canines: comparison to the human achiasmatic prototype. *Vision Res* 38:1629, 1998
236. Dell'Osso LF, Hogan D, Jacobs JB, et al: Eye movements in canine hemichiasma: Does human hemichiasma exist? *Neuro-Ophthalmol* 22:47, 1999
237. Hertle RW, Dell'Osso LF, FitzGibbon EJ, et al: Clinical, radiographic, electrophysiologic findings in patients with achiasma or hypochiasma. *Neuro-Ophthalmol* 26:43, 2002
238. Dell'Osso LF, Daroff RB: Two additional scenarios for see-saw nystagmus: Achiasma and hemichiasma. *J Neuro-Ophthalmol* 18:112, 1998
239. Acland GM, Aguirre GD, Ray J, et al: Gene therapy restores vision in a canine model of childhood blindness. *Nat Genet* 28(1):92, 2001
240. Jacobs JB, Dell'Osso LF, Hertle RW, et al: Gene therapy to abolish congenital nystagmus in RPE65-deficient canines. p. ARVO Abstr 4249. Annual Meeting Abstract and Program Planner [on CD-ROM or accessed at [www.arvo.org](http://www.arvo.org)], 2003
241. Doslak MJ, Dell'Osso LF, Daroff RB: Multiple double saccadic pulses occurring with other saccadic intrusions and oscillations. *Neuro Ophthalmol* 3:109, 1983
242. Whicker L, Abel LA, Dell'Osso LF: Smooth pursuit and fixation in the parents of schizophrenics. *Soc Neurosci Abstr* 9:70, 1983
243. Shaffer DM, Krisky CM, Sweeney JA: Frequency and metrics of square-wave jerks: Influences of task-demand characteristics. *Invest Ophthalmol Vis Sci* 44:1082, 2003
244. Abel LA, Tracis S, Dell'Osso LF, et al: Square wave oscillation. The relationship of saccadic intrusions and oscillations. *Neuro Ophthalmol* 4:21, 1984
245. Dell'Osso LF, Troost BT, Daroff RB: Macro square wave jerks. *Neurology* 25:975, 1975
246. Dell'Osso LF, Abel LA, Daroff RB: "Inverse latent" macro square wave jerks and macro saccadic oscillations. *Ann Neurol* 2:57, 1977
247. Garbutt S, Dell'Osso LF, Jacobs JB: "Staircase" saccadic intrusions and transient yoking and neural integrator failures associated with cerebellar hypoplasia. p. ARVO Abstr 1968. Annual Meeting Abstract and Program Planner [on CD-ROM or accessed at [www.arvo.org](http://www.arvo.org)], 2003
248. Selhorst JB, Stark L, Ochs AL, et al: Disorders in cerebellar ocular motor control. II. Macro saccadic oscillation: an oculographic, control system and clinico-anatomical analysis. *Brain* 99:509, 1976
249. Herishanu YO, Sharpe JA: Saccadic intrusions in internuclear ophthalmoplegia. *Ann Neurol* 14:67, 1983
250. Sharpe JA, Kim JS: Ocular oscillations and intrusions with palatal tremor. *Neurol* 54 suppl 3:A250, 2000
251. Selhorst JB, Stark L, Ochs AL, et al: Disorders in cerebellar ocular motor control. I. Saccadic overshoot dysmetria: an oculographic, control system and clinico-anatomical analysis. *Brain* 99:497, 1976
252. Vilis T, Snow R, Hore J: Cerebellar saccadic dysmetria is not equal in the two eyes. *Exp Brain Res* 51:343, 1983
253. Bötzel K, Rottach K, Büttner U: Normal and pathological saccadic dysmetria. *Brain* 116:337, 1993
254. Büttner U, Straube A, Spuler A: Saccadic dysmetria and "intact" smooth pursuit eye movements after bilateral deep cerebellar nuclei lesions. *J Neurol Neurosurg Psychiatr* 57:832, 1994
255. Kanayama R, Bronstein AM, Shallo-Hoffmann J, et al: Visually and memory guided saccades in a case of cerebellar saccadic dysmetria. *J Neurol Neurosurg Psychiatr* 57:1081, 1994
256. Zee DS, Robinson DA: A hypothetical explanation of saccadic oscillations. *Ann Neurol* 5:405, 1979
257. Hain TC, Zee DS, Mordes M: Blink induced saccadic oscillations. *Ann Neurol* 19:299, 1986
258. Ashe J, Hain TC, Zee DS, et al: Microsaccadic flutter. *Brain* 114:461, 1991
259. Kaminski HJ, Zee DS, Leigh RJ, et al: Ocular flutter and ataxia associated with AIDS-related complex. *Neuro Ophthalmol* 11:163, 1991

260. Dropcho EJ, Kline LB, Riser J: Antineuronal (anti-Ri) antibodies in a patient with steroid-responsive opsoclonus-myoclonus. *Neurology* 43:207, 1993
261. Prier S, Larmande P, Dairou R, et al: Oscillations macro-saccadiques au cours d'un cas d'encéphalopathie myoclonique paraneoplasique. *Rev Neurol* 135:339, 1979
262. Furman JMR, Eidelman BH, Fromm GH: Spontaneous remission of paraneoplastic ocular flutter and saccadic intrusions. *Neurology* 38:499, 1988
263. Wong AMF, Musallam S, Tomlinson RD, et al: Opsoclonus in three dimensions: An oculographic and neuropathologic correlation. In Sharpe JA (ed): *Neuro-ophthalmology at the beginning of the new millennium*. Englewood: Medimond Medical Publications, 2000:87
264. Gresty MA, Findley LJ, Wade P: Mechanism of rotatory eye movements in opsoclonus. *Br J Ophthalmol* 64:923, 1980
265. Hattori T, Takaya Y, Tsuboi Y, et al: Opsoclonus showing only during eye closure in hereditary cerebellar ataxia. *J Neurol Neurosurg Psychiatr* 56:1036, 1993
266. Binyon S, Prendergast M: Eye-movement tics in children. *Dev Med Child Neurol* 33:343, 1991
267. Shawket F, Harris CM, Jacobs M, et al: Eye movement tics. *Br J Ophthalmol* 76:697, 1992
268. Hunter S, Kooistra C: Neuropathologic findings in idiopathic opsoclonus and myoclonus. Their similarity to those in paraneoplastic cerebellar cortical degeneration. *J Clin Neuro Ophthalmol* 6:236, 1986
269. Dehaene I, Van Vleymen B: Opsoclonus induced by phenytoin and diazepam. *Ann Neurol* 21:216, 1987
270. Greenlee JE, Lipton HL: Anticerebellar antibodies in serum and cerebrospinal fluid of a patient with oat cell carcinoma of the lung and paraneoplastic cerebellar degeneration. *Ann Neurol* 19:82, 1986
271. Anderson NE, Corinna CB, Budde-Steffen C: Opsoclonus, myoclonus, ataxia, and encephalopathy in adults with cancer: A distinct paraneoplastic syndrome. *Medicine* 67:100, 1988
272. Herishanu Y, Apte R, Kuperman O: Immunological abnormalities in opsoclonus cerebellopathy. *Neuro Ophthalmol* 5:271, 1985
273. Nitschke M, Hochberg F, Dropcho E: Improvement in paraneoplastic opsoclonus-myoclonus after protein A column therapy. *Nejm* 332:192, 1995
274. Ridley A, Kennard C, Scholtz CL, et al: Omnipause neurons in two cases of opsoclonus associated with oat cell carcinoma of the lung. *Brain* 110:1699, 1987
275. Tuchman RF, Alvarez LA, Kantrowitz AB, et al: Opsoclonus-myoclonus syndrome: Correlation of radiographic and pathological observations. *Neuroradiology* 31:250, 1989
276. Gwinn KA, Caviness JN: Electrophysiological observations in idiopathic opsoclonus-myoclonus syndrome. *Movement Disorders* 12:438, 1997
277. Borodic GE, Miller DC, Bienfang DC: Opsoclonus: Three cases and literature review. In Smith JL, Katz RS (eds): *Neuro-ophthalmology enters the nineties*. Miami: Dutton Press, 1988: 213
278. Caviness JN, Forsyth PA, Layton DD, et al: The movement disorder of adult opsoclonus. *Movement Disorders* 10:22, 1995
279. Nakada T, Kwee IL: Oculopalatal myoclonus. *Brain* 109:431, 1986
280. Deuschl G, Mischke G, Schenck E, et al: Symptomatic and essential rhythmic palatal myoclonus. *Brain* 113:1645, 1990
281. Matsuo F, Ajax ET: Palatal myoclonus and denervation supersensitivity in the central nervous system. *Ann Neurol* 5:72, 1979
282. Koeppen AH, Barron KD, Dentinger MP: Olivary hypertrophy: Histochemical demonstration of hydrolytic enzymes. *Neurology* 30:471, 1980
283. Keane JR: Acute vertical ocular myoclonus. *Neurology* 36:86, 1986
284. Jacobs L, Newman RP, Bozian D: Disappearing palatal myoclonus. *Neurology* 31:748, 1981
285. Carlow TJ: Medical treatment of nystagmus and ocular motor disorders. In Beck RW, Smith CH (eds): *Neuroophthalmology*. Boston: Little Brown, 1986:251
286. Herishanu YO, Zigoulini R: The effect of chronic one-eye patching on ocular myoclonus. *J Clin Neuro Ophthalmol* 11: 166, 1991
287. Jabbari B, Rosenberg M, Scherokman B, et al: Effectiveness of trihexyphenidyl against pendular nystagmus and palatal myoclonus: Evidence of cholinergic dysfunction. *Movement Disorders* 2:93, 1987
288. Neetens A, Martin JJ: Superior oblique myokymia in a case of adrenoleukodystrophy and in a case of lead intoxication. *Neuro Ophthalmol* 3:103, 1983
289. Kommerell G, Schaubele G: Superior oblique myokymia. An electromyographical analysis. *Trans Ophthalmol Soc UK* 100: 504, 1980
290. Morrow MJ, Sharpe JA, Ranalli PJ: Superior oblique myokymia associated with a posterior fossa tumor: Oculographic correlation with an idiopathic case. *Neurology* 40:367, 1990
291. Leigh RJ, Tomsak RL, Seidman SH, et al: Superior oblique myokymia: Quantitative characteristics of the eye movements in three patients. *Arch Ophthalmol* 109:1710, 1991
292. Rosenberg ML, Glaser JS: Superior oblique myokymia. *Ann Neurol* 13:667, 1983
293. Breen LA, Gutmann L, Riggs JE: Superior oblique myokymia. A monomer. *J Clin Neuro Ophthalmol* 3:131, 1983
294. Thurston SE, Saul RF: Superior oblique myokymia: Quantitative description of the eye movement. *Neurology* 41:1679, 1991
295. Komai K, Mimura O, Uyama J, et al: Neuro-ophthalmological evaluation of superior oblique myokymia. *Neuro Ophthalmol* 12:135, 1992
296. Brazis PW, Miller NR, Henderer JD, et al: The natural history and results of treatment of superior oblique myokymia. *Arch Ophthalmol* 112:1063, 1994
297. Rudick R, Satran R, Eskin T: Ocular bobbing in encephalitis. *J Neurol Neurosurg Psychiatr* 44:441, 1981
298. Dehaene I, Lammens M, Marchau M: Paretic ocular bobbing. *Neuro Ophthalmol* 13:143, 1993
299. Gaymard B: Disconjugate ocular bobbing. *Neurology* 43:2151, 1993
300. Brusa A, Firpo MP, Massa S, et al: Typical and reverse bobbing: A case with localizing value. *Eur Neurol* 23:151, 1984
301. Knobler RL, Somasundaram M, Schutta HS: Inverse ocular bobbing. *Ann Neurol* 9:194, 1981
302. Ropper AH: Ocular dipping in anoxic coma. *Arch Neurol* 38: 297, 1981
303. Van Weerden TW, Van Woerkom TCAM: Ocular dipping. *Clin Neurol Neurosurg* 84:221, 1982
304. Stark SR, Masucci EF, Kurtzke JF: Ocular dipping. *Neurology (Cleveland)* 34:391, 1984

- 305. Safran AB, Berney J: Synchronism of inverse ocular bobbing and blinking. *Am J Ophthalmol* 95:401, 1983
- 306. Shults WT, Stark L, Hoyt WF, et al: Normal saccadic structure and voluntary nystagmus. *Arch Ophthalmol* 95:1399, 1977
- 307. Rosenberg ML: Spontaneous vertical eye movements in coma. *Ann Neurol* 20:635, 1986
- 308. Nagle M, Bridgeman B, Stark L: Voluntary nystagmus, saccadic suppression, and stabilization of the visual world. *Vision Res* 20:717, 1980
- 309. Krohel G, Griffin JF: Voluntary vertical nystagmus. *Neurology* 29:1153, 1979
- 310. Yee RD, Spiegel PH, Yamada T, et al: Voluntary saccadic oscillations, resembling ocular flutter and opsoclonus. *J Neuro-Ophthalmol* 14:95, 1994

# Duane's Clinical Ophthalmology

---

## Volume 2

### *Editor*

WILLIAM TASMAN, MD

Ophthalmologist-in-Chief and Co-Director of the Retina Service,  
Wills Eye Hospital; Professor and Chairman, Department of  
Ophthalmology, Jefferson Medical College of Thomas Jefferson  
University, Philadelphia

### *Associate Editor*

EDWARD A. JAEGER, MD

Professor of Ophthalmology, Jefferson Medical College of  
Thomas Jefferson University; Attending Surgeon, Wills Eye  
Hospital, Philadelphia

Revised Edition—2005



LIPPINCOTT WILLIAMS & WILKINS  
PHILADELPHIA • NEW YORK • BALTIMORE