

*Louis F. Dell'Osso\**

## SACCADIC PATHOLOGY AND PLASTICITY

### INTRODUCTION

In order to completely characterize a saccade, its metrics (accuracy), trajectory (peak velocity, duration, over/undershoot, multiple/single and discrete decelerations) and timing (latency) need to be described. This is true for normal as well as pathological saccades and fast phases of nystagmus. In addition, saccadic pathology includes various types of saccadic intrusions and oscillations that affect fixation or normal eye movements.

### TYPES

The saccadic subsystem generates saccades under a variety of conditions. The main purpose of most saccades or fast phases, with the exception of «braking» saccades (Dell'Osso e Daroff, 1976), is to bring the image of a target of interest onto the fovea. This requires both accuracy (since the foveal area is only about 1° in diameter) and speed; the latter is necessary for survival. Overall speed is determined by the latency of the movement and the method by which the ocular motor system generates the saccade (i.e., its trajectory). Inappropriate saccades or those that are incorrectly generated constitute the class of pathological saccades.

\* Ocular Motor Neurophysiology Laboratory, Cleveland, USA.

### *Static (metrics)*

Since all normal saccades are generated by a «pulse-step» of innervation and since the step is responsible for the final position of the eyes after the saccade, the metrics of a saccade depend solely on this latter part of the innervational package. The common neural integrator generates the step of innervation for saccades as well as position signals for pursuit and vestibuloocular movements. In the step is correct, an orthometric (O) saccade is generated. The eye's final position is on target and is independent of the motion (trajectory) of the actual saccade. If the step is too small, the saccade will be hypometric (HO), if too large, hypermetric (HR); again, independent of the trajectories of the saccades (Schmidt et al., 1980).

### *Dynamic (trajectories)*

Trajectories are affected by the burst-cell circuitry and the local neural integrator that determines pulse width. There is strong evidence suggesting that the local and common neural integrators are not the same (i.e., these functions are subserved by different neural networks (Dell'Osso, 1989). In contrast to the metrics of saccades, with only the above three possibilities, there are many ways in which the trajectories of saccades can vary (Schmidt et al., 1980a, b). The peak velocity may be normal (n) or slow (s) for the saccadic amplitude and the pulse may cause the eye to overshoot (o) or undershoot (u) the final eye position. The saccade may contain a dynamic overshoot (do), multiple, closely-spaced saccades (m) or discrete decelerations (d). By combining the metrics (indicated by capital letters) and the trajectories (indicated by small subscripts), each saccade in a refixation can be fully described by this simple recursive scheme. For example, a refixation that consisted of a hypometric saccade with an overshooting trajectory followed by an orthometric corrective saccade with an undershooting trajectory would be labeled, HO<sub>o</sub>O<sub>u</sub>; if the trajectory of the latter was instead three multiple, closely-spaced saccades, the description would be, HO<sub>o</sub>O<sub>3m</sub>.

There are several things that should be remembered when determining the normalcy of saccadic characteristics. First, saccadic amplitude affects trajectory (Abel et al., 1987). Large saccades are more likely to consist of multiple, closely spaced saccades or contain discrete decelerations. Second, age affects some saccadic parameters (Abel et al., 1983). Latency increases with age but velocity and duration do not. Finally, various types of dementia result in latency increases but these increases may not be correlated with the severity of the dementia (Hershey et al., 1983). We found an increased latency preceding a decline in an Alzheimer's patient but not in a Huntington's patient. In contrast, the peak velocities were slow in the Huntington's patient from early in the

course of the disease but were normal in the Alzheimer's patient (Abel et al., 1988).

### *Intrusions*

Saccades that inappropriately interrupt fixation (or pursuit) are called, «saccadic intrusions» (Doslak et al., 1983). They may occur singly or in groups and they may consist either of complete saccades (each generated by a pulse-step of innervation) or partial saccades (each generated by only a pulse).

Those that consist of complete saccades are: saccadic lateropulsion; square-wave jerks (SWJ) and square-wave pulses (SWP). The latter were originally called macro square-wave jerks but that name led to the misinterpretation that they were merely large SWJ (Dell'Osso, 1991). Saccadic intrusions that consist of partial (pulse-only) saccades are: bobbing/dipping; double saccadic pulses (DSP); saccadic pulses (SP); and superior oblique myokymia (SOMY). The dynamic overshoot consists of a no-latency, oppositely directed small saccade following the main pulse of a saccade; dynamic overshoots may occur in normal saccades, especially small ones. Sometimes DSP, SP, SWJ and SWP occur in groups or bursts and look more like oscillations than intrusions; thus, they are included below.

In addition to saccadic intrusions, slow eye movements sometimes interrupt fixation. These may be ramps (r) or exponential runaways (e) or cycles of pendular (p) or triangular (t) oscillations. When part of a refixation, these movements may be combined with the trajectory indicators as subscripts to the metrics descriptor (Schmidt et al., 1980).

### *Oscillations*

When fixation or pursuit is interrupted by repetitive, alternating-direction saccades, they are called, «saccadic oscillations». In the past, some saccadic oscillations were mistaken for nystagmus since they were described without the benefit of eye movement recordings. Nystagmus consists of oscillations that are begun by slow eye movements off target with either slow eye movements or saccades to return the eyes to the intended gaze angle. Saccadic oscillations are due to saccadic movements off target with either saccadic or slow return movements. Where the term «nystagmus» was used incorrectly to describe a saccadic oscillation, it is retained in quotes in recognition of the fact that, despite its name, the oscillation is saccadic. Examples of saccadic oscillations are: convergence-retraction «nystagmus»; [multiple] double saccadic pulses (mDSP); dysmetria; flutter; flutter dysmetria; macro saccadic oscillations (MSO); myoclonus; opsoclonus; psychogenic flutter (voluntary «nystagmus»); saccadic

pulse trains (SPT); square-wave oscillations (SWO); and [bursts] of square-wave pulses (bSWP). Fig. 1 shows illustrations of dysmetria, flutter, flutter dysmetria, MSO, SWJ, SP and DSP.

#### IN INFANCY

Saccadic pathology may manifest itself in infancy and may mask coexisting infantile nystagmus. We studied a case where congenital nystagmus (CN) was masked in a 4<sup>1</sup>/<sub>2</sub> month-old infant by SWJ and SWO (Hertle et al., 1988). Five months later these saccadic intrusions and oscillations were accompanied by CN. Because of the different subsystems involved in the generation of these instabilities, it is unclear why the saccadic instabilities delayed the onset of the CN. It is also quite possible that the CN developed late independently from the saccadic oscillations. No nervous-system abnormalities were found, indicating that infantile saccadic instability may be benign.

#### IN CONGENITAL NYSTAGMUS

CN waveforms exhibit a complexity that reflects the tug-of-war that is going on between the basic instability driving the slowly accelerating eye movements off target and the fixation subsystem that is trying to maintain the image of the target in the foveal area with minimal slip velocity. This produces a variety of idiosyncratic waveforms that can be predominantly pendular, unidirectional jerk or bidirectional jerk (Dell'Osso e Daroff, 1975). Embedded in many of these waveforms are saccades whose direction is always corrective (i.e., they tend to move the eyes in the direction of the target).

#### *Braking Saccades*

One class of saccades found in CN waveforms are called «braking» saccades because they serve only to stop (or brake) the runaway eye movements that constitute CN slow phases (Dell'Osso e Daroff, 1976). These saccades are usually small and may not be recognized in eye-position recordings; eye-velocity recordings are the best way to identify braking saccades. Due to their size, braking saccades do not result in a repositioning of the eyes but do stop the rapid eye movement away from the target and begin a movement towards the target. Such saccades have not been encountered in any other ocular motor disorder or in normals.

### *Foveating Saccades*

A special type of braking saccade is the «foveating» saccade. These saccades not only brake the slow phases of CN but also reposition the eyes to allow the target's image to fall in the foveal area. The fast phases of unidirectional jerk nystagmus are foveating saccades.

### HYPOMETRIA AND HYPERMETRIA

One of the ways the saccadic system can demonstrate abnormality is by failure to accurately reposition the eyes to a target of interest. This static disorder of saccadic gain results in either hypometria or hypermetria. When a saccade is dysmetric, corrective saccades are required; they may also be dysmetric if the dysmetria is severe enough. Hypometria results in a staircase series of saccades to accomplish a refixation whereas hypermetria results in a saccadic oscillation about the target of interest; except for very severe hypermetria, the latter movements are of decreasing amplitude and converge to the target. Hypermetria is seen in cerebellar disease.

### *Myasthenia Gravis and Eaton-Lambert Syndrome*

Although the specific neuromuscular-junction deficits producing myasthenia gravis and the Eaton-Lambert syndrome differ, their effects on the saccadic system are similar (Schmidt et al., 1980a, b; Dell'Osso et al., 1983). Both cause the ocular motor plant to respond with less gain than normal to the pulse-step of innervation required to produce a saccade. The net result is hypometria and trajectory disorders (multiple, closely-spaced saccades). The saccadic velocities in myasthenia gravis appear to be faster than normal whereas in the Eaton-Lambert syndrome they can be slow or normal. The time-varying nature of the neuromuscular deficits gives rise to diverse saccadic responses requiring a descriptive scheme like that described above. The saccades are further distorted by the mixture of the primary deficit with central compensatory adaptation (plasticity). In these, as well as other, slowly developing conditions, measured neurophysiological responses reflect both the deficit and plastic adaptive changes aimed at overcoming the deficit. The use of edrophonium chloride to transiently remove the neuromuscular deficit results in hypermetric saccades and uncovers the plastic changes in the central saccadic gain.

### *Nerve Palsies*

Hypometria is often the result of nerve palsies. In progressive supranuclear palsy, we found hypometria to be common for all saccades greater than 5° (Troost et al., 1976). Also, saccades were slow and fixation was interrupted by SWJ. In a patient with a partial third nerve palsy, we studied the plastic adaptive changes in saccadic gain that were employed to overcome the hypometria (Abel et al., 1978). By alternately patching each eye, we were able to drive the central saccadic gain in both directions. Pulse-width modulation was found to be the method employed in plastic adaptation of saccadic gain.

### *Internuclear Ophthalmoplegia (INO)*

Adduction hypometria is indicative of INO. The yoked abduction saccade is often hypermetric due to plastic changes attempting to raise the saccadic gain of the adducting eye; central gain changes affect both eyes in a given direction. Both the pulse and step of saccadic innervation are under separate plastic control. This can result in trajectory abnormalities due to the gain changes in the pulse (pulse-width) and step (neural-integrator) (Doslak et al., 1980). The resulting saccades will often exhibit post-saccadic drifts, reflecting pulse-step mismatches.

### SACCADIC INTRUSIONS

Table 1 list those saccadic intrusions due to either pulse or pulse-step abnormalities. The following are descriptions of saccadic intrusions and the pathological conditions in which they occur.

### *Bobbing/Dipping*

Bobbing begins with a downward saccadic movement followed by a slow upward return (Fisher, 1964). It usually occurs in comatose patients to have extensive destruction of the pons; extrapontine compressions, obstructive hydrocephalus, and metabolic encephalopathy are occasionally causative. Dipping begins with a slow downward movement followed by an upward saccade; if true, dipping is a form of upbeat nystagmus and not a saccadic oscillation. Occasionally, dipping (inverse bobbing) has been seen in patients who are deeply comatose from metabolic encephalopathy (Knobler et al., 1981; Ropper, 1981). Reverse bobbing begins with an upward saccade followed by a slow downward return and reverse dipping begins with a slow upward movement followed by a downward saccade (Mehler, 1988) (i.e., a form of downbeat nystag-

mus). Bobbing and reverse bobbing is associated with coma but dipping may only require a reduced level of consciousness. Good recordings of bobbing and dipping are lacking and hypotheses regarding their genesis is speculative. Bobbing has been associated with pontine and cerebellar lesions and with metabolic and toxic disturbances.

#### *Double Saccadic Pulses (single)*

Double saccadic pulses are small back-to-back saccades which interrupt fixation, taking the eyes off the target and immediately returning them to the target. The movement is a dynamic overshoot where both saccades are of equal amplitude, producing no net position change. Small double saccadic pulses (minutes of an arc) have been seen in normal fixation and also in certain cases of congenital nystagmus. Although their mechanism is not clear, it is probable that they arise from instability within the circuitry surrounding the burst cells since the common neural integrator used to generate a position signal for saccades is not involved.

#### *Saccadic Lateropulsion*

Saccadic lateropulsion is a dramatic eye movement abnormality associated with lateral veering of body and limb movements. It has been reported in a patient with a left lateral medullary infarction (Kommerell e Hoyt, 1973). All saccades made to the left by this patient were hypermetric while those to the right were hypometric. Even vertical saccades veered to the left along an oblique rather than the vertical path. Lateropulsion was initially described in the same direction as the side of the lesion (ipsipulsion); contrapulsion was described in a case of a unilateral disorder of the rostral cerebellum (Ranalli e Sharpe, 1986). Contralateral saccades were hypermetric and ipsilateral saccades, hypometric.

Both lateropulsion and upbeat nystagmus have been cited as manifestations of central vestibular dysfunction (Benjamin et al., 1986) due to a right hemispheric cerebellar infarction. The lateropulsion was contralateral to the side of the lesion. Two cases with leftward saccadic pulsion during vertical saccades were found: a patient with Wallenberg's syndrome exhibited lateropulsion whereas the patient with the proximal type of the superior cerebellar syndrome had contrapulsion (Uno et al., 1989).

### *Saccadic Pulses*

A saccadic pulse consists of the pulse portion of a saccade and then the eyes drift exponentially back to their original position (a stepless saccade). Thus, the common neural integrator does not provide a step of innervation to hold the new eye position. This suggests a spurious defect within the burst-cell circuitry. Saccadic pulses occur in normal fixation.

### *Square-Wave Jerks*

A square-wave jerk consists of two saccades in opposite directions separated by the normal intersaccadic interval (200 msec). The deficit responsible for SWJ is probably before the burst-cell circuitry since both a pulse and step are generated to produce the first saccade in the pair making up the SWJ; the second saccade is merely corrective. The deficit probably also affects the signal for desired eye position since the corrective saccade of the pair is not generated until 200 msec later. SWJ intrusions may occur in normals (especially upon closure of the eyelids) or may represent pathology suggestive of cerebellar disease. They have been recorded in Huntington's disease, progressive supranuclear palsy and Balint's syndrome. If SWJ interrupt fixation, they will also interrupt pursuit; they should not be considered a deficit in the pursuit system.

Ohtsuka et al. (1986) studied the origin of SWJ under conditions of fixation of targets of variable size. The size of SWJ was found to be directly related to the size of the target; the frequency and duration of SWJ remained constant and was independent of target size. SWJ within the range of microsaccades disappeared as larger SWJ appeared. The authors concluded that SWJ were enlarged versions of microsaccadic SWJ that appear when viewing very small targets. The authors agreed with Doslak et al. (1983) and concluded that the saccadic intrusion (i.e., the first saccade of a SWJ) is caused by a spurious error signal that takes the eye off the target creating a real error that is corrected by the return saccade after a normal latency. Even in the dark, the eye position after an SWJ equaled the mean eye position before the SWJ. Thus, SWJ occur normally but are usually of microsaccadic amplitudes. The instability of eye position in the dark in patients with cerebellar degeneration was found to differ from that of normals (Ohtsuka et al., 1988). In addition to SWJ, unidirectional drifts and corrective saccades were observed. Patients with spino-cerebellar degeneration showed unsteadiness in non-visual eye position control. In normal subjects, both in light and in darkness, saccadic intrusions provoked position error signals and corrective saccades were elicited producing SWJ. However, in patients with moderate and marked instability, the saccadic intrusions did not elicit corrective saccades and SWJ were not observed. The authors concluded that a position error signal was not provoked in these patients in the dark. They



further hypothesized that proprioceptive afferent information from eye muscles contributes to controlling eye position in the dark through the cerebellum.

Shallo-Hoffmann et al. (1989) studied the occurrence of SWJ in normals under different conditions. They concluded that SWJ were normal with the eyes closed, in darkness while looking straight ahead and while fixating a target in a lighted room. More than 16 SWJ/min while fixating or 20/min under the other conditions should be considered abnormal according to these authors. A difference between this and a previous report [Herishanu e Sharpe, 1981] in the number of SWJ occurring in darkness was attributed to the specific instruction, «hold the eyes still» given in the other study. In a related study, Shallo-Hoffman et al. [1990] reported the characteristics of SWJ over a broad age range. Their results showed no relationship between SWJ frequency and age.

#### *Superior Oblique Myokymia (SOMY)*

SOMY is a small-amplitude, uniocular, intermittent, torsional eye movement which evokes oscillopsia and appears spontaneously in otherwise healthy adults. It reflects phasic contraction of the superior oblique muscle and may be detected during ophthalmoscopy or by the use of the slit lamp. SOMY sometimes responds to the administration of the anticonvulsant drug, carbamazepine.

Morrow et al. (1990), recorded SOMY in an idiopathic patient and one with an astrocytoma involving the midbrain tectum. Monocular bursts of tonic and phasic intorsion and depression and miniature oscillations were found. In both patients, the torsional and vertical movements were synchronous with similar waveforms but the torsional movements were about twice as large as the vertical. The waveforms of SOMY consisted of either a slow sustained tonic intorsion and depression or a phasic intorsion; each was followed by a decreasing velocity return. Occasionally there were small torsional-vertical oscillations superimposed on the tonic deviations. The tonic amplitudes were 2-3° of intorsion and 1-1.5° of depression. The phasic amplitudes were 0.5-1° and the small oscillations were less than 0.5° at up to 20 Hz. Thus, in the torsional plane, SOMY consists of either an intorsional saccade followed after some time by a decreasing velocity return (tonic) or an intorsional saccadic pulse (phasic). In addition, bursts of small pendular oscillations can be superimposed on the tonic intorsions. These movements are also seen in the vertical plane. The symptoms stopped in the second patient after tumor resection.

We studied three patients with SOMY by simultaneously measuring the horizontal, vertical and torsional movements of both eyes (Leigh et al., 1991). A spectral analysis of the fine oscillation revealed frequencies up to 50 Hz with peaks at 5.6 and 1.5 Hz (in two patients) corresponding to a component resembling jerk nystagmus. Although the vertical and torsional amplitudes were less than 1°, the velocities frequently exceeded 4°/sec.

Table 1. SACCADIC INTRUSIONS

<i>Pulse</i>	<i>Pulse-Step</i>
Bobbing/Dipping	Saccadic Lateropulsion
Double Saccadic Pulses	Square-Wave Jerks
Saccadic Pulses	Square-Wave Pulses <MSWJ>
Superior Oblique Myokymia	
Dynamic overshoots	

Table 2. SACCADIC OSCILLATIONS

Convergence-Retraction «nystagmus»  
multiple Double Saccadic Pulses  
Dysmetria  
Flutter  
Flutter-Dysmetria  
Macro Saccadic Oscillations  
Myoclonus  
Opsoclonus  
Psychogenic Flutter  
Saccadic Pulse Trains  
Square-Wave Oscillations

#### SACCADIC OSCILLATIONS

Table 2 is a list of saccadic oscillations. Saccadic oscillations and their associated pathological conditions are described below.

#### *Double Saccadic Pulses (multiple)*

Runs of double saccadic pulses appear as an instability of fixation. They have been reported, along with numerous other saccadic instabilities, in a case of presumed multiple sclerosis (Doslak et al., 1983).

### *Flutter and Flutter Dysmetria*

Bursts of back-to-back saccades without intersaccadic latency appear as high-frequency sinusoidal oscillations. They may occur spontaneously (flutter) or at the end of saccades (flutter dysmetria). Flutter and opsoclonus represent a continuum of ocular motor instability; patients often pass through phases of flutter when recovering from opsoclonus (the opsoclonus may re-emerge with upward gaze).

An unusual case of blink-induced flutter in a patient with multiple sclerosis was reported (Herishanu et al., 1987). The flutter was present whenever the patient blinked or attempted to blink while her lids were held open; no spontaneous saccadic intrusions or oscillations were observed during fixation. Furman et al. (1988) reported spontaneous remission of ocular flutter and other saccadic intrusions and oscillations in two women. Since their remission preceded the appearance of a primary neoplastic process remote from the nervous system, the authors warned that such remission does not necessarily imply a benign outcome. Bergenius (1986) studied the saccadic abnormalities in patients that exhibited ocular flutter. He found opsoclonus, increased frequency of SWJ, high peak velocity of voluntary saccades and hypermetria. Salonen et al. (1988) reported a case of sarcoidosis where flutter was the only neurological sign. The flutter disappeared in two months and the authors suggested that neurosarcoidosis should be considered as a potential cause.

Hotson (1984) investigated the proposal that voluntary flutter is an inherent capability in humans. He found no difference in saccadic peak velocity between control subjects and those capable of voluntary flutter. With training, control subjects were able to learn to produce runs of voluntary flutter. This learned flutter was composed of recurrent complete saccades rather than saccades interrupted in mid flight. He concluded that voluntary flutter is not a genetic trait but a learned event that is usually undeveloped in man.

Low-amplitude flutter has been described in two cases and given the designation, «microflutter» [Carlow, 1986; Sharpe e Fletcher, 1986]. In one, cerebellar degeneration was the diagnosis. Ashe et al. (1991) studied five cases with microflutter and hypothesized that microflutter was not merely a case of low-amplitude flutter but a mechanistically different oscillation. It is premature to conclude that the mechanism for microflutter is significantly different from that of flutter. The former may merely be the precursor of the latter or reflect a smaller disruption to that area of the brain stem.

Flutter dysmetria may be associated with dysmetria or it may appear after an orthometric saccade; it is a disturbance of saccadic trajectory, not metrics. As with flutter and ocular dysmetria, flutter dysmetria is seen in patients with cerebellar disease.

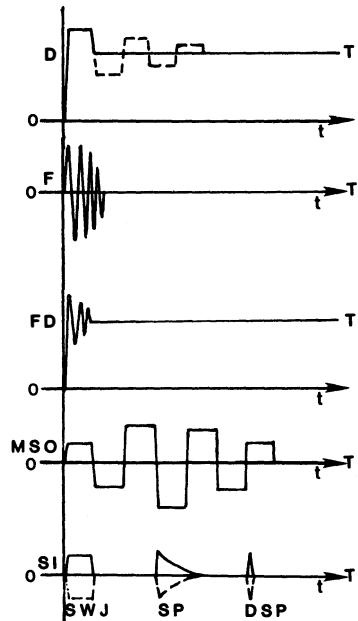


Fig. 1. Schematic illustrations of dysmetria (D), flutter (F), flutter dysmetria (FD), macro saccadic oscillations (MSO) and the saccadic intrusions (SI): square-wave jerks (SWJ), saccadic pulses (SP) and double saccadic pulses (DSP). T-target, O-primary position and t-time. Reprinted with permission from Doslak et al., 1982.

### *Macro Saccadic Oscillations (MSO)*

MSO consist of alternate-direction saccades separated by a normal inter-saccadic latency (200 msec) that straddle the intended fixation angle; their amplitudes gradually increase and then decrease. MSO have been modeled as an instability of the saccadic control loop including the visual feedback pathway [Selhorst et al., 1976]. MSO are associated with cerebellar disease, multiple sclerosis and metabolic encephalopathy.

### *Opsoclonus (OPSO)*

OPSO was first described in 1913 (Orzechowski et al.) and again in 1927 (Orzechowski). OPSO (saccadomania) consists of rapid, involuntary, chaotic, repetitive, unpredictable, conjugate saccadic eye movements in all directions which prevent fixation and persist during sleep. The terms «dancing eyes» and «lightning eye movements» have been used to describe the eye movements of patients with opsoclonus.

Adding to the many substances that have been reported to induce OPSO, Dehaene and Van Vleymen (1987) presented a case in which phenytoin and diazepam caused OPSO. Hunter and Kooistra (1986) discussed the neuropathology of OPSO.

thologic findings in a case of OPSO. They found structural lesions limited to the cerebellum and inferior olives and severe depletion of Purkinje cells with preservation of granular cells in the neo- and paleocerebellum. Purkinje cells were preserved in the archicerebellum. No abnormalities were found in the paramedian pontine reticular formation of the caudal pons. In a case of OPSO associated with adenocarcinoma of the breast, steroid treatment was successful (Herishanu et al., 1985). Ridley et al. (1987) looked at omnipause neurons in two cases of OPSO associated with oat cell carcinoma of the lung. The light-microscopic appearance of these neurons were normal. The authors concluded that, although the cells appeared normal, it is still possible that their function was disturbed and OPSO resulted. Borodic et al. (1988) have extensively reviewed the literature of 19 autopsied cases of OPSO.

In addition to the many disorders that have since been associated with OPSO, organophosphate poisoning (Pullicino e Aquilina, 1989) thymic carcinoma (Schwartz et al., 1990), Epstein-Barr virus infection (Delreux et al., 1989), hyperosmolar stupor (Weissman et al., 1989) and hypertension (Tychsens et al., 1990; Wolpow et al., 1988) have been added. Also, a case of opsoclonus-myoclonus («dancing eyes, dancing feet») was reported secondary to cocaine usage (Scharf, 1989). The episode was self-limiting over four weeks and had not reappeared after one year.

### *Psychogenic Flutter*

Flutter that can be produced at will or is the result of psychological factors, is termed «psychogenic flutter»; «voluntary 'nystagmus'» or «psychological/hysterical 'nystagmus'» are some of the other terms commonly used for this type of flutter.

It has been clearly shown (Zee et al., 1981) that these were not nystagmus at all but a series of back-to-back saccades, interrupting fixation, whose timing is such that the waveform traced out appears to be pendular. Psychogenic flutter is typically 8-23 Hz. It is a horizontal conjugate oscillation and each burst usually has a duration of less than 30 seconds.

### *Saccadic Pulse Trains (SPT)*

When saccadic pulses occur in bursts, or continuously, they are called saccadic pulse trains. Since it consists of alternating fast and slow phases, it is often confused with nystagmus. This has given rise to the misnomer, «nystagmus of internuclear ophthalmoplegia» or «abduction nystagmus». SPT are probably due to instability of the burst-cell circuitry that does not affect the common neural integrator. They have been seen in multiple sclerosis.

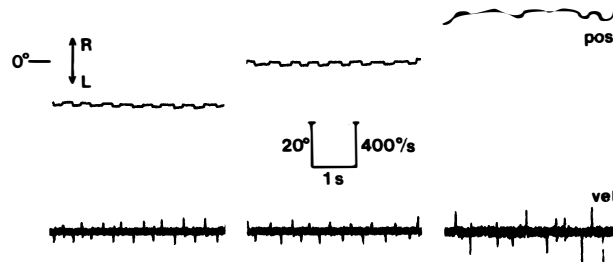


Fig. 2. Square-wave oscillations (SWO) seen in primary position and at  $\pm 20^\circ$ . Note the regularity of the eye movements seen at  $0^\circ$  and  $-20^\circ$ . Reprinted with permission from Abel et al., 1983.

Abduction «nystagmus» is the dissociated oscillation of the abducting eye seen in patients with internuclear ophthalmoplegia (INO) (Cogan, 1970). The clinical picture presented by the patient with a total INO is that of an acquired jerk «nystagmus» of the abducting eye (with abducting fast phases) while the fellow eye remains motionless in primary position. If the INO is bilateral, abduction «nystagmus» will be present in both extremes of gaze, always in the abducting eye only. Abduction «nystagmus» has also been called «ataxic» nystagmus of Harris. Careful recordings, using high bandwidth methods and simultaneous velocity tracings, have shown that the slow phases are decreasing-velocity exponentials and the fast phases of the abducting eye are always accompanied by hypometric saccades in the adducting eye. In fact, if the gaze angle is such that the adducting eye eventually reaches the target, both the oscillation and hypometric adduction saccades will cease. It is only in the full-blown INO, where the adducting eye does not adduct beyond midline, that abduction «nystagmus» persists. Since the abducting saccadic pulses are truly the cause of this oscillation, abduction «nystagmus» is actually a SPT.

We hypothesized that the fast phases of so-called abduction «nystagmus» of INO were really saccadic pulses present in the abducting eye as a result of the weakness in the adducting eye (Dell'Osso e Daroff, 1981). Additional evidence in support of that hypothesis followed (Zee et al., 1987). Four patients with INO had one eye patched 1 to 5 days to allow time for the nervous system to optimize innervation for the habitually viewing eye. The conjugate adjustment of innervation diminished the abduction overshoot and backward post-saccadic drift made by the habitually viewing eye. The authors concluded that abduction «nystagmus» is a manifestation of a normal adaptive response in patients with INO.

Gamlin et al. (1989) studied the effects (in rhesus monkeys) on conver-

gence and conjugate eye movements of lidocaine-induced unilateral INO. The relevant findings were: 1) uniocular vertical nystagmus with unyoked fast phases inferred independent operation of the individual saccade generators and 2) abduction «nystagmus» was actually caused by adaptive saccadic behavior. This latter finding is yet another supporting the classification of this sign as a saccadic oscillation.

#### *Square-Wave Oscillations (SWO)*

SWO are continuous square-wave jerks [Abel et al., 1984]. They take the eyes off and back to the target in either or both directions. Fig. 2 shows SWO in a patient with progressive supranuclear palsy. As for single SWJ, the site of instability is probably before the burst-cell circuitry and affects the desired eye position signal. The occurrence of both SWJ and SWO has been documented in two patients with acquired immunodeficiency syndrome (Friedman e Feldon, 1989). The SWO had a frequency of up to 5 Hz. SWO have also been seen in progressive supranuclear palsy, Parkinson's disease, basal ganglia infarct and spinocerebellar degeneration.

#### *Square-Wave Pulses SWO (bursts) «Macro Square-Wave Jerks»*

As with SWO, bursts of SWP also take the eyes off and back to the target but they have lower intersaccadic intervals and usually higher amplitudes. Fig. 3 shows SWP (then referred to as MSWJ) in a patient with multiple sclerosis. The intersaccadic interval between the return saccade and the next intruding saccade is normal (200 msec). SWP have been seen in multiple sclerosis and cerebellar degeneration and atrophy.

#### SPECIAL CASE

There is an oscillation that combines slow and fast eye movement instabilities in different planes; it gives rise to a scan path (horizontal vs. vertical position plot) that resembles a bow-tie.

#### *Bow-Tie Nystagmus*

Bow-tie nystagmus was first described as the eye-movement condition brought about by smoking tobacco (Sibony et al., 1987). It consisted of a saccadic horizontal oscillation combined with a vertical upbeat nystagmus. The horizontal saccades and fast phases of the upbeat nystagmus were synchronized,

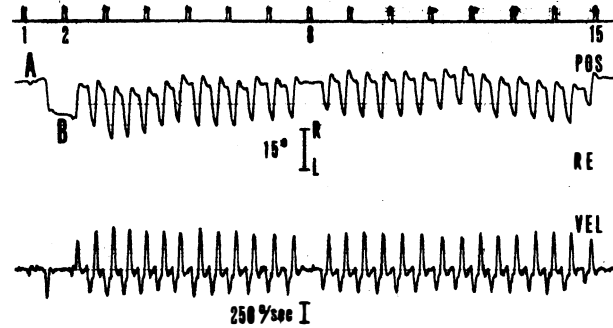


Fig. 3. Monocular recording of the right eye (RE) showing initiation of square-wave pulses (SWP) after a voluntary saccade to the right. The voluntary saccade to the left from A to B (after timing mark 1) was uneventful but the rightward saccade back to A (after timing mark 2) resulted in a burst of SWP (bSWP), a pause on target A at timing mark 8, and another bSWP that ended at timing mark 15. The timing marks indicate 1 second intervals. Reprinted with permission (and corrected legend) from Dell'Osso et al., *Neurology* 25: 975-979, 1975.

producing upward diagonal fast phases in alternating horizontal directions and downward slow phases. Nicotine was isolated as the responsible element (Sibony et al., 1990). Recently, we described a case of torsional, see-saw, bow-tie nystagmus associated with brain stem abnormalities (Weissman et al., 1990). Here, a conjugate, clockwise jerk torsional nystagmus was superimposed on an upbeat, bow-tie nystagmus in the left eye and a downbeat, bow-tie nystagmus in the right eye. Central vestibular connection disturbance was the postulated cause.

#### REFERENCES

- Abel L.A., Traccis S., Troost B.T., Dell'Osso L.F.: Saccadic trajectories change with amplitude, not time. *Neuro-ophthalmol.* 7: 309-314, 1987.
- Abel L.A., Troost B.T., Dell'Osso L.F.: The effects of age on normal saccadic characteristics and their variability. *Vision Res.* 28: 33-37, 1983.
- Abel L.A., Dell'Osso L.F., Rusted L.C.: Longitudinal saccadic changes in Huntington's disease and Alzheimer's disease. *Neuro-ophthalmol.* 8: 307-315, 1988.
- Abel L.A., Schmidt D., Dell'Osso L.F., Daroff R.B.: Saccadic system plasticity in humans. *Ann. Neurol.* 4: 313-318, 1978.
- Abel L.A., Traccis S., Dell'Osso L.F., Daroff R.B., Troost B.T.: Square wave oscillation. The relationship of saccadic intrusions and oscillations. *Neuro-ophthalmol.* 4: 21-25, 1984.
- Ashe J., Hain T.C., Zee D.S., Schatz N.J.: Microsaccadic flutter. *Brain* 114: 461-472, 1991.



- Benjamin E.E., Zimmerman C.F., Troost B.T.: Lateropulsion and upbeat nystagmus are manifestations of central vestibular dysfunction. *Arch. Neurol.* 43: 962-964, 1986.
- Bergenius J.: Saccade abnormalities in patients with ocular flutter. *Acta Otolaryngol. (Stockh.)* 102: 228-233, 1986.
- Borodic G.E., Miller D.C., Bienfang D.C.: Opsoclonus: three cases and literature review. In: *Neuro-Ophthalmology Enters the Nineties*. Smith J.L., Katz R. S. (eds.), Miami: Dutton Press pp. 213-232, 1988.
- Carlow T.J.: Medical treatment of nystagmus and other ocular motor disorders. *Int. Ophthalmol. Clin.* 26: 251-263, 1986.
- Cogan D.G.: Internuclear ophthalmoplegia, typical and atypical. *Arch. Ophthalmol.* 84: 583-589, 1970.
- Dehaene I., Van Vleymen B.: Opsoclonus induced by phenytoin and diazepam. *Ann. Neurol.* 21: 216, 1987.
- Dell'Osso L.F., Daroff R.B.: Braking saccade — A new fast eye movement. *Aviat Space Environ Med.* 47: 435-437, 1976.
- Dell'Osso L.F.: Neural integration in ocular motility. *Bull. Soc. belge Ophthalmol.* 237: 19-33, 1989.
- Dell'Osso L.F.: Nystagmus, saccadic intrusions/oscillations and oscillopsia. In: *Current Neuro-Ophthalmology, Vol. 3*. Lessell S., Van Dalen J. T. W. (eds.), Chicago: Year Book Medical Publishers pp. 153-191, 1991.
- Dell'Osso L.F., Daroff R.B.: Congenital nystagmus waveforms and foveation strategy. *Doc. Ophthalmol.* 39: 155-182, 1975.
- Dell'Osso L.F., Ayyar D. R., Daroff R.B., Abel L.A.: Edrophonium test in Eaton-Lambert syndrome: Quantitative oculography. *Neurology* 33: 1157-1163, 1983.
- Dell'Osso L.F., Daroff R.B.: Clinical disorders of ocular movement. In: *Models of Oculomotor Behavior and Control*. Zuber B. L. (ed.), West Palm Beach: CRC Press Inc. pp. 233-256, 1981.
- Delreux V., Kevers L., Callewaert A., Sindic C.: Opsoclonus secondary to an Epstein-Barr virus infection. *Arch. Neurol.* 46: 480-481, 1989.
- Doslak M.J., Dell'Osso L.F., Daroff R.B.: Multiple double saccadic pulses occurring with other saccadic intrusions and oscillations. *Neuro-ophthalmology* 3: 109-116, 1983.
- Doslak M.J., Kline L.B., Dell'Osso L.F., Daroff R.B.: Internuclear ophthalmoplegia: Recovery and plasticity. *Invest. Ophthalmol.* 19: 1506-1511, 1980.
- Fisher C.M.: Ocular bobbing. *Arch. Neurol.* 11: 543, 1964.
- Friedman D.I., Feldon S.E.: Eye movements in acquired immunodeficiency syndrome. *Arch. Neurol.* 46: 841, 1989.
- Furman J.M.R., Eidelman B.H., Fromm G.H.: Spontaneous remission of paraneoplastic ocular flutter and saccadic intrusions. *Neurology* 38: 499-501, 1988.
- Gamlin P.D.R., Gnadt J.W., Mays L.E.: Lidocaine-induced unilateral internuclear ophthalmoplegia: effects on convergence and conjugate eye movements. *J. Neurophysiol.* 62: 82-95, 1989.
- Herishanu Y.O., Sharpe J.A.: Normal square wave jerks. *Invest Ophthalmol. Vis. Sci.* 20: 268-272, 1981.
- Herishanu Y., Abarbanel J.M., Frisher S.: Blink induced ocular flutter. *Neuro-ophthalmol.* 7: 175-177, 197.
- Herishanu Y., Apte R., Kuperman O.: Immunological abnormalities in opsoclonus cerebellopathy. *Neuro-ophthalmol.* 5: 271-276, 1985.

- Hershey L.A., Whicker Jr. L., Abel L.A., Dell'Osso L.F., Traccis S., Grossniklaus D.: Saccadic latency measurements in dementia. *Arch. Neurol.* 40: 592-593, 1983.
- Hertle R.W., Tabuchi A., Dell'Osso L.F., Abel L.A., Weissman B.M.: Saccadic oscillations and intrusions preceding the postnatal appearance of congenital nystagmus. *Neuro-ophthalmol.* 8: 37-42, 1988.
- Hotson J.R.: Convergence-initiated voluntary flutter: a normal intrinsic capability in man. *Brain Res.* 294: 299-304, 1984.
- Hunter S., Kooistra C.: Neuropathologic findings in idiopathic opsoclonus and myoclonus. Their similarity to those in paraneoplastic cerebellar cortical degeneration. *J. Clin. Neuro-ophthalmol.* 6: 236-241, 1986.
- Knobler R.L., Somasundaram M., Schutta H.S.: Inverse ocular bobbing. *Ann. Neurol.* 9: 194-197, 1981.
- Kommerell G., Hoyt W.F.: Lateropulsion of saccadic eye movements. *Arch. Neurol.* 28: 313-318, 1973.
- Leigh R.J., Tomsak R.L., Seidman S.H., Dell'Osso L.F.: Superior oblique myokymia: quantitative characteristics of the eye movements in three patients. *Arch. Ophthalmol.* 109: 1710-1713, 1991.
- Mehler M.F.: The clinical spectrum of ocular bobbing and ocular dipping. *J. Neurol. Neurosurg. Psychiat.* 51: 725-727, 1988.
- Morrow M.J., Sharpe J.A., Ranalli P.J.: Superior oblique myokymia associated with a posterior fossa tumor: oculographic correlation with an idiopathic case. *Neurology* 40: 367-370, 1990.
- Ohtsuka K., Mukuno K., Ukai K., Ishikawa S.: The origin of square wave jerks: conditions of fixation and microsaccades. *Jpn. J. Ophthalmol.* 30: 209-215, 1986.
- Ohtsuka K., Mukuno K., Sakai H., Ishikawa S.: Instability of eye position in the dark in cerebellar degeneration. *Ophthalmologica* 196: 35-39, 1988.
- Orzechowski K., Walichewicz T.: Przypadek operowanej torbieli sródpajeczy mózdzka (operated cyst of the cerebellum). *Lwowski Tygodnik Lekarski* 18: 219-227, 1913.
- Orzechowski K.: De l'ataxie dysmetrique des yeux: remarques sur l'ataxie des yeux dite myoclonique (opsoclonie, opsochorie). *J. Psych. Neurol.* 35: 1-18, 1927.
- Pullicino P., Aquilina J.: Opsoclonus in organophosphate poisoning. *Arch. Neurol.* 46: 704-705, 1989.
- Ranalli P.J., Sharpe J.A.: Contrapulsion of saccades and ipsilateral ataxia: a unilateral disorder of the rostral cerebellum. *Ann. Neurol.* 20: 311-316, 1986.
- Ridley A., Kennard C., Scholtz C.L., Büttner-Ennever J.A., Summers B., Turnbull A.: Omnipause neurons in two cases of opsoclonus associated with oat cell carcinoma of the lung. *Brain* 110: 1699-1709, 1987.
- Ropper A.H.: Ocular dipping in anoxic coma. *Arch. Neurol.* 38: 297-299, 1981.
- Salonen R., Nikoskelainen E., Aantaa E., Marttila R.: Ocular flutter associated with sarcoidosis. *Neuro-ophthalmol.* 8: 77-79, 1988.
- Scharf D.: Opsoclonus-myoclonus following the intranasal usage of cocaine. *J. Neurol. Neurosurg. Psychiat.* 52: 1447-1448, 199.
- Schmidt D., Dell'Osso L.F., Abel L.A., Daroff R.B.: Myasthenia gravis: Saccadic eye movement waveforms. *Exp. Neurol.* 68: 346-364, 1980a.
- Schmidt D., Dell'Osso L.F., Abel L.A., Daroff R.B.: Myasthenia gravis: Dynamic changes in saccadic waveform, gain and velocity. *Exp. Neurol.* 68: 365-377, 1980b.
- Schwartz M., Sharf B., Zidan J.: Opsoclonus as a presenting symptom in thymic carcinoma. *J. Neurol. Neurosurg. Psychiat.* 53: 534, 1990.

- Selhorst J.B., Stark L., Ochs A.L., Hoyt W.F.: Disorders in cerebellar ocular motor control. II. Macro saccadic oscillation: an oculographic, control system and clinico-anatomical analysis. *Brain* 99: 509-522, 1976.
- Shallo-Hoffmann J., Petersen J., Mühlendych H.: How normal are «normal» square wave jerks? *Invest Ophthalmol. Vis. Sci.* 30: 1009-1011, 1989.
- Shallo-Hoffmann J., Sendler B., Mühlendych H.: Normal square wave jerks in differing age groups. *Invest. Ophthalmol. Vis. Sci.* 31: 1649-1652, 1990.
- Sharpe J.A., Fletcher W.A.: Disorders of visual fixation. In: *Neuro-ophthalmology Now*. Smith J. L. (ed.), Chicago: Yearbook pp. 267-284, 1986.
- Sibony P.A., Evinger C., Manning K.A.: Tobacco-induced primary-position upbeat nystagmus. *Ann. Neurol.* 21: 53-58, 1987.
- Sibony P.A., Evinger C., Manning K., Pellegrini J.J.: Nicotine and tobacco-induced nystagmus. *Ann. Neurol.* 28: 198, 1990.
- Tychsen L., Engelken E.J., Austin E.J.: Periodic saccadic oscillations and tinnitus. *Neurology* 40: 549-551, 1990.
- Troost B.T., Daroff R.B., Dell'Osso L.F.: Quantitative analysis of the ocular motor deficit in progressive supranuclear palsy (PSP). *Trans. Am. Neurol. Assoc.* 101: 60-64, 1976.
- Uno A., Mukuno K., Sekiya H., Ishikawa S., Suzuki S., Hata T.: Lateropulsion in Wallenberg's syndrome and contrapulsion in the proximal type of the superior cerebellar artery syndrome. *Neuro-ophthalmol.* 9: 75-80, 1989.
- Weissman B.M., Devereaux M., Chandar K.: Opsoclonus and hyperosmolar stupor. *Neurology* 39: 1401-1402, 1989.
- Weissman J.D., Seidman S.H., Dell'Osso L.F., Naheedy M.H., Leigh R.J.: Torsional, see-saw, «bow-tie» nystagmus in association with brain stem anomalies. *Neuro-ophthalmol.* 10: 315-318, 1990.
- Wolpow E.R., Davis K.R., Kamitsuka P.F., Koerner F.C., Wray S.H.: Case records of the Massachusetts General Hospital. Case 9-1988. *New Eng. J. Med.* 318: 563-570, 1988.
- Zee D.S., Yamzaki A., Butler P.H., Gücer G.: Effects of ablation of flocculus and paraflocculus on eye movements in primate. *J. Neurophysiol.* 46: 878-899, 1981.
- Zee D.S., Hain T.C., Carl J.R.: Abduction nystagmus in internuclear ophthalmoplegia. *Ann Neurol.* 21: 383-388, 1987.

# I MOVIMENTI SACCADICI

A cura di  
Sebastiano Traccis e Daniela Zambarbieri

PÀTRON EDITORE  
BOLOGNA 1992