

Combining recessions (nystagmus and strabismus) with tenotomy improved visual function and decreased oscillopsia and diplopia in acquired downbeat nystagmus and in horizontal infantile nystagmus syndrome

Zhong I. Wang, MS,^{a,c} Louis F. Dell'Osso, PhD,^{a,b,c} Robert L. Tomsak, MD, PhD,^{a,b} and Jonathan B. Jacobs, PhD^{a,b}

PURPOSE	To investigate the effects of combined tenotomy and recession procedures on both acquired downbeat nystagmus and horizontal infantile nystagmus.
METHODS	Patient 1 had downbeat nystagmus with a chin-down (upgaze) position, oscillopsia, strabismus, and diplopia. Asymmetric superior rectus recessions and inferior rectus tenotomies reduced right hypertropia and rotated both eyes downward. Patient 2 had horizontal infantile nystagmus, a 20° left-eye exotropia, and alternating (<i>abducting-eye</i>) fixation. Lateral rectus recessions and medial rectus tenotomies were performed. Horizontal and vertical eye movements were recorded pre- and postsurgically using high-speed digital video. The eXpanded Nystagmus Acuity Function (NAFX) and nystagmus amplitudes and frequencies were measured.
RESULTS	Patient 1: The NAFX peak moved from 10° up to primary position where NAFX values improved 17% and visual acuity increased 25%. Vertical NAFX increased across the -10° to +5° vertical range. Primary-position right hypertropia decreased ~50%; foveation time per cycle increased 102%; vertical amplitude, oscillopsia, and diplopia were reduced, and frequency was unchanged. Patient 2: Two lateral, narrow high-NAFX regions (due to alternating fixation) became one broad region with a 43% increase in primary position (acuity increased ~92.3%). Diplopia amplitude decreased; convergence and gaze holding were improved. Primary-position right exotropia was reduced; foveation time per cycle increased 257%; horizontal-component amplitude decreased 45.7%, and frequency remained unchanged.
CONCLUSIONS	Combining tenotomy with nystagmus or strabismus recession procedures increased NAFX and visual acuities and reduced diplopia and oscillopsia in downbeat nystagmus and infantile nystagmus. (J AAPOS 2007;11:135-141)



Previous investigations have demonstrated the efficacy of recessions,¹ resections,² or both (Anderson-Kestenbaum)³ to treat infantile nystagmus. More recently, four-muscle tenotomy was shown to both im-

prove nystagmus waveforms and broaden the range of gaze angles with improved waveforms.⁴⁻⁷ It was also reported to be effective in reducing acquired pendular nystagmus and oscillopsia in a patient with multiple sclerosis.⁸

Surgical treatment of nystagmus should be tailored to the eye-movement and clinical characteristics of each individual patient. In this study, we investigated surgical treatments with recessions combined with tenotomy. We chose two patients with both different types of nystagmus and clinical characteristics. In one patient, tenotomy was combined with bilateral inferior rectus recessions (a vertical Anderson nystagmus procedure) to improve acquired downbeat nystagmus, plus a small unilateral inferior rectus recession (a strabismus procedure) to improve a vertical tropia. In the other, it was combined with bilateral lateral rectus recessions (a strabismus procedure) to improve horizontal infantile nystagmus. The nystagmus caused oscillopsia in the downbeat nystagmus patient and reduced visual acuity in both. The postsurgical changes of different aspects of the nystagmus, tenotomy's broadening effect in

Author affiliations: ^aDaroff-Dell'Osso Ocular Motility Laboratory, Louis Stokes Cleveland Department of Veterans Affairs Medical Center and CASE Medical School; and the ^bDepartment of Neurology and ^cDepartment of Biomedical Engineering, Case Western Reserve University and University Hospitals of Cleveland, Cleveland, Ohio

This work was supported in part by the Office of Research and Development, Medical Research Service, Department of Veterans Affairs.

Presented in part at the 2006 North American Neuro-Ophthalmology Society, Association for Research in Vision and Ophthalmology, and World Multi-Conference on Systemics, Cybernetics, and Informatics meetings.

Submitted August 1, 2006.

Revision accepted October 23, 2006.

Published online February 6, 2007.

Reprint requests: L. F. Dell'Osso, PhD, Daroff-Dell'Osso Ocular Motility Laboratory, Louis Stokes Cleveland Veterans Affairs Medical Center, 10701 East Boulevard, Cleveland, OH 44106 (email: lfd@case.edu).

Copyright © 2007 by the American Association for Pediatric Ophthalmology and Strabismus.

1091-8531/2007/\$35.00 + 0

doi:10.1016/j.jaapos.2006.10.012

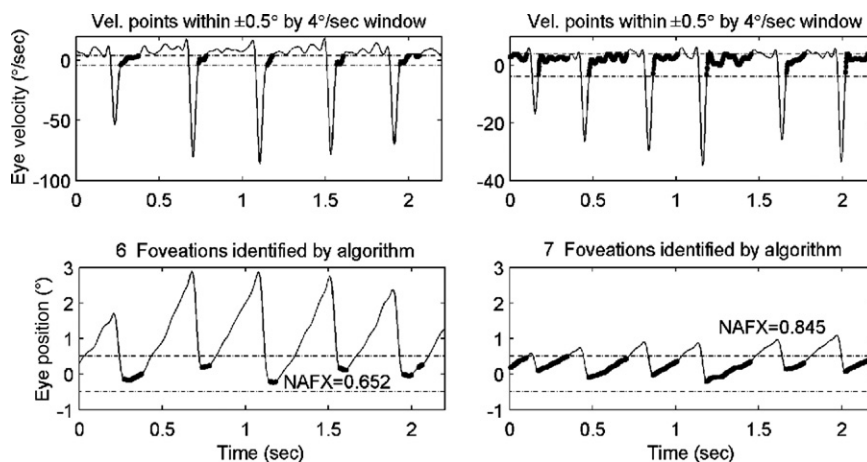


FIG 1. NAFX-program outputs comparing pre- and postsurgical waveforms from Patient 1 during left-eye fixation with both eyes open, in primary position (due to a small, prior head movement between recording trials, the postsurgical data were at -2.5°). Left columns are presurgical data and right columns are postsurgical data. Velocity traces (upper row) and position traces scaled for ease of interpretation (lower row) are shown. In each subplot, the NAFX-algorithm-determined foveation periods satisfying the foveation-window criteria are shown thickened. NAFX values for each corresponding segment are noted on the plots.

particular, were evaluated using the eXpanded Nystagmus Acuity Function (NAFX).

Subjects and Methods

Recording

The digital video system (EyeLink II, SR Research, Mississauga, ON, Canada) had a linear range of $\pm 30^\circ$ horizontally and $\pm 20^\circ$ vertically. System sampling frequency was 500 Hz, and gaze position accuracy error was 0.5° to 1° on average. The data were digitized at 500 Hz with 16-bit resolution. The EyeLink signal from each eye was calibrated with the other eye behind cover to obtain accurate position information; the foveation periods were used for calibration.⁹ Monocular primary-position adjustments for all methods allowed accurate position information and documentation of small tropias and phorias hidden by the nystagmus.

Protocol

This study was approved by the local institutional review board and written consent was obtained from each subject before the testing. All test procedures were carefully explained to the subject before the experiment began and were reinforced with verbal commands during the trials. Subjects were seated in a chair with headrest and a chin stabilizer, far enough from the stimulus screen to prevent convergence effects (>5 feet). At this distance the light-emitting diode subtended less than 0.1° of visual angle. The room light could be adjusted from dim down to blackout to minimize extraneous visual stimuli. An experiment consisted of from 8 to 10 trials, each lasting under a minute with time allowed between trials for the subject to rest. Trials were kept this short to guard against boredom because infantile nystagmus intensity is known to decrease with inattention.

Analysis

All the analyses were unmasked and done in MATLAB environment (The MathWorks, Natick, MA) using OMLAB software

(OMtools, available from <http://www.omlab.org>). Only eye position was sampled directly; velocity was derived from the position data by a fourth-order central-point differentiator. Position data were prefiltered with a low-pass filter with the cutoff frequency of 20 Hz to eliminate noise without changing the nystagmus signals to be studied. The differentiating and filtering were applied equally to the pre- and postsurgical data sets to ensure consistency. Analysis was always performed on the fixating eye. The postsurgical records for Patient 1 were obtained 6 weeks after the procedure; for Patient 2, 8 weeks. It was reported that visual functions were stable within this time period.⁶

The NAFX was used to measure tenotomy-induced changes in the infantile nystagmus in primary position and various gaze angles. It is an objective measure of waveform quality and a predictor of potential visual acuity for nystagmus patients assuming that no afferent deficits are present. It can be applied to any nystagmus waveform whose foveation variability (position and velocity) lies within the maximum foveation window of $\pm 6^\circ$ and $\pm 10^\circ/\text{second}$. Five or more primary-position NAFXs for each patient in this study were calculated and averaged; the segments chosen avoided blinks and inattention periods. At each gaze angle, two or three NAFX calculations were made and averaged, depending on the data availability. When choosing the segments, we maintained consistency in the pre- and postsurgical data sets; that is, the best segments for foveation were chosen, so that the NAFX average would reflect the best potential visual acuity for the patient. This methodology duplicates that used in masked clinical trials.^{6,7} Two outputs will be listed and discussed in the results section. Details about the NAFX may be found elsewhere.¹⁰

Primary-position visual acuities were obtained by the referring physician (Snellen chart at distance and near card using Jaeger scale). Potential visual acuities were provided by the NAFX program as a comparison. Stereopsis was measured by

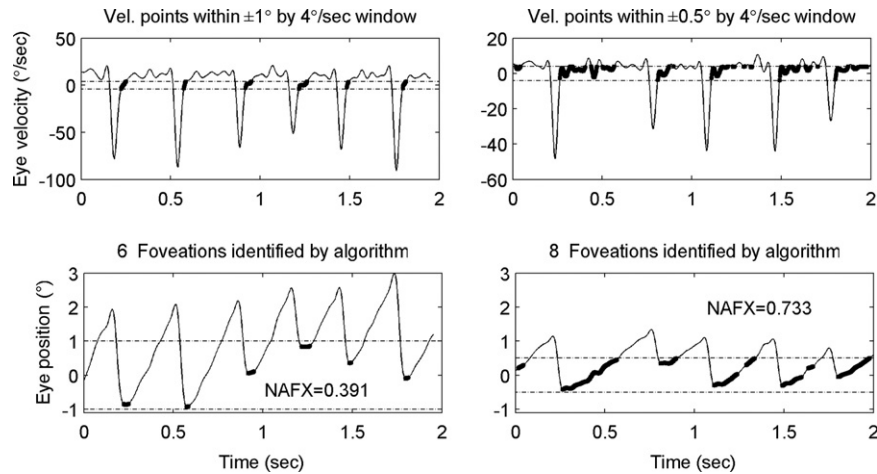


FIG 2. NAFX-program outputs comparing pre- and postsurgical waveforms from Patient 1 during left-eye fixation with both eyes open, at 10° downgaze. Due to a small, prior head depression, the postsurgical data were at 9° down. Left columns are presurgical data and right columns are postsurgical data.

Titmus fly and Randot Stereo Tests (Stereo Optical, Chicago, IL). Pre- and postsurgical peak-to-peak amplitude in primary position was measured by taking the average of 16 amplitude measurements from different nystagmus cycles. The samples were chosen with the same criteria as described previously for the NAFX analysis. Second-order polynomial curves were fitted to pre- and postsurgical NAFX values at each gaze angle. Eye movement movies were made from primary-position fixation data with custom-defined MATLAB programs.

Results

Patient 1

The first patient was a 44-year-old man who had intractable oscillopsia for 14 years that was resistant to drug therapy. He preferred left-eye fixation; he had stereopsis of 50" of arc, rightward internuclear ophthalmoplegia, and predominantly vertical nystagmus (downbeat nystagmus). The patient also had right-eye hypertropia of 7° and esotropia of 3° to 5°. He exhibited a marked chin-down position. Eye-muscle surgery was done 12 years prior for diplopia from a traumatic fourth-nerve palsy, but no surgical notes could be obtained. At the time of our surgery no evidence of conjunctival scarring was evident and the operated muscles were in their normal anatomic positions, indicating that surgery on these muscles had not been done previously. Superior rectus muscles were recessed asymmetrically (left, 5 mm and right, 6 mm) to simultaneously rotate both eyes 10° downward (5 mm both eyes) and reduce the right hypertropia (1 mm right eye); both IR muscles were tenotomized to complete the four-muscle tenotomy. Thus, a *vertical* (Anderson + strabismus + tenotomy) procedure was performed.

Following the combined procedure, the patient's primary-position NAFX values were improved by 17%; foveation time per cycle increased 102% from 88 to 178 ms, and visual acuity increased 25% from 20/25 to 20/20 + 1. Vertical-component amplitude was reduced by 46%, and

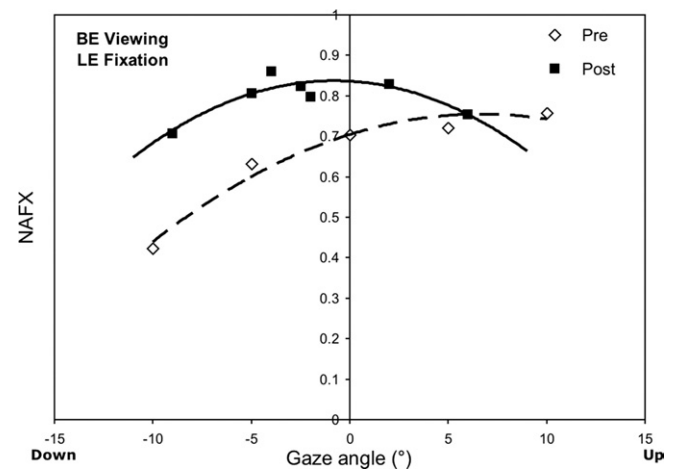


FIG 3. NAFX versus gaze angle curves for Patient 1, who had a null at 10° downgaze presurgically. *BE*: both eyes; *LE*: left eye. For this and Figures 6 and 7, open symbols denote presurgical data and filled symbols denote postsurgical data; the presurgical NAFX curve is dashed, and the postsurgical NAFX curve is solid.

frequency was unchanged at ~3 Hz. Vertical NAFX values increased across the -10° to +5° vertical range, suggesting improved visual function. As is shown in Figure 1, in the primary position, the postsurgical foveation periods were longer and better aligned. The NAFX values for these intervals increased 29.6% from 0.652 to 0.845. Similar changes at 10° downgaze are shown in Figure 2, with the NAFX values increased 87.5% from 0.391 to 0.733.

The broadening effect may be observed in the patient's NAFX versus gaze angle curves, as shown in Figure 3. His NAFX peak was moved from 10° up to primary position (eliminating the chin-down position) and the curve was effectively broadened, increasing the patient's high-acuity region. The right hypertropia was reduced to 3 to 4° and stereopsis was maintained.

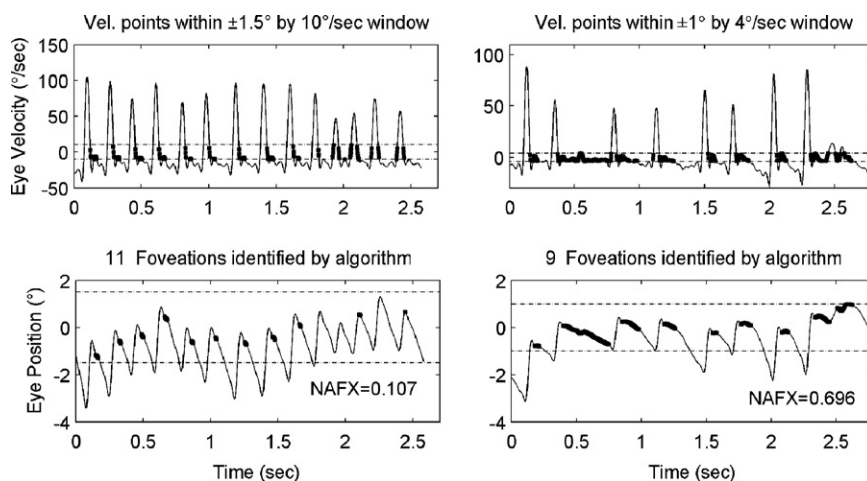


FIG 4. NAFX-program outputs comparing pre- and postsurgical waveforms from Patient 2 during forced left-eye fixation (right eye occluded) in primary position. Left columns are presurgical data and right columns are postsurgical data.

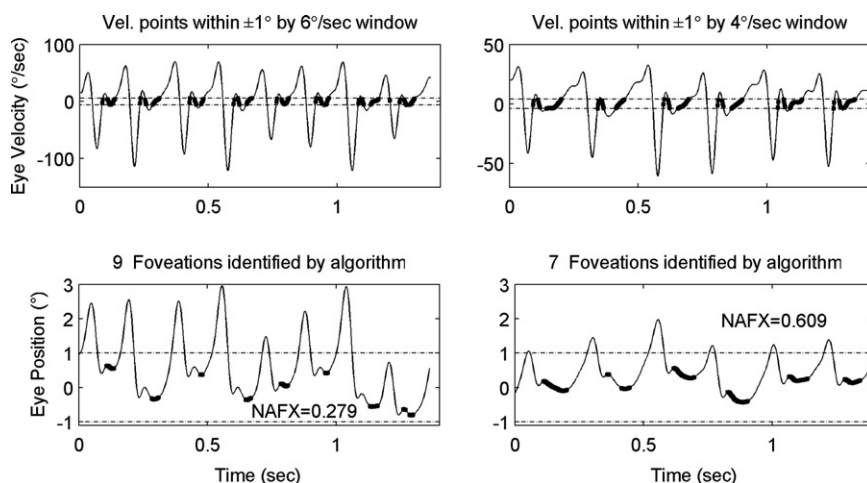


FIG 5. NAFX-program outputs comparing pre- and postsurgical waveforms from Patient 2 during both-eye viewing and right-eye fixation in primary position. Left columns are presurgical data and right columns are postsurgical data.

We used data from primary-position foveation to drive the eyes in Video 1 (available at jaapos.org), demonstrating the clinical impression of postsurgical effects. The same data were used for demonstrating the amplitude reduction and foveation improvement in Video 2 (available at jaapos.org). Both movies were made at half-speed. Note that the vertical component is dominant. The reduction of the amplitude postsurgically is evident on both movies. The phase planes in Video 2, which shows the time spent within the foveation window, demonstrate that the reduction of downbeat nystagmus and the improvement of postsurgical foveation quality greatly contribute to the elevation of patient's visual function. The patient also reported decreased frequency of diplopia and improvement in oscillopsia.

Patient 2

The second patient was a 49-year-old man who had predominantly horizontal infantile nystagmus syndrome and

diplopia. The patient preferred left-eye viewing in left gaze, right-eye viewing in right gaze. Stereopsis was $>3000^\circ$ of arc. There was a left-eye exotropia of 20° . A *horizontal* (tenotomy + recession) procedure was performed, with both lateral rectus muscles recessed 8 mm and both medial rectus muscles tenotomized.

The procedure transformed two lateral, narrow NAFX versus gaze angle curves (due to fixating-eye changes) into one broad curve with a 43% increase in primary position where acuity increased 92.3%, from 20/150 to 20/80. There was a slight decrement in left gaze. In primary position, foveation time per cycle increased 257.4%, from 35.5 to 126.9 ms; horizontal-component amplitude was reduced by 45.7%, and frequency remained unchanged at ~ 4 Hz. Fixation data of left-eye viewing in primary position is shown in Figure 4; there was a 550% NAFX increase postsurgically (from 0.107 to 0.696). In Figure 5, which is right-eye

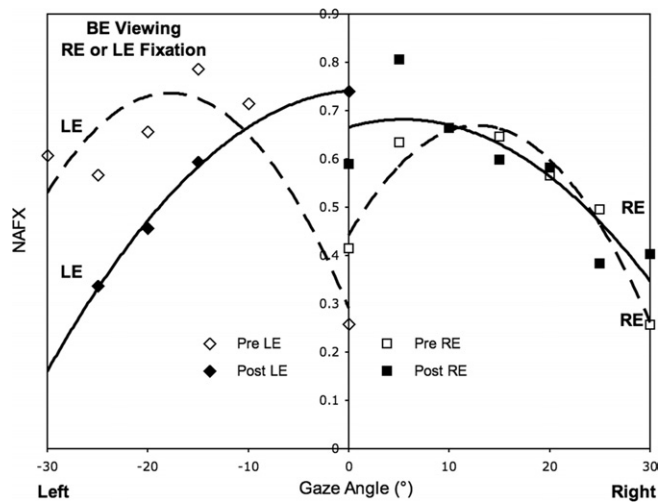


FIG 6. NAFX versus gaze angle curves for Patient 2, binocular viewing, and monocular fixation. Square symbols are RE-fixation data and diamond symbols are LE-fixation data. *BE*: both eyes; *RE*: right eye; *LE*: left eye.

viewing, a 118% NAFX increase occurred (from 0.279 to 0.609).

This exotropic patient had an interesting fixation preference—left-eye fixation in the left field of gaze and right-eye fixation in the right field (in primary position, either eye was used); this is opposite to the fixation pattern normally shown in esotropia. The data contained no evidence of any adduction lags. Pre- and postsurgically (Figure 6), the two lateral, narrow NAFX peaks were transformed into one broad peak, with the NAFX in primary position greatly increased. Thus, although the left eye was still preferred for all targets to the left of center and the right eye for all targets to the right of center, the potential acuity across the central 30° was improved, especially the acuity in primary position for either eye.

The patient's diplopia amplitude was decreased; his ability to converge was regained, and to hold gaze was improved. The right exotropia was reduced to ~10°. Videos 3 and 4 (available at www.jaapos.org) are primary-position, fixation-data demonstrations of the pre- and postsurgical changes. Stereovision was not restored after the surgery.

Discussion

The purpose of this study was to investigate the effects of combined tenotomy on two different kinds of nystagmus. Listed in Table 1 is a comparison of the two patients' clinical profiles. They have different nystagmus types, planes, sensory deficits, and presurgical visual acuities; however, they both benefited from the combined procedures, in primary position and lateral gaze, as shown in Table 2.

Because it is impossible to recess or resect a muscle without an obligate tenotomy, one could not separate out the effects of the muscle-moving and muscle-detaching components of either. Sequentially recessing or resecting

two muscles and then tenotomizing the other two can only differentiate the combined recession or resection plus tenotomies from the additional two tenotomies. However, prior studies, using four-muscle tenotomies alone, demonstrated that the waveform improvements and "null" broadening effects of Anderson-Kestenbaum procedures were due solely to the obligate tenotomies, ie, the recessions and resections only shifted the "null" position. Thus, in these two patients, we also attribute the improvements in waveforms and the broadening of the "null" regions to the four-muscle tenotomy component of each procedure.

In Figure 7, the age-adjusted NAFX (40- to 60-year-old group) versus visual acuity line (established in previous studies from normal population data⁸) is plotted along with data points from both patients. Previous studies demonstrated the linear relationship between the NAFX values and the potential visual acuity of individuals with nystagmus, in the presence of a constant, or minimally changing, deficit in the afferent visual system.¹⁰ Patient 1 had no afferent deficits and the data points for potential and measured acuities were close to each other; they overlapped for the postsurgical data. For Patient 2, the vertical difference between the potential and the measured values reflects the decrement in acuity due to the afferent visual system deficits. This difference was relatively fixed during the course of our study; therefore, the decrement was preserved postsurgically. By drawing a second (dashed) line with the same slope as the age-adjusted line through the presurgical measured-acuity data point, we found that the postsurgical data fell along this line of estimated, *measured* visual acuity. Note that the intersection of the dashed line with the NAFX value of 1.0 (ie, no nystagmus) is ~20/25, indicating that even if the nystagmus was abolished, the visual acuity would still be reduced by the afferent visual system deficit. In both patients (one with an afferent visual deficit and one without, one acquired and one infantile), the preoperative NAFX and measured acuity values *predicted* both the best potential visual acuities (as they were designed to do) and the *estimated* postoperative measured acuities. Our prior publications on the NAFX have also demonstrated many patients' NAFX and acuity values fall on or near the appropriate age-determined line.

It was previously reported that, in addition to elevating primary-position NAFX, tenotomy also broadens the high-NAFX regions in infantile nystagmus patients, therefore resulting in improvements in visual function beyond primary-position acuity.¹¹ The broadening effect was also observed in the two patients in our study. The types of nystagmus that tenotomy has now been demonstrated to be effective include infantile nystagmus syndrome (plus asymmetric (a)periodic alternating nystagmus), acquired pendular nystagmus, downbeat nystagmus, and seesaw nystagmus.^{6-8,12} Because each of these types of nystagmus has a different mechanism and putative anatomical site, it is unlikely that tenotomy affects central signals. We pre-

Table 1. Patients' clinical profile and eye-movement characteristics

	Nystagmus type	Plane	Strabismus	Sensory deficit	Presurgical			Other
					Primary position visual acuity	Primary position NAFX	NAFX peak	
Patient 1	Acquired DBN	Vertical	ET	No	20/25	0.704	-10°	Diplopia oscillopsia
Patient 2	INS	Horizontal	XT	Yes	20/150	0.415	LE: >20°L RE: 15°R	Diplopia

Table 2. Summary of postsurgical changes

	Measurement	NAFX	Potential acuity	Measured acuity	Foveation time per cycle (ms)	Amplitude (°pp)
Patient 1	Presurgical	0.704	0.852 (20/23)	0.8 (20/25)	88	1.87
	Postsurgical	0.824	0.997 (20/20)	1.0+ (20/20+1)	178	1.01
	Percentage change	+17%	+17%	+25%	+102%	-46%
Patient 2	Presurgical	0.415	0.502 (20/40)	0.13 (20/150)	35.5	2.54
	Postsurgical	0.592	0.716 (20/28)	0.25 (20/80)	126.9	1.38
	Percentage change	+43%	+43%	+92.3%	+257%	-45.7%

Measurements were all obtained in primary position.

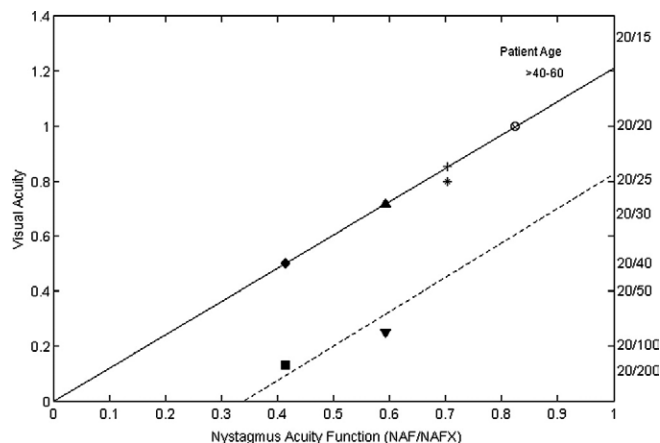


FIG 7. NAFX versus visual acuity, age-adjusted line with pre- and postsurgical data points for both potential and measured acuities for both patients. Patient 1, open symbols: plus sign, presurgical; cross, postsurgical potential acuities; star, presurgical; circle, postsurgical measured acuities. Patient 2, solid symbols: diamond, presurgical; up-triangle, postsurgical potential acuities; square, presurgical; and down-triangle, postsurgical measured acuities.

viously hypothesized that tenotomy works by changing the proprioceptively controlled resting tension in the extraocular muscles, thereby reducing the small-signal (ie nystagmus slow-phase) gain of the ocular motor plant.¹² We subsequently demonstrated that large signals, that is, saccades, were not affected by tenotomy.¹³ Recent studies on palisade endings and their proprioceptive role in the extraocular muscles have supported the proposed mechanism for tenotomy's effects and suggested anatomical sites for ocular motor proprioceptors.¹⁴⁻¹⁶

The combined procedures reduced acquired nystagmus and oscillopsia and improved visual acuity in both downbeat nystagmus (Patient 1) and infantile nystagmus

(Patient 2). Because binocularity was not restored, the improvement in nystagmus at far cannot be attributed to convergence damping. Since the muscle insertions are several millimeters anterior to the equator of the eyes, small-to-moderate recessions do not diminish muscle action until the eye is moved into the field of action of that muscle. Thus, the damping of small signals in primary position (eg, nystagmus) was not due to mechanical changes secondary to recession. The postsurgical improvements demonstrated the necessity of tailoring each procedure based on the evaluation of the idiosyncratic eye-movement characteristics. We believe that combined muscle-movement (for nystagmus "null" shifting or strabismus correction) and tenotomy (for nystagmus damping and waveform quality improvement) procedures produce more effective and individualized nystagmus treatments.

References

1. Anderson JR. Causes and treatment of congenital eccentric nystagmus. *Br J Ophthalmol* 1953;37:267-81.
2. Kestenbaum A. Nouvelle operation de nystagmus. *Bull Soc Ophthalmol Fr* 1953;6:599-602.
3. Dell'Osso LF, Flynn JT. Congenital nystagmus surgery: a quantitative evaluation of the effects. *Arch Ophthalmol* 1979;97:462-9.
4. Dell'Osso LF. Extraocular muscle tenotomy, dissection, and suture: a hypothetical therapy for congenital nystagmus. *J Pediatr Ophthalmol Strabismus* 1998;35:232-3.
5. Dell'Osso LF. Development of new treatments for congenital nystagmus. In: Kaminski HJ, Leigh RJ, editors. *Neurobiology of Eye Movements. From Molecules to Behavior*. Ann NY Acad Sci 956. New York: NYAS; 2002.
6. Hertle RW, Dell'Osso LF, FitzGibbon EJ, Thompson D, Yang D, Mellow SD. Horizontal rectus tenotomy in patients with congenital nystagmus. Results in 10 adults. *Ophthalmology* 2003;110:2097-105.
7. Hertle RW, Dell'Osso LF, FitzGibbon EJ, Yang D, Mellow SD. Horizontal rectus muscle tenotomy in patients with infantile nystagmus syndrome: a pilot study. *J AAPOS* 2004;8:539-48.

8. Tomsak RL, Dell'Osso LF, Rucker JC, Leigh RJ, Bienfang DC, Jacobs JB. Treatment of acquired pendular nystagmus from multiple sclerosis with eye muscle surgery followed by oral memantine. *Digital J Ophthalmol* 2005;11:1-11.
9. Dell'Osso LF. Recording and calibrating the eye movements of nystagmus subjects. *Journal* 2005;#011105:1-4. http://www.omlab.org/OMLAB_page/Teaching/teaching.html.
10. Dell'Osso LF, Jacobs JB. An expanded nystagmus acuity function: intra- and intersubject prediction of best-corrected visual acuity. *Doc Ophthalmol* 2002;104:249-76.
11. Wang Z, Dell'Osso LF, Jacobs JB, Burnstine RA, Tomsak RL. Effects of tenotomy on patients with infantile nystagmus syndrome: foveation improvement over a broadened visual field. *J AAPOS* 2006 (in press).
12. Dell'Osso LF, Hertle RW, Williams RW, Jacobs JB. A new surgery for congenital nystagmus: effects of tenotomy on an achiasmatic canine and the role of extraocular proprioception. *J AAPOS* 1999;3:166-82.
13. Wang Z, Dell'Osso LF, Zhang Z, Leigh RJ, Jacobs JB. Tenotomy does not affect saccadic velocities: Support for the "small-signal" gain hypothesis. *Vision Res* 2006;46:2259-67.
14. Jaggi GP, Laeng HR, Müntener M, Killer HE. The anatomy of the muscle insertion (scleromuscular junction) of the lateral and medial rectus muscle in humans. *Invest Ophthalmol Vis Sci* 2005;46:2258-63.
15. Eberhorn AC, Horn AKE, Fischer P, Büttner-Ennever JA. Proprioception and pallsade endinge in extraocular eye muscles. In: Ramat S, Straumann D, editors. *Clinical and Basic Oculomotor Research. In Honor of David S. Zee—Ann NY Acad Sci 1039*. New York: NYAS; 2005.
16. Niechwiej-Szwedo E, Gonzalez E, Bega S, Verrier MC, Wong AM, Steinbach MJ. Proprioceptive role for pallsade endings in extraocular muscles: evidence from the Jendrassik maneuver. *Vision Res* 2006;46:2268-79.



First Person

Camille had surgery for eyes that wandered outward. As she slept in the recovery room that morning, I warned her mother about a typical early response to the surgery—her daughter might see double for a few days. When Camille arrived at home that afternoon, she was delighted. “Doctor Hunter gave me MAGIC EYES!” she exclaimed. “I see TWO mommies!” She went about her activities for the day, even took a short bike ride to see the new magical world, but she tired quickly and went to bed early. The next morning, she was still seeing double, but was less than delighted. “I don’t like these magic eyes, mommy. I want my old eyes back.”

Fortunately, the double vision had worn off by the afternoon. Mother said, “I had gotten so used to her eyes being ‘off’ all of the time. But today, for the first time ever, I feel like I was able to look my daughter in the eyes, and she looked right back at me. She does not have “off” eyes anymore, or ‘magic’ eyes, she just has beautiful eyes.”

—David G. Hunter, MD, PhD

The word “downgaze” should be corrected to “upgaze” on page 137 Figure legend 3.