

# Horizontal Rectus Muscle Tenotomy in Children With Infantile Nystagmus Syndrome: A Pilot Study

Richard W. Hertle, MD,<sup>a</sup> Louis F. Dell'Osso, PhD,<sup>b</sup> Edmond J. FitzGibbon, MD,<sup>c</sup> Dongsheng Yang, PhD,<sup>a</sup> and Susan D. Mellow, RN<sup>c</sup>

**Purpose:** We wished to determine the effectiveness of horizontal rectus tenotomy in changing the nystagmus of children with infantile nystagmus syndrome. **Design:** This was a prospective, noncomparative, interventional case series in five children with varied sensory and oculographic subtypes of congenital nystagmus (including asymmetric (a)periodic alternating nystagmus) and no nystagmus treatment options. Simple tenotomy of all four horizontal recti with reattachment at the original insertion was accomplished. Search-coil and infrared eye movement recordings and clinical examinations were performed before and 1, 6, 26, and 52 weeks after surgery. Outcome measures included masked pre- and postoperative expanded nystagmus acuity function (NAFX), foveation time obtained directly from ocular motility recordings, and masked measures of visual acuity. **Results:** At 1 year after tenotomy and under binocular conditions, two of the three patients for whom the NAFX could be measured had persistent, significant postoperative increases in the NAFX of their fixating eye. Average foveation times increased in these patients' fixating eyes. Measured binocular visual acuity increased in four patients; the remaining patient had retinal dystrophy. There were no adverse events due to surgery. **Conclusions:** In the two children who could fixate the targets for several seconds and for whom we could obtain accurate measurements of their infantile nystagmus, tenotomy resulted in significant improvements in nystagmus foveation measures. In those patients plus two others (four of five), measured visual function improved. (J AAPOS 2004;8:539-548)

Infantile nystagmus syndrome (INS) is an ocular motor disorder of unknown etiology that presents at birth or early infancy and is clinically characterized by involuntary oscillations of the eyes.<sup>1</sup> Other clinical characteristics of the nystagmus, with variable association, include increased intensity with fixation, decreased intensity with sleep or inattention; variable intensity in different positions of gaze (null positions); changing direction in different positions of gaze (neutral positions); decreased intensity with convergence (damping); anomalous head postur-

ing; strabismus; and the increased incidence of significant refractive errors.<sup>2,3</sup> INS can also occur in association with congenital or acquired defects in the visual sensory system (eg, albinism, achromatopsia, congenital cataracts, optic nerve, and/or foveal hypoplasia).<sup>4</sup>

Patients with INS usually also have diminished visual acuity, significantly diminished if associated with afferent deficits. The visual acuity may be inversely related to the intensity of the nystagmus in those patients whose ocular motor system can take advantage of reduced intensity to improve the INS waveform and in whom no other sensory defect is present (eg, foveal or optic nerve hypoplasia)<sup>5</sup> and contributes to further visual loss in patients in whom sensory defects are present.<sup>6</sup> Some patients with INS exhibit adaptive mechanisms to improve their INS waveforms and, thereby, their vision.

One of the most common features of the INS waveforms is the presence in segments of the slow phase wherein the eyes remain at or close to the point of desired fixation with little or no movement.<sup>7-9</sup> These "foveation periods" have been shown to enhance visual acuity. The accuracy and duration of foveation has been directly linked to visual acuity.<sup>5,7-10</sup> If these periods can be lengthened or increased by the patient (adaptation) or by therapeutic interventions, the patient's visual acuity may be increased.

*From the Department of Ophthalmology, Children's Hospital of Pittsburgh,<sup>a</sup> Pittsburgh, PA; The Ocular Motor Neurophysiology Laboratory, Louis Stokes Cleveland VA Medical Center, Departments of Neurology and Biomedical Engineering, Case Western Reserve University,<sup>b</sup> Cleveland, Ohio; and The Laboratory of Sensorimotor Research and The National Eye Institute, The National Institutes of Health,<sup>c</sup> Bethesda, Maryland.*

*This paper has been presented in part at the 2004 meetings of the American Association of Pediatric Ophthalmology and Strabismus, Washington, D.C.*

*This study was supported in part by the Veterans Affairs Merit Review (Dr. Dell'Osso).*

*The authors have no financial interest in any of the ideas or procedures discussed in this paper.*

*Submitted March 9, 2004.*

*Revision accepted August 9, 2004.*

*Address reprint requests to Richard W. Hertle, MD, Department of Ophthalmology, Children's Hospital of Pittsburgh, 3705 Fifth Avenue, Pittsburgh, PA 15213.*

*Copyright © 2004 by the American Association for Pediatric Ophthalmology and Strabismus.*

*1091-8531/2004/\$35.00 + 0*

*doi:10.1016/j.jaapos.2004.08.005*

There is no cure for INS or many of the visual sensory system deficits that are associated with INS. Visual benefits are observed in patients who underwent the Anderson-Kestenbaum (AK) surgical procedure, although the procedure's primary purpose is to decrease torticollis in patients whose nystagmus intensity is least in gaze angles away from primary position. It was originally designed to straighten these patients' face or head turn, which they were performing to maximize their visual acuity.<sup>11,12</sup>

The discovery of the beneficial *secondary effects* (lower nystagmus and increased acuity in and outside of the null zone, increased width of the null zone, more "beneficial" waveforms in the null zone) of the AK<sup>2,13</sup> effects led to the hypothesis that the same broadening and damping could be achieved by performing a variation of the AK procedure *without* the resection or recession.<sup>14,15</sup> That is, simply tenotomizing the four horizontal recti and reattaching them at their original insertions. For 12 years after the initial clinical and electrophysiological observations of the beneficial secondary effects were made, an animal model was sought, upon which the hypothetical procedure could be tried. In 1991, such a model appeared in achiasmatic members of a family of Belgian sheep dogs.<sup>14,15</sup> Studies of the eye movements of the affected dogs in this family revealed horizontal (and sometimes) vertical INS plus a congenital see-saw nystagmus (SSN). It was first shown in this animal model that tenotomy alone duplicated the damping effects first documented in human patients after undergoing the full AK procedure.<sup>14</sup> Since that report, we have demonstrated that in 9 of 10 adult patients (including 5 with albinism and 1 with achiasma) with clinical and oculographic variations in their INS, tenotomy resulted in significant improvements in their nystagmus waveforms along with improvements in subjective visual function.<sup>16</sup> This report summarizes the findings of horizontal rectus tenotomy in a prospective cohort of five children with INS.

## STUDY DESIGN AND METHODS

This study was approved by the National Eye Institute, Institutional Review Board and Data Safety Monitoring Committee (Protocol no. 99-EI-0152) with Coordinating Center support through contract N1-EY-1-2113. After initial screening examination, satisfying inclusion/exclusion criteria, and signing of informed consent, the subjects underwent a full initial protocol ophthalmic examination, baseline oculographic evaluation followed by tenotomy surgery, and follow-up ophthalmic and oculographic examinations. Data collection included historical information; gender; ethnicity; age at diagnosis of INS; prior ophthalmic treatments (spectacles, prisms, orthoptics); prior medical treatments (acupuncture, biofeedback, medicines, etc.); other ocular conditions and treatments; significant medical illnesses; history of other surgical procedures; and allergies to medicines or environmental agents.

For inclusion in the study, the patient must have had a clinical and oculographically confirmed diagnosis of INS, binocular best-corrected visual acuity of 20/400 to 20/50, been able to undergo a complete ophthalmic evaluation, standard eye movement recording, medically undergo extraocular muscle surgery, and have been available for 1 year of follow-up.

Exclusion criteria for patients included prior extraocular muscle surgery; other treatment options available for their nystagmus (specifically those INS patients who have an eccentric null position or convergence damping of their nystagmus); other indications for extraocular muscle surgery (eg, a significant head posture or strabismus requiring surgical correction, ie, >8 prism diopters horizontal or 6 prism diopters vertical deviation); have a null position greater than 10° from primary position horizontally, 5° vertically, or 5° torsionally; be on systemic medication known to affect ocular oscillations; have concurrent medical conditions or known risks which would increase their chance of an adverse event due to general anesthesia (greater than a ASA Class 1); or have a family history of malignant hyperthermia. The NEI Data and Safety Monitoring Committee (DSMC) was responsible for reviewing the study design and, as appropriate, recommending design changes.

Ophthalmic examinations were performed three times within a 3-month period prior to tenotomy and at 1, 6, 26, and 52 weeks after tenotomy and included ETDRS (in three children) and ATS HOTV<sup>17</sup> (in two children) visual acuity (an outcome measure) by certified, masked technicians, pupillary examination, ocular motility examination, nystagmus pattern in all fields of gaze as well as response to convergence, cover, and the presence and amount of any head posturing at distance and 33 cm, stereo testing with the Wirt stereo test, slit-lamp biomicroscopy of the lids and anterior segments, cycloplegic refraction, and dilated examination of the retina and optic nerves with indirect ophthalmoscopy.

Two investigators (E.J.F. and D.Y.), not involved with the clinical examination or surgery on the patients, performed the eye movement recordings three times within a 3-month period prior to tenotomy and at 1, 6, 26, and 52 weeks after tenotomy. Eye movement data were collected using the magnetic induction and scleral search coil in two patients and an infrared method in three patients. Calibration was accomplished monocularly (trial 1 during right-eye fixation and trial 2 during left-eye fixation) using targets placed horizontally at 0° and ±(15, 20, 25, and 30°) for the search coil and 0° and ±10° for the infrared. Eye-position and stimulus signals were digitized on-line at 1000 Hz (search coil) and eye-position signals at 500 Hz (infrared) and stored on computer for later analysis.

Accurate ocular motor recording and calibration of children is problematic and requires constant real-time monitoring to ensure they are following instructions and fixating the targets for the required periods of time. Spe-

cific requirements include on-line, eye-position monitoring and display to enable the experimenter to evaluate the patient's compliance to the instructions and to encourage the patient to fixate the target when his attention wanders (as it often does for LED targets); without this ability, digitized data acquisition becomes more variable. With the search-coil method, the coils are precalibrated but the zero-position offset for each eye (*during monocular fixation*) must be set using the stored data. With the IR method, both the zero-position offset and positive and negative gains for each eye during monocular fixation require accurate and repetitive fixation of the targets as well as digitized stimulus signals to show the target position at all times. Accurate determination of the zero-position offset data for each eye during monocular fixation (trials 1 and 2) is imperative as it allows measurement of subsequent tropias and determination of the fixating eye during binocular viewing (trials 3–8); the NAFX must be calculated from the eye *actually* fixating during the interval of data chosen if it is to reflect potential acuity.

In Phase 1 of this study,<sup>16</sup> using adult patients and only the search-coil method, problems with calibration were minimized. In this study, using children, the problems created by their failure to fixate the targets adequately for either calibration or analysis were more evident and the absence of real-time monitoring of eye-position data during the trials, digitized stimulus signals, or, in some cases monocular fixation records for each eye, resulted in many of the stored infrared records being of insufficient quality for either accurate calibration or analysis. However, when taken under optimal conditions, both infrared and high-speed digital video data from children as young as 4 years old can be accurately calibrated and analyzed when on-line data are displayed, enabling the experimenter to encourage the subject to look at the target (note that Subject 3 was 5 years old and his infrared data were successfully calibrated and analyzed despite suboptimal recording conditions).

One investigator (R.W.H.) performed the surgery on all patients under general anesthesia. Using standard strabismus surgical techniques, all four horizontal rectus muscles were identified and isolated and a suture was placed through the tendon. The tendon was cut off the surface of the globe and immediately reattached at the original insertion site. The wounds were closed in standard fashion and antibiotic/steroid ointment was then placed in the eyes. Standard postoperative care consisted of daily application of antibiotic/steroid drops qid for 7 days and follow-up examinations at 1 day, 1 week, 6 weeks, 26 weeks, and 52 weeks.

One investigator (L.F.D.), not involved with the clinical examination, eye-movement recording, or surgery on the patients, transformed the data formats to one acceptable to the MATLAB<sup>R</sup> (computer software analysis package) environment and then resampled, calibrated, and analyzed the eye movement data. This was initially done in a masked fashion whereby data from each recording session

(identified only by a random number) prior to tenotomy and after tenotomy were analyzed in random order after the search-coil data were resampled at 200 Hz and the infrared at 250 Hz. However, when calibration problems became evident for some of the infrared data, the masking was removed in the hope of using intrasubject comparisons to aid in calibration but the data from Subjects 1 and 4 remained too inaccurate for subsequent analysis.

One direct outcome measure was the eXpanded Nystagmus Acuity Function, (NAFX).<sup>18</sup> The NAF, and later the NAFX, originated from the Nystagmus Foveation Function (NFF).<sup>5,7</sup> The Nystagmus Acuity Function (NAF) was developed to provide an objective measure of the quality of a nystagmus waveform, to predict potential best-corrected visual acuity in INS patients under benign conditions, and to assess the direct effects of treatments on the INS oscillation. The NAF was based on objective measurements (from eye movement data) of waveform characteristics during fixation of a small light-emitting diode. It combined the foveation time-per-cycle and the standard deviations of both eye position and velocity during target foveation into a function that is linearly proportional to best-possible visual acuity.

The NAFX incorporates the time intervals of foveation periods and their position and velocity standard deviations into a measure of the quality of an INS waveform (ie, how likely it was to allow good acuity). It assesses the *potential upper limits* of the acuities of individuals with poor foveation capabilities by allowing expansion of the foveation window based on the eye-movement data. Neither the NAFX nor the NAF, which it includes, are dependent on the methodology of data collection (eg, infrared, video, or magnetic search coil), the type of nystagmus (INS, latent/manifest latent nystagmus, etc.), or the particular nystagmus waveform—it is essentially a measure of foveation ability for any nystagmus waveform.

In this study, NAFX values calculated for fixation intervals from each recording session were averaged and it is those average NAFX values that appear in the figures. For the patient with INS plus APAN, the NAFX values used were for fixation during the best portions of the APAN cycle in each direction. In addition, foveation-period durations and peak-to-peak INS amplitudes were calculated as secondary outcome measures.

## RESULTS

### Patient Demographics

Table 1 contains the age, gender, and associated eye disease of the five enrolled patients. The ages of the patients at the time of surgery were 5, 7, 9, 13, and 16 years. Three patients were white, one was Hispanic, and one was African American. Four were male. One patient had Asymmetric (a)Periodic Alternating Nystagmus (APAN), two patients (with achiasma) also had see-saw nystagmus, and 3 patients had associated childhood strabismus and no indication for surgical treatment of their strabismus. There

**TABLE 1.** Clinical Characteristics

Patient No.	Age/Sex	Clinical Characteristics
1	9/M	INS/SSN/Achiasma/ET/OD Preference
2	13/M	Retinal Dystrophy/INS/Ortho/NO Preference
3	5/M	INS/SSN/Achiasma/ET/OD Preference
4	7/F	INS/APAN/OS Preference
5	16/M	Idiopathic INS/XT/OS Preference

M = male; F = female; ET = esotropia; XT = exotropia; Ortho = orthotropia; OS = left eye; OD = right eye; INS = congenital nystagmus; APAN = asymmetric (a)periodic alternating nystagmus; SSN = see-saw nystagmus.

were no adverse events secondary to surgery or the examination techniques.

### Direct Outcome Measure—NAFX

For each patient for whom accurately calibrated data could be obtained, the NAFX values calculated during fixation in primary position were averaged in each session and plotted for the preop and postop recording sessions. The data collected for Subjects 1 and 4 (using infrared) were as follows: too variable (reflecting an inability to foveate the target long enough); sometimes unresponsive to target stimuli; and sometimes lacked both monocular fixation records. That, coupled with the lack of a digitized stimulus record, prevented accurate calibration and precluded application of the NAFX. Although Subject 2 was studied using the search-coil method, he failed to fixate the primary-position target in a repeatable manner or with sufficient time duration for the resulting NAFX values to reflect his potential acuity. Typical NAFX variation in a single trial ranged from 0.126 (20/170) during jerk waveforms to 0.720 (20/20-) during jerk with extended foveation waveforms. Such large and consistent variation was not seen in the Phase 1 data, where NAFX variations were usually in the second decimal place.<sup>16</sup> Further examination of Subject 2's data revealed consistently better waveforms for the right-20° target with high NAFX values (0.673 to 0.720), equivalent to a potential acuity of 20/20.

Fig. 1 is a representative output of the NAFX program for fixation intervals taken from both the pretenotomy and the posttenotomy data for Subject 3. The figure demonstrates that both the position and the velocity boundaries of the foveation window were decreased, resulting in lower SDs of mean foveation position, longer foveation periods, and a 24% higher NAFX for this fixation interval.

Fig. 2 is a representative output of the NAFX program for fixation intervals taken from both the pretenotomy and posttenotomy data for Subject 5. Again, tenotomy resulted in an improvement in the relevant foveation parameters and a 38% increase in the NAFX for this fixation interval.

Fig. 3 shows the average NAFX values during the course of this study for 2 patients with INS (top) and the NAFX percentage increases (bottom). We fitted the data for each subject with logarithmic curves and also plotted and curve-fitted the average NAFX for both patients (heavy curves). The patients showed an immediate rise in

the NAFX and retention of that increase after 1 year; this mimics the responses reported for the 10 adult patients in Phase 1 of this study.<sup>16</sup> Also after 1 year, the average NAFX increase was approximately 20%. The individual increases were approximately 5.5% for Subject 3 (who's initial NAFX was already high) and 31% for Subject 5.

### Indirect Outcome Measure—Visual Acuity

Table 2 shows binocular best-corrected visual acuity change measured before and at 6 weeks after tenotomy. No patient experienced a decrease of five or more letters, equivalent to a loss of one line worsening in best-corrected visual acuity. Four patients had an improvement of five letters or more (one logMAR line of acuity). Pre- to Postoperative changes in acuity for each patients are as follows: Patient 1, 20/60 to 20/40, Patient 2, 20/60 to 20/60, Patient 3, 20/50 to 20/40, Patient 4, 20/40 to 20/25, and Patient 5, 20/50 to 20/25. The 6-week acuity was used as an outcome measure to eliminate an age effect of acuity if the 52-week data were used as the outcome. We assumed that any change in acuity at the 6-week outcome was due to the surgical procedure and not due to age, learning, or change in refractive status

### Direct Outcome Measures—Foveation-Period Duration and Peak-to-Peak Amplitudes

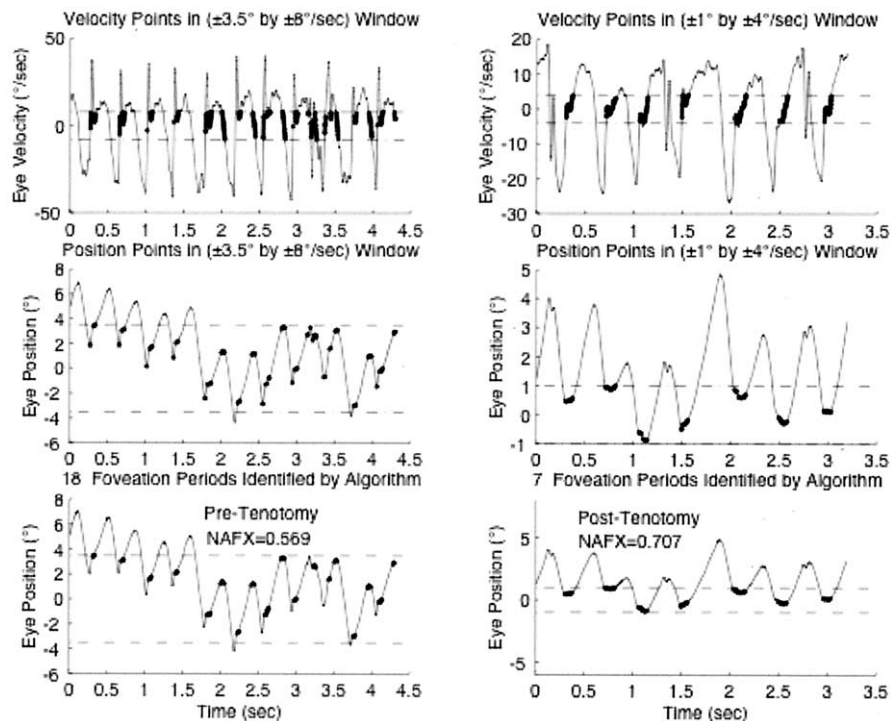
The average foveation-period durations of Subjects 3 and 5 went from 97 to 164 ms and 46 to 145 ms, respectively; the respective percentage increases were 69 and 215% after 1 year. Their average peak-to-peak amplitudes went from 4.4 to 4.2° (no change in Subject 3) and 3.0 to 2.1° (a 30% decrease for Subject 5). Although the quality of Subject 4's data prevented accurate calibration, we were able to measure the time intervals of the APAN. The period of Subject 4's pretenotomy APAN was 204 s (79 s JL; 12 s N<sub>JL-JR</sub>; 96 s JR; 17 s N<sub>JR-JL</sub>) and at 1 year posttenotomy it decreased 36% to 131 s (63 s JL; 6 s N<sub>JL-JR</sub>; 61 s JR; 1 s N<sub>JR-JL</sub>). Interim values for 1 week, 6 weeks, and 6 months posttenotomy were 201, 177, and 197 s, respectively.

### Direct and Indirect Outcome Measures—NAFX and Acuity

Table 3 shows the relationship between the NAFX-predicted visual acuities and the measured acuities before and 52 weeks after tenotomy. For the two subjects with predicted increases in their potential best-corrected visual acuities, both showed measured increases of one or more Snellen lines; one patient (Subject 2, with retinal dystrophy) showed no changes.

## DISCUSSION

Numerous treatments have been described for INS. These include dietary manipulation, drugs, contact lenses, prisms, biofeedback, intermittent photic stimulation, acupuncture, transcutaneous vibratory or electronic stimula-



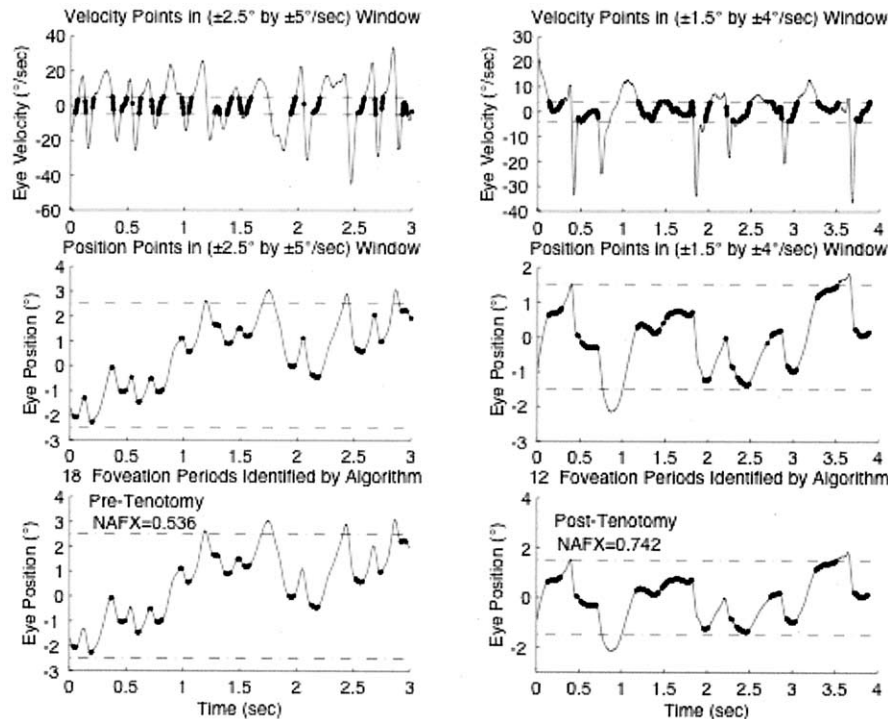
**FIG 1.** Expanded Nystagmus Acuity Function (NAFX) outputs for pre- and postop data from patient 3 (Subject 3). As a result of the tenotomy, the infantile nystagmus (INS) waveforms improved. That is, the duration of the foveation periods increased and their position and velocity variations decreased as is evident from the smaller foveation window required. The net result was an increased NAFX. In this and Figs. 2 and 4, the thickened portions of the tracings correspond to algorithm-identified points falling within the foveation window. The bottom pairs of plots in this and Fig. 2, as well as all plots in Fig. 4, are drawn to the same scale for ease of comparison of the waveforms, foveation periods, and foveation windows.

tion of the face and neck, injection of botulinum toxin, and a variety of surgical procedures (ie, bimedial rectus recession, recession alone, resection alone, rectus transpositions, retroequatorial rectus recessions).<sup>12,19-26</sup> Excepting those treatments that directly improve visual acuity (spectacle and contact lens correction of refractive errors), all these treatments have in common a desired effect of reducing the nystagmus intensity (amplitude  $\times$  frequency) directly or indirectly, allowing for a potential increase in visual acuity. In a review of a total of 361 patients undergoing surgical repositioning of the eyes for congenital nystagmus from 21 reports in which vision was measured both preoperatively and postoperatively, 273 (76%) had improved vision after the surgery.<sup>27</sup> Most of these studies were retrospective reviews and did not use objective eye movement recordings before and after treatment of the nystagmus.

Surgical treatment of nystagmus has a long and well-documented history. Surgery is usually indicated in patients with INS and an anomalous head posture due to an eccentric gaze null position, strabismus, or those who have good binocular function and whose nystagmus decreases and vision improves during convergence (convergence “damping”). There have also been numerous reports of experience with recession of the four horizontal recti for those patients in whom no other surgical indication ex-

ists. Many authors have reported patients in whom surgical repositioning of the extraocular muscles has improved head positioning, nystagmus intensity, and vision.<sup>19,22,28-31</sup> In 1979, Dell’Osso and Flynn examined eye movements with infrared oculography, documenting the effect of this type of procedure on patients with INS.<sup>2,13</sup> They reported the unusual and unpredicted, but beneficial, effects of broadening the null zone, improved foveation in the null zone, and increasing the range of gaze positions over which foveation improved and the nystagmus intensity diminished. There was no ready explanation for these observed effects, which could be related to simply mechanically shifting the positional bias (physically favorable eye position in the orbit) of the eyes. Visual recognition time has also been reported to improve after bilateral horizontal rectus muscle recession surgery for nystagmus.<sup>32</sup>

As Fig. 1 and 2 show, four-muscle tenotomy improved the INS waveforms and, therefore, the potential visual acuities of these patients. There was improvement in Subject 3, who’s pretenotomy NAFX was already very high, mimicking a similar case in Phase 1. The NAFX improvement was immediate (as we documented in the canine model, 1 day post-tenotomy<sup>14</sup> and in the adults in Phase 1 of this study<sup>16</sup>) and was maintained throughout the 1-year duration of the study. Because the same secondary effects of the AK procedure were shown to persist for 5 years,<sup>33</sup>



**FIG 2.** Expanded Nystagmus Acuity Function (NAFX) outputs for pre- and postop data from patient 5 (Subject 5). As a result of the tenotomy, the infantile (INS) nystagmus waveforms improved. That is, the durations of foveation periods increased and their position and velocity varied as is evident from the smaller foveation window required. The net result was an increased NAFX.

we conclude that stability has been reached and the waveforms may be permanently improved.

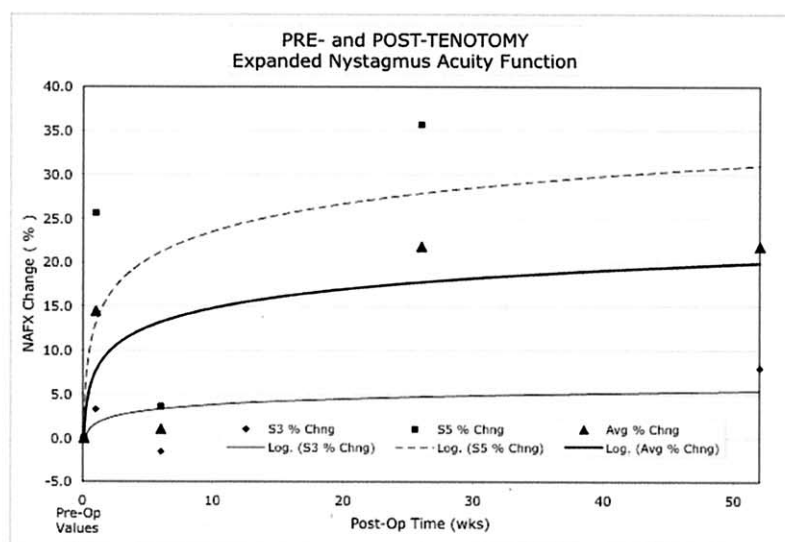
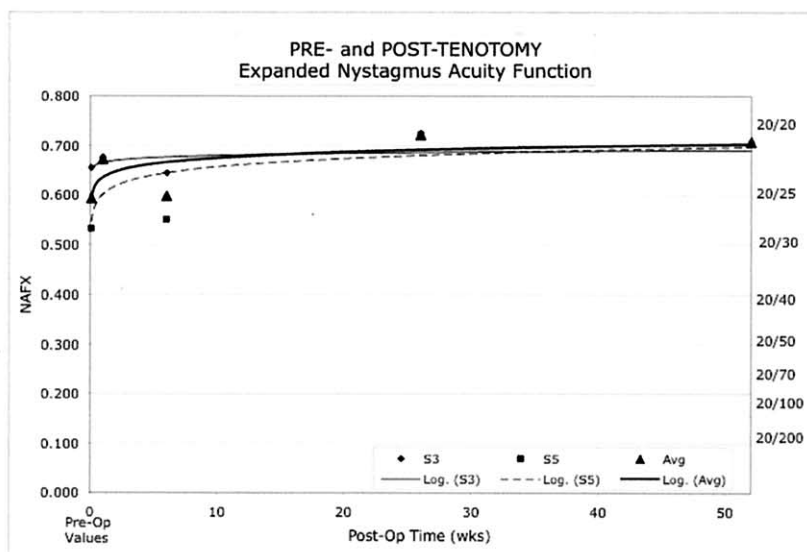
Coincident with the NAFX improvements were increases in average foveation periods of those patients with INS and no APAN. Foveation-period duration improvement was expected and is the primary contributor to improved acuity. Thus, despite variable effects on INS amplitude (which is the primary contributor to cosmetic appearance), tenotomy allowed both patients to achieve waveform improvements that resulted in increases in their NAFX and potential visual acuities.

As illustrated in Table 3, improvements in the outcome measure (NAFX) were tracked by the measured changes in binocular best-corrected acuity visual acuity. The relationship between Snellen visual acuity, nystagmus, and other sensory visual functions is complex and measured visual acuity is usually less than the NAFX-predicted best potential acuity for a given nystagmus waveform but may more closely reflect actual acuity under normal conditions.<sup>18</sup> Both patients' acuities (Subjects 3 and 5) increased in proportion to their NAFX improvements. We conclude that the posttenotomy increases in visual acuity for Subjects 1 and 4 reflected INS waveform improvement similar to that measured by the NAFX in Subjects 3 and 5. We used ocular motility recordings of the nystagmus as the basis for the NAFX outcome measure. Our hypothesis was that the tenotomy surgery would change the nystagmus waveforms in a positive way. The indirect effects on visual

function of improving a patient's nystagmus waveforms are related to a number of unknown, unpredictable, variables including, but not limited to patient age, underlying visual sensory system disease, associated strabismus, associated amblyopia, uncorrected refractive errors, and associated central nervous system disease.

One of the most common features of the INS waveforms is the presence in segments of the slow phase wherein the eyes remain at or close to the point of desired fixation with little or no movement. These foveation periods have been shown to enhance visual acuity. The accuracy and duration of foveation has been directly linked to visual acuity, especially in those INS patients in whom no other sensory system disease can be found.<sup>7,34-38</sup> The possibility of "bilateral amblyopia" is a confounding variable that may explain the lack of improvement in acuity in children with nystagmus who have their nystagmus changed to a visually more favorable oscillation.

One of the goals of our study of the effects of tenotomy on the waveforms of INS was to determine if there were specific waveforms resistant to the damping effects of the procedure. The data from Subject 2 may shed some light on this question. During both the pretenotomy and posttenotomy recording sessions the predominant primary-position waveform was a high-slow-phase-velocity jerk nystagmus with no extended foveation periods; this resulted in low NAFX values. However, occasionally there would appear short intervals of jerk with extended fove-



**FIG 3.** Plots of Expanded Nystagmus Acuity Function (NAFX) values (top) and NAFX percent change (bottom) for two patients (Subject 3 and Subject 5) with INS over the 1-year course of the study. Subjects 3 and 5 = patients 3 and 5 at 0°, Avg = average of patients in each graph, Log = logarithmic curve fits of the NAFX vs. Post-Op Time data.

ation waveforms whose NAFX values were much higher. Fig. 4 illustrates these two waveforms and their respective NAFX values. Because of the large variation, calculated average NAFX values are unrepresentative of pre- or post-tenotomy foveation and potential acuity. Although it appears in this figure that the posttenotomy waveforms had more accurate foveation (less position variation and a smaller foveation window), the predominant high-amplitude jerk waveforms appeared to be unchanged by tenotomy.

Although most of Subject 2's waveforms were high-slow-phase-velocity jerk with little foveation time, there were instances of jerk with extended foveation in primary position. Thus, despite retinal dystrophy, the fixation mechanism was able to occasionally generate long periods of extended foveation; tenotomy appeared to have improved those waveforms.

As we accumulate more patient data demonstrating the effects of tenotomy, we may find that pure jerk waveforms with absent extended foveation periods are more resistant

**TABLE 2.** Visual Acuity Change

Patient No.	Age	VA OU PRE	VA OU POST
1	9	20/60*	20/40‡
2	13	20/60*	20/60‡
3	5	20/50†	20/40‡
4	7	20/40†	20/25‡
5	16	20/50*	20/25‡

VA = visual acuity; OU = both eyes; PRE = pretenotomy; POST = 52 weeks posttenotomy.

\*ETDRS (early treatment diabetic retinopathy) visual acuity testing method.

†ATS HOTV visual acuity testing method.

‡Patients with increased measured visual acuity.

**TABLE 3.** NAFX and Visual Acuity Outcome Measures

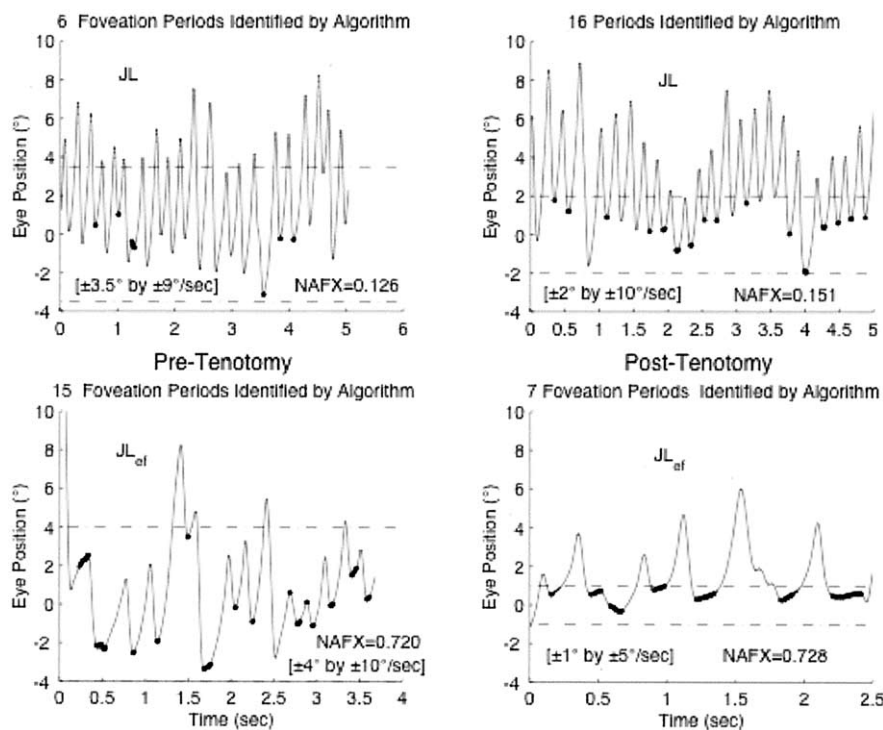
Patient No.	Age	VA OU PRE	NAFX PRE	VA OU POST	NAFX POST
1	9	20/60	*	20/40	*
2	13	20/60	**	20/60	**
3	5	20/50	0.656 (20/25+)	20/40	0.708 (20/20-)
4	7	20/40	*	20/25	*
5	16	20/50	0.532 (20/30+)	20/25	0.722† (20/20)

Binocular visual acuity (VA OU) and average eXpanded Nystagmus Acuity Function (NAFX) values measured before (PRE) and 52 weeks after tenotomy (POST). Values in parentheses are equivalent, best-corrected, potential acuities.

\*Data too poor for reliable calibration (see text).

\*\*Fixation/nystagmus too variable for meaningful average NAFX values (see text).

†Six-month data.



**FIG 4.** Expanded Nystagmus Acuity Function (NAFX) outputs for pre- and postop data from patient 2 (Subject 2) illustrating the large differences between the low NAFX values for the jerk left (JL) waveform (prevalent in this subject) and the high values for the jerk left with extended foveation (JL<sub>ef</sub>) waveform (rare in this subject). For both the pre- and the posttenotomy plots, these intervals occurred within tens of seconds of each other.

to the subtle, but visually important, effects of tenotomy in extending already present foveation periods. If so, that would support the hypothesis that only small-signal plant gain is lowered allowing extended foveation but when there are high slow-phase velocities, they override the damping effect.

There is abundant basic-science and some clinical evidence supporting a hypothesis that central nervous system gain-modulation of the oscillation may be due to afferent changes from the extraocular muscles after the procedure.<sup>14</sup> The primary afferent neurons providing sensory innervation of the mammalian extraocular muscles are located in the

trigeminal ganglion.<sup>39</sup> Afferent fibers from V1 (ophthalmic branch of the trigeminal nerve) either directly connect to or influence brainstem, cerebellar, and cortical areas associated with eye-movement control.<sup>40,41</sup> Recently discovered nerve endings in the extraocular muscles at the tendino-scleral interface (its “enthesis”) may shed light on a further mechanism of action of tenotomy surgery.<sup>42</sup>

Given these numerous studies, it is likely that afferent information from the extraocular muscles (either as proprioceptive signals or as other sensory information) serves as a continuous and long-term calibration signal. The underlying pathophysiology of infantile nystagmus syn-



drome has been attributed to and modeled as a high-gain instability in the pursuit system.<sup>43,44</sup> The clinical and electrophysiological consequences of extraocular muscle tenotomy in patients with INS may be due to interruption of the afferent proprioceptive loop, producing a damped *peripheral* ocular-motor response to the small, unchanged nystagmus signal—the small-signal gain of the ocular motor plant is effectively reduced.

Both phases of this study provided some evidence that tenotomy could affect the periods of some patients' APAN. At present, the data are too sparse to determine if the effects observed were idiosyncratic changes subsequent to tenotomy or simply reflected the known variability of APAN cycles in the INS; Subject 4's data suggest the latter.

In conclusion, we have now demonstrated in this study 4 of 5 children, and our previous study, 9 of 10 adult patients, with wide clinical and oculographic variations in their INS, four-muscle tenotomy resulted in improvements in their nystagmus along with improvements in visual acuity. We are currently evaluating the effects of different combinations of two-muscle tenotomy procedures as part of combined nystagmus and strabismus surgery.

#### References

1. Hertle RW. A next step in naming and classification of eye movement disorders and strabismus. *J AAPOS* 2002;6(4):201-2.
2. Dell'Osso LF, Flynn JT. Congenital nystagmus surgery: a quantitative evaluation of the effects. *Arch Ophthalmol* 1979;97:462-9.
3. Gradstein L, Reinecke RD, Wizov SS, Goldstein HP. Congenital periodic alternating nystagmus. Diagnosis and management. *Ophthalmology* 1997;104(6):918-28; discussion 28-9.
4. Abadi RV. Visual performance with contact lenses and congenital idiopathic nystagmus. *Br J Physiol Opt* 1979;33(3):32-7.
5. Sheth NV, Dell'Osso LF, Leigh RJ, Van Doren CL, Peckham HP. The effects of afferent stimulation on congenital nystagmus foveation periods. *Vision Res* 1995;35(16):2371-82.
6. Leigh RJ, Dell'Osso LF, Yaniglos SS, Thurston SE. Oscillopsia, retinal image stabilization and congenital nystagmus. *Invest Ophthalmol Vis Sci* 1988;29(2):279-82.
7. Dell'Osso LF, van der Steen J, Steinman RM, Collewijn H. Foveation dynamics in congenital nystagmus. I: Fixation. *Doc Ophthalmol* 1992;79(1):1-23.
8. Dell'Osso LF, van der Steen J, Steinman RM, Collewijn H. Foveation dynamics in congenital nystagmus. II: Smooth pursuit. *Doc Ophthalmol* 1992;79(1):25-49.
9. Dell'Osso LF, van der Steen J, Steinman RM, Collewijn H. Foveation dynamics in congenital nystagmus. III: Vestibulo-ocular reflex. *Doc Ophthalmol* 1992;79(1):51-70.
10. Bedell HE, White JM, Abplanalp PL. Variability of foveations in congenital nystagmus. *Clin Vision Sci* 1989;4:247-52.
11. Kestenbaum A. Nouvelle operation de nystagmus. *Bull Soc Ophthalmol Fr* 1953;6:599-602.
12. Anderson JR. Causes and treatment of congenital eccentric nystagmus. *Br J Ophthalmol* 1953;37:267-81.
13. Flynn JT, Dell'Osso LF. The effects of congenital nystagmus surgery. *Ophthalmology* 1979;86(8):1414-27.
14. Dell'Osso LF, Hertle RW, Williams RW, Jacobs JB. A new surgery for congenital nystagmus: effects of tenotomy on an achiasmatic canine and the role of extraocular proprioception. *J AAPOS* 1999;3:166-82.
15. Dell'Osso LF, Williams RW, Jacobs JB, Erchul DM. The congenital and see-saw nystagmus in the prototypical achiasma of canines: comparison to the human achiasmatic prototype. *Vision Res* 1998;38(11):1629-41.
16. Hertle RW, Dell'Osso LF, FitzGibbon EJ, Thompson D, Yang D, Mellow SD. Horizontal rectus tenotomy in patients with congenital nystagmus: results in 10 adults. *Ophthalmology* 2003;110(11):2097-105.
17. Moke PS, Turpin AH, Beck RW, Holmes JM, Repka MX, Birch EE, Hertle RW, Kraker RT, Miller JM, Johnson CA. Computerized method of visual acuity testing: adaptation of the amblyopia treatment study visual acuity testing protocol. *Am J Ophthalmol* 2001;132(6):903-9.
18. Dell'Osso LF, Jacobs JB. An expanded nystagmus acuity function: intra- and intersubject prediction of best-corrected visual acuity. *Doc Ophthalmol* 2002;104:249-76.
19. Calhoun JH, Harley RD. Surgery for abnormal head position in congenital nystagmus. *Trans Am Ophthalmol Soc* 1973;71:70-83.
20. Carlow TJ. Medical treatment of nystagmus and ocular motor disorders. *Int Ophthalmol Clin* 1986;26(4):251-64.
21. Blekher T, Yamada T, Yee RD, Abel LA. Effects of acupuncture on foveation characteristics in congenital nystagmus. *Br J Ophthalmol* 1998;82(2):115-20.
22. Cooper EL, Sandall GS. Surgical treatment of congenital nystagmus. *Arch Ophthalmol* 1969;81(4):473-80.
23. Helveston EM, Ellis FD, Plager DA. Large recession of the horizontal recti for treatment of nystagmus. *Ophthalmology* 1991;98(8):1302-5.
24. Kirschen DG. Auditory feedback in the control of congenital nystagmus. *Am J Optom Physiol Opt* 1983;60(5):364-8.
25. Mallett RF. The treatment of congenital idiopathic nystagmus by intermittent photic stimulation. *Ophthalmic Physiol Opt* 1983;3(3):341-56.
26. Reinecke RD. Retroequatorial placement of horizontal recti. *J Pediatr Ophthalmol Strabismus* 1996;33(3):201-2.
27. Hertle RW, Dell'Osso LF, FitzGibbon EJ, Thompson D, Yang D, Mellow SD. Protocol 99-El-0152: horizontal rectus tenotomy in the treatment of congenital nystagmus. The National Eye Institute, National Institutes of Health, Intramural Research Protocols 1999: 1-85.
28. Goto K, Muranushi Y. Treatment of nystagmus present in the change of head positions-use of ATP. *Jibiinkoka* 1967;39(8):879-90.
29. Parks MM. Symposium nystagmus. Congenital nystagmus surgery. *Am Orthop J* 1973;23:35-9.
30. Pratt-Johnson JA. Results of surgery to modify the null-zone position in congenital nystagmus. *Can J Ophthalmol* 1991;26(4): 219-23.
31. Nelson LB, Wagner RS, Harley RD. Congenital nystagmus surgery. *Int Ophthalmol Clin* 1985;25(4):133-8.
32. Helveston EM, Neely DF, Stidham DB, Wallace DK, Plager DA, Sprunger DT. Results of early alignment of congenital esotropia. *Ophthalmology* 1999;106(9):1716-26.
33. Flynn JT, Dell'Osso LF. Surgery of congenital nystagmus. *Trans Ophthalmol Soc UK* 1981;101:431-3.
34. Dell'Osso LF. Fixation characteristics in hereditary congenital nystagmus. *Am J Optom Arch Am Acad Optom* 1973;50:85-90.
35. Dell'Osso LF, Daroff RB. Congenital nystagmus waveforms and foveation strategy. *Doc Ophthalmol* 1975;39:155-82.
36. Gresty M, Halmagyi GM, Leech J. The relationship between head and eye movement in congenital nystagmus with head shaking: objective recordings of a single case. *Br J Ophthalmol* 1978;62(8):533-5.
37. Gottlob I, Wizov SS, Reinecke RD. Quantitative eye and head movement recordings of retinal disease mimicking spasmus nutans. *Am J Ophthalmol* 1995;119(3):374-6.
38. Gradstein L, Goldstein HP, Wizov SS, Hayashi T, Reinecke RD. Relationships among visual acuity demands, convergence, and nys-

- tagmus in patients with manifest/latent nystagmus. J AAPOS 1998;2(4):218-29.
39. Buttner-Ennever JA, Cohen B, Horn AK, Reisine H. Pretectal projections to the oculomotor complex of the monkey and their role in eye movements. J Comp Neurol 1996;366(2):348-59.
  40. Eisenman LM, Sieger DD, Blatt GJ. The olivocerebellar projection to the uvula in the mouse. J Comp Neurol 1983;221(1):53-9.
  41. Kimura M, Takeda T, Maekawa K. Contribution of eye muscle proprioception to velocity-response characteristics of eye movements: involvement of the cerebellar flocculus. Neurosci Res 1991; 12(1):160-8.
  42. Hertle RW, Chan C, Galita DA, Maybodi M, Crawford MA. Neuroanatomy of the extraocular muscle tendon enthesis In macaque, normal human and patients with congenital nystagmus. J AAPOS 2002;6:319-27.
  43. Dell'Osso LF. A hypothetical fixation system capable of extending foveation in congenital nystagmus. J Neuroophthalmol 2002;22: 185-6.
  44. Jacobs JB. An ocular motor system model that simulates congenital nystagmus, including braking and foveating saccades. (Ph.D. Dissertation). In: Biomedical Engineering. Cleveland, OH: Case Western Reserve University. 2001.



### An Eye on the Arts – The Arts on the Eye

In bed, leaning back, I open Linda Gregg's book.  
 A razor-sharp bookmark flips out, slicing my one reading eye.  
 I leap up, wheeling, clutching my face. I've sliced open my eye, my only workable eye!

I lurch to the bathroom and vomit. There are strobe lights in my skull. A lightning-streaked tree blazes in the back of my stabbed eye.  
 I bang my shins on the unfamiliar furniture.  
 This is the kind of pain known to torturers. What am I to do? I don't know a soul in town.  
 My entire fabricated being is gone. Instantly.  
 In the kitchen I vomit into the sink. Grab wet towels and press them to my eye.  
 All night I sit in a rocking chair. My eyes dart about uncontrollably.  
 I know I should call an ambulance. Instead I rock back and forth, reciting parts of poems silently.  
 "Only brooms know the devil still exists." (Charles Simic)  
 "When I went out to kill myself/I caught a pack of hoodlums beating up a man." (James Wright)  
 The chair rocks and squeaks.  
 When daylight comes, I telephone the Colonel, my landlord. He agrees to drive me to the hospital.  
 There I lie in a darkened room, alone on a gurney for four hours. These four hours offer a return to childhood: I listen to unfamiliar voices, the click of women's shoes in the halls, the talk of strangers.  
 When the doctor finally comes in, I begin to babble. "Good eye . . . legally blind . . . birth defect . . . too much oxygen . . ." He, however, is brisk, uncommunicative. He puts a salve in my eye and says that the wound should heal in a few days. He covers it with a bandage, then disappears.  
 "You're free to go," says the nurse.  
 I never get the chance to tell him that bandaged in this way, I can't see a thing.  
 —Stephen Kuusisto (from *Planet of the Blind*)