

Latent Nystagmus and Acquired Pendular Nystagmus Masquerading as Spasmus Nutans

Jaecil I. Kim, MD, PhD, Louis F. Dell'Osso, PhD, and Elias Traboulsi, MD

Abstract: We used ocular motility recordings to identify the characteristics of a rare combination of conjugate, horizontal jerk, and pendular nystagmus in a 9-year-old boy. The clinical diagnoses were amblyopia, left esotropia, congenital nystagmus, and an apparently uniocular pendular nystagmus that mimicked spasmus nutans. Ocular motility recordings revealed an unusual latent/manifest latent nystagmus, pendular nystagmus with characteristics of an acquired nystagmus, and uniocular saccades. The ocular motor data identified clinically unrecognized types of nystagmus and suggested that the pendular nystagmus was acquired in infancy rather than as a result of failure to develop good vision or binocularity. The presence of uniocular saccades adds to the mounting evidence that individual control for each eye exists in humans.

(J Neuro-Ophthalmol 2003;23: 198–203)

Complex ocular motor cases often present the clinician with a diagnostic puzzle whose multiple, sometimes-contradictory signs require ocular motility recordings to solidify diagnosis. Analysis of the data from such cases may also provide insight into the organization of the ocular motor system.

In this study, we describe a patient with a rare combination of latent/manifest latent nystagmus (LMLN) and a reversed Alexander law variation, together with apparently uniocular pendular nystagmus and uniocular saccades. In

doing so, we address the following questions: 1) Is the nystagmus the result of failure to develop normal binocular vision? 2) Is the nystagmus worse in the amblyopic eye? 3) Is a visual acuity better than 20/100 required to prevent the development of pendular nystagmus and to preserve the strong yoking needed to ensure conjugate eye movements? We also present data-driven diagnoses, therapeutic recommendations, and support for the hypothesis of uniocular motor control (1).

We use the term LMLN to include both latent nystagmus (nystagmus evoked by having one eye occluded) and manifest latent nystagmus (nystagmus present with both eyes open, one fixating and the other suppressed) (2). Regardless of viewing condition, the linear or decelerating slow phases of both eyes are in the nasal direction of the fixating eye and the fast phases in the temporal direction (2,3). We use the term congenital nystagmus (CN) to mean a conjugate nystagmus with characteristic pendular or jerk waveforms that are not normally related to strabismus or to the fixating eye (4). CN may have a superimposed “latent component” but the waveforms remain those of CN.

CASE REPORT

Clinical Features

The patient, a boy, was the product of a 32-week gestation with a small subarachnoid hemorrhage noted by lumbar puncture performed in the nursery. A neurologic evaluation at the age of 4 months disclosed intermittent left fisting and mild head lag. At 12 months, he showed slight delay in cognitive and motor skills. He had developed an alternating esophoria at 18 months, and exhibited minor developmental and motor delay. Apart from intermittent left fisting, his neurologic examination was normal. At 30 months, dissociated pendular nystagmus (left eye greater than right eye) was diagnosed as spasmus nutans; jerk nystagmus was diagnosed as congenital. An intermittent left head tilt was noted at age 2 years.

On our initial examination at age 9 years, visual acuity was 20/30 right eye and 20/100 left eye. An esotropia of 25 prism-diopters was noted. There was a conjugate, horizontal jerk-right nystagmus with a left face turn and a constant, apparently uniocular, horizontal pendular nystagmus in the left eye that was clinically compatible with spas-

From the Ocular Motor Neurophysiology Laboratory (JIK, LFD), Veterans Affairs Medical Center; the Department of Neurology (LFD), Case Western Reserve University and University Hospitals of Cleveland; Cleveland, Ohio; the Department of Neurology, Dankook University, Cheonan, Korea (JIK); and the Department of Pediatric Ophthalmology and Strabismus, Cleveland Clinic, Cleveland, Ohio (ET).

Reprints: L. F. Dell'Osso, Ocular Motor Neurophysiology Laboratory, Veterans Affairs Medical Center (127A), 10701 East Boulevard, Cleveland, OH 44106. E-mail: lfd@po.cwru.edu

Supported in part by the Office of Research and Development, Medical Research Service, Department of Veterans Affairs (L. F. Dell'Osso) and Korea Research Foundation, Support for Faculty Research Abroad (J. I. Kim).

mus nutans. He had bilateral dissociated vertical deviations (DVD) more prominent in the right eye. There was significant bilateral overaction of the inferior oblique muscles. A left face turn was present when he fixated on a distant target. Using the Titmus test, we confirmed that there was no stereopsis. He reported no oscillopsia.

Testing Methods

Horizontal eye movement recordings were made using infrared reflection (Applied Scientific Laboratories, Waltham, MA). In the horizontal plane, the system was linear to $\pm 20^\circ$ and monotonic (i.e., no reversal) to $\pm 25\text{--}30^\circ$ with a saturating characteristic. The sensitivity was 0.25° . The infrared signal from each eye was calibrated with the other eye behind cover to obtain accurate position information and to document small tropias and phorias hidden by the nystagmus. Eye positions and velocities (obtained by analog differentiation of the position channels) were displayed on a strip chart recording system (Beckman Type R612 Dynograph). The total system bandwidth (position and velocity) was 0–100 Hz. The data were digitized at 500 Hz with 16-bit resolution.

Written consent was obtained from the patient's parent before the testing. All test procedures were carefully explained to the patient before the experiment began and were reinforced with verbal commands during the trials. The patient was seated in a chair with headrest and a chin stabilizer, 5 feet from an arc of red light-emitting diodes (LEDs) to prevent convergence effects. At this distance, the LED subtended less than 0.1° of visual angle. The room light could be adjusted from dim down to blackout to minimize extraneous visual stimuli. Trials were kept short to guard against boredom because CN intensity is known to decrease with inattention.

Data Analysis

Data analysis (and filtering, if required) and graphical presentation were performed using MATLAB (The MathWorks, Natick, MA) software for scientific computing.

RESULTS

Nystagmus Waveforms and Directions

Ocular motility recordings did not contain the typical CN waveforms previously identified (4). Figure 1 shows the waveforms during fixation in primary position of the right (Fig. 1A) and left eye (Fig. 1B) during LN (one eye occluded) and of the right eye (Fig. 1C) during MLN (both eyes viewing). The waveforms were jerk and dual jerk with linear or decelerating slow phases; these are the waveforms of LMLN. When recorded during monocular fixation (one eye occluded), the direction of the jerk nystagmus was always towards the fixating eye and, during binocular viewing, the direction was also always towards the fixating eye,

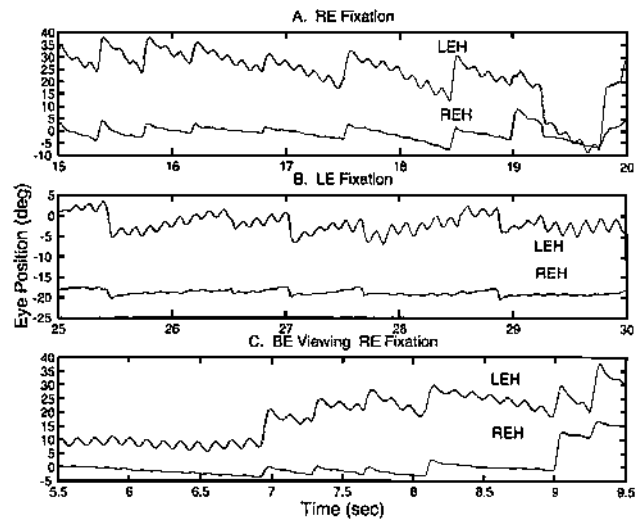


FIG. 1. Infrared eye movement recording. There is horizontal, dual jerk nystagmus of both eyes in primary position with right eye fixation (A) and left eye fixation (B) during monocular viewing, and with right eye fixation (C) during binocular viewing. In each case, the jerk nystagmus is in the direction of the fixating eye, a characteristic of latent/manifest latent nystagmus (LMLN). REH, right eye horizontal; LEH, left eye horizontal; us, uniocular saccade; rightward eye movements are positive. Figures 1 and 3–6 show intervals from 30-second records. BE = both eyes.

with the other eye in an esotropic position (25 PD). As this and the following figures show, the fast phases of the LMLN in the two eyes were often dissociated.

Nystagmus Variation With Gaze Angle

Figure 2 shows the variation of the LMLN as the fixating right eye is directed laterally to the right (Fig. 2A) and left (Fig. 2B). The LMLN slow-phase velocity and amplitude decreased (while the esotropia remained constant) as gaze was directed to the right while the right eye was fixating the targets. Even in far-left gaze, when the esotropia of the left eye diminished (damping the LMLN amplitude), the right eye remained the fixating eye and the LMLN direction remained jerk right.

Interocular Phase of Pendular Nystagmus

Recordings documented that the pendular nystagmus that appeared clinically as “uniocular” was, in fact, present in both eyes but greater in the left eye. As Figure 1 shows, changing the fixating eye did not alter the 8-Hz pendular component of the nystagmus; it remained 6–10 times greater in the left eye. Expanded time scale intervals of the pendular nystagmus in both eyes revealed interocular phase differences of either 45° or 135° . Figure 3 shows an interval of 2 LMLN cycles (15 pendular cycles) in which the in-

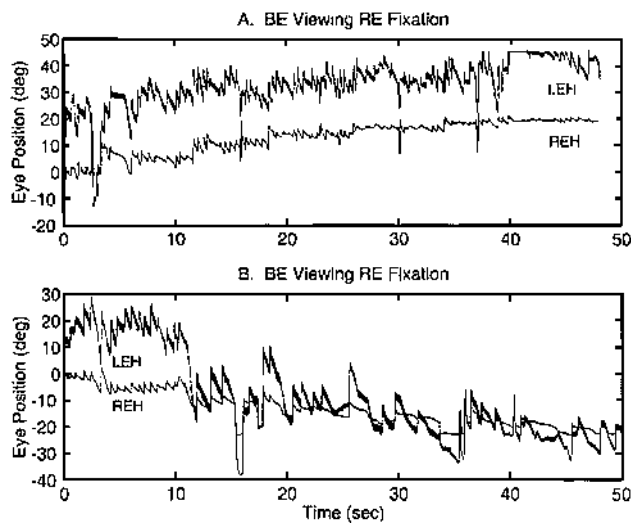


FIG. 2. Infrared eye movement recording. This shows variation of the nystagmus with gaze to the right (A) and left (B) with right eye fixation during binocular viewing and the left eye in an esotropic position, except for far left gaze angles. The increase in nystagmus as the fixating eye abducts is a reversal of the Alexander law variation usually seen in LMLN.

terocular phase shift of the pendular nystagmus was 45° (the fixating right eye was leading the left).

Saccade and Fast-Phase Damping of Pendular Nystagmus

Prominent throughout the recordings were periods of transient damping of the pendular nystagmus immediately

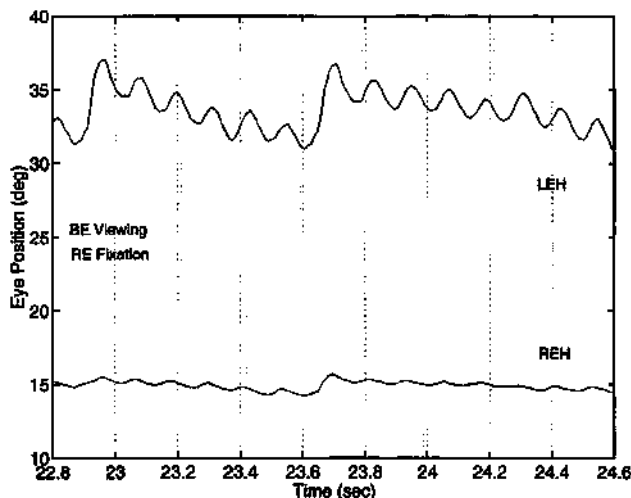


FIG. 3. Infrared eye movement recording. This provides an expanded view of two cycles of dual jerk LMLN of both eyes, showing an interocular phase shift in the pendular nystagmus of 45° (right eye leading). This finding suggests that the pendular oscillations in each eye were generated independently.

after voluntary saccades and, in some cases, after nystagmus fast phases. Figure 4 demonstrates the transient damping of the pendular nystagmus after voluntary saccades (A) and some fast phases (B). Voluntary saccades in the direction of jerk nystagmus fast phases (s1, s3, and s4) and opposite to them (s2) damped the pendular nystagmus transiently. The damping is more easily seen in the variation of the velocity trace.

Dissociated and Uniocular Saccades

The patient exhibited dissociated (unequal amplitude), convergent, divergent, and occasional uniocular saccades in addition to normal, conjugate saccades (i.e., saccades with normal peak velocity- and duration-amplitude relationships). Square-wave jerks were common; some were disconjugate or uniocular. The uniocular saccades and square-wave jerks appeared in the fixating right eye during fixation of a stationary LED target; none were seen in the deviated left eye. The rightward saccade at 19 seconds in Figure 1A was greater in the right eye but the leftward saccade at 19.3 seconds was greater in the left eye. The rightward saccade that followed at 19.8 seconds was so dissociated (much greater in the left eye) that it was almost uniocular. Figure 5 shows the eye position, velocity, acceleration, and jerk (the third derivative of position) (5) of both eyes during divergent, convergent, and dissociated saccades. Figure 6 shows the same data for a truly uniocular

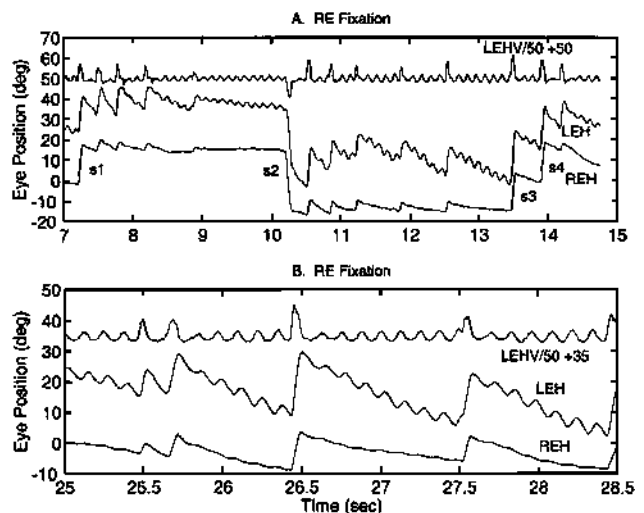


FIG. 4. Infrared eye movement recording. This shows transient damping of the pendular component of the dual jerk nystagmus after voluntary saccades (A) and some fast phases (B). Saccadic damping of pendular nystagmus suggests it is acquired. LEHV/50 + # is the left-eye velocity divided by 50 and shifted by the amount shown (for clarity). 500°/s is equivalent to 10° on the y-axis; s# indicates voluntary saccades.

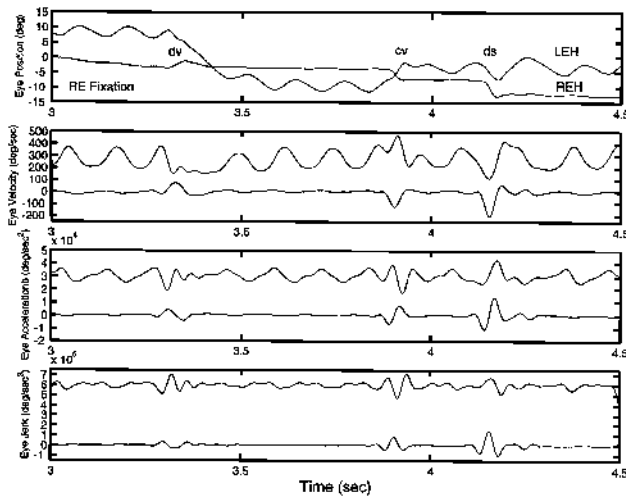


FIG. 5. Infrared eye movement recording. Eye position, velocity, acceleration, and jerk recordings from both eyes show that a divergent (dv) saccade is followed by convergent (cv) and dissociated (ds) saccades. The rapid deflections in the velocity, acceleration, and jerk data of both eyes confirm these simultaneous, albeit disjunctive, saccades. In this and Figure 6, the nonfixating left eye velocity, acceleration, and jerk data have been offset upwards for clarity.

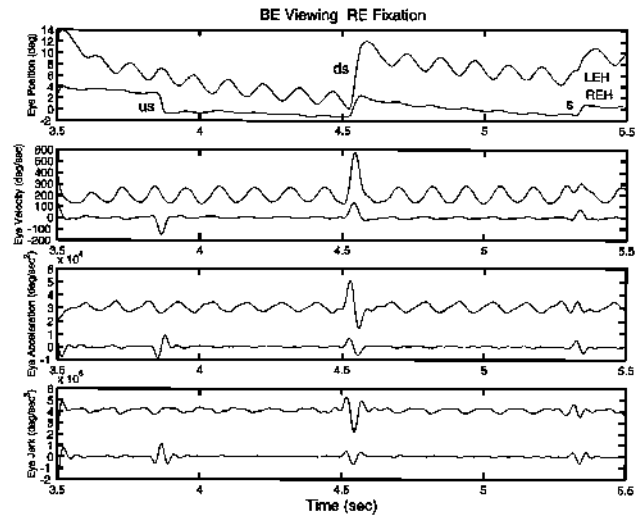


FIG. 6. Infrared eye movement recording. Eye position, velocity, acceleration, and jerk recordings from both eyes show that a uniocular saccade (us) is followed by dissociated (ds) and conjugate (s) saccades. The absence of rapid deflections in the left eye velocity, acceleration, and jerk data verify that the leftward saccade in the right eye is uniocular. This is in contrast to the deflections seen in the velocity, acceleration, and jerk data of both eyes for the ds and s saccades.

leftward saccade (us), recorded from the fixating right eye, that exhibited saccadic duration, peak velocity, acceleration, and jerk. The uniocular saccade was followed by a conjugate saccade. As the top two panels in Figure 6 show, this 4° saccade had a peak velocity of 150°/s, which is normal for our laboratory. The patient's conjugate saccades also met normal criteria, regardless of when in the cycle of the pendular nystagmus they occurred. Uniocular square-wave jerks also were recorded.

DISCUSSION

It is sometimes difficult to differentiate the subtle slow-phase characteristics of LMLN, CN, and combinations of the two (3). In this case, the positive alternate-cover test would have suggested LMLN, but only eye movement recordings could differentiate LMLN from CN with a latent component; the latter is much more common than LMLN.

Ocular motility recordings of the patient's nystagmus demonstrated that it was actually LMLN with linear and decreasing velocity slow phases, despite a clinical picture of CN with a head turn and spasmus nutans (6). Monocular occlusion resulted in the direction of the jerk nystagmus switching to that of the fixating eye. There were no characteristic CN waveforms, although the presence of a conjugate, high-frequency pendular nystagmus superimposed on the jerk is common in both CN and LMLN.

The fixating eye in LMLN usually obeys Alexander law (3) and, in a similar manner, the amplitude of jerk CN

increases as gaze is deviated away from the null angle. That is, jerk-right CN increases with rightward gaze and jerk-left CN increases with leftward gaze. Because of this, patients with LMLN commonly adopt a head turn or, if they alternate their fixating eye, two head turns. The head turn places the fixating eye in adduction, where the slow-phase velocity and the nystagmus are minimal. However, recordings of this patient's LMLN variation with gaze angle (Fig. 2) revealed damping with abduction of the fixating right eye, opposite to that predicted by Alexander law. That is, it was a reversed Alexander law variation. It was this phenomenon that accounted for the left head turn—not a CN null angle. A reversed Alexander law has been reported in some cases of LMLN (3).

The DVD in this patient was greater in the right eye, which was the preferred eye for fixation. Because only one eye is used for fixation in LMLN, the DVD has no effect on visual acuity. There is no diplopia because vision in the deviated eye is suppressed. The damped LMLN in right gaze was preferred for the increased acuity it allowed.

This patient's pendular nystagmus differed from that in the dual jerk waveforms of either CN or LMLN (7). First, it was dissociated (much greater in the left eye than in the right) and did not change with fixation; in CN and LMLN, the pendular nystagmus is conjugate. Second, it was transiently damped by voluntary saccades and fast phases, a feature that does not occur in CN or LMLN. The pendular

nystagmus of spasmus nutans usually has a variable phase shift between the two eyes but is unaffected by saccades; this patient's interocular phase shift was either 45° or 135°. The eye movement data identified this as a nystagmus with the same characteristics as an acquired pendular nystagmus, consistent with other patients with acquired pendular nystagmus that we have recorded. We believe it improbable that this was the first recorded case of dual-jerk LMLN whose pendular component was damped by saccades. Also, the high frequency precluded oculopalatal myoclonus.

Based on our ocular motor diagnoses, we recommended an Anderson-Kestenbaum procedure to rotate both eyes to the left with an additional leftward rotation of the left eye. This would shift the low-nystagmus region towards primary position and correct the esotropia.

It is unique to have recorded dissociated, divergent, convergent, and uniocular saccades in a patient whose other ocular motor behavior is also unusual. It appears that the normally strong yoking seen in humans, even those with strabismus, has been weakened sufficiently in this patient to reveal an innate ability in humans to make uniocular saccades, that is, to fire only the burst cells to the agonist extraocular muscle of one eye. Because these saccades appeared in a subject with strabismus during fixation of an LED with no vergence stimuli, it is unlikely that they were due to superimposed vergence signals.

Uniuocular saccades can be made by canines and humans (both are binocular mammals) (8–10). Thus, the current putative neuroanatomy whereby a single pool of burst neurons drives both eyes for ipsilateral saccades is, at best, inadequate and possibly incorrect. For that schema, one might speculate that the signal to the contralateral medial rectus could be blocked by inhibition at the level of the ipsilateral internuclear neurons in the region of the ipsilateral abducens motoneurons. That schema would allow an ipsilateral, uniocular, *abducting* saccade. However, the uniocular saccade shown in Figure 6 is an *adducting* saccade. Therefore, the ipsilateral internuclear neurons must have fired, innervating the contralateral oculomotor neurons via the MLF, with concurrent inhibition of the ipsilateral abducens motoneurons. Another possibility is that the uniocular saccades resulted from vergence burst neurons. These neurons fire during combined version–vergence refixations. However, it is unclear why vergence burst neurons specific to the fixating right eye's medial rectus would fire during fixation of a stationary LED target. The most parsimonious hypothesis is that each pool of burst neurons is made up of two subgroups, one specific for the ipsilateral abducens, the other for the contralateral oculomotor neurons (1). Recent evidence from the study of burst cells in monkeys supports the latter hypothesis (11–15). In cases of binocularity, a yoking mechanism coordinates the firing of

both subgroups of burst cells so that conjugate saccades result. However, when binocularity is compromised, as in strabismus or achiasma, the yoking mechanism is weakened, allowing dissociated or uniocular saccades, consistent with an underlying uniocular architecture.

In our patient, the apparent uniocular pendular nystagmus exhibited the characteristics of an acquired, dissociated pendular nystagmus, perhaps caused by the subarachnoid hemorrhage in the neonatal period. Acquired pendular nystagmus is one of the more common types of nystagmus (16–18). Its pathogenesis remains unclear, and more than one mechanism may be responsible for its occurrence (19). High-frequency pendular nystagmus is known to accompany LMLN and CN, and may be associated with poor vision. Tusa et al. (20–22) studied the pendular nystagmus induced in monkeys reared using several occlusion paradigms. These authors concluded that this high-frequency pendular nystagmus was similar to that seen in CN and LMLN in humans. Their studies localized this nystagmus to the nucleus of the optic tract (NOT). Therefore, the pendular nystagmus sometimes seen superimposed on classic CN and LMLN waveforms (dual jerk and dual jerk latent waveforms) is possibly due to instability in NOT circuitry. The relationship between acuity and the development of *binocular* pendular nystagmus in more common cases of LMLN, DVD, strabismus, and amblyopia has not been adequately studied. Thus, there is a possibility that this patient's pendular nystagmus is a disconjugate variant of the NOT-produced pendular nystagmus.

Acknowledgments

We are grateful to Dr. Brian Mohny for allowing us the opportunity to study this unusual patient.

REFERENCES

1. Dell'Osso LF. Evidence suggesting individual ocular motor control of OU (muscle). *J Vestib Res* 1994;4:335–45.
2. Dell'Osso LF, Traccis S, Abel LA. Strabismus—a necessary condition for latent and manifest latent nystagmus. *Neuroophthalmology* 1983;3:247–57.
3. Dell'Osso LF, Schmidt D, Daroff RB. Latent, manifest latent and congenital nystagmus. *Arch Ophthalmol* 1979;97:1877–85.
4. Dell'Osso LF, Daroff RB. Congenital nystagmus waveforms and foveation strategy. *Doc Ophthalmol* 1975;39:155–82.
5. Wyatt HJ. Detecting saccades with jerk. *Vision Res* 1998;38:2147–53.
6. Weissman BM, Dell'Osso LF, Abel LA, et al. Spasmus nutans: a quantitative prospective study. *Arch Ophthalmol* 1987;105:525–8.
7. Dell'Osso LF. Congenital, latent and manifest latent nystagmus—similarities, differences and relation to strabismus. *Jpn J Ophthalmol* 1985;29:351–68.
8. Dell'Osso LF, Williams RW. Ocular motor abnormalities in achiasmic mutant Belgian sheepdogs: Unyoked eye movements in a mammal. *Vision Res* 1995;35:109–16.
9. Dell'Osso LF, Williams RW, Jacobs JB, et al. The congenital and see-saw nystagmus in the prototypical achiasma of canines: comparison to the human achiasmic prototype. *Vision Res* 1998;38:1629–41.

10. Dell'Osso LF, Hogan D, Jacobs JB, et al. Eye movements in canine hemichiasma: does human hemichiasma exist? *Neuro-ophthalmology* 1999;22:47–58.
11. King WM, Mays LE, Paige GD, et al. Symposium. Binocular coordination of eye movements. *Soc Neurosci Abstr* 1997;23:1937.
12. King WM, Zhou W. An ocular selectivity model of eye movement control: implications for strabismus. *Soc Neurosci Abstr* 1997;23:1559.
13. Zhou W, King WM. Monocular rather than conjugate saccade burst generators in paramedian pontine reticular formation (PPRF). *Soc Neurosci Abstr* 1997;23:7.
14. Zhou W, King WM. Premotor commands encode monocular eye movements. *Nature* 1998;393:692–5.
15. King WM, Zhou W. New ideas about binocular coordination of eye movements: Is there a chameleon in the primate family tree? *Anat Rec (New Anat)* 2000;261:153–61.
16. Gresty MA, Ell JJ, Findley LJ. Acquired pendular nystagmus: its characteristics, localising value and pathophysiology. *J Neurol Neurosurg Psychiatry* 1982;45:431–9.
17. Barton JJ, Cox TA. Acquired pendular nystagmus in multiple sclerosis: clinical observations and the role of optic neuropathy. *J Neurol Neurosurg Psychiatry* 1993;56:262–7.
18. Barton JJ. Is acquired pendular nystagmus always phase locked? *J Neurol Neurosurg Psychiatry* 1994;57:1263–4.
19. Leigh RJ, Zee DS. *The Neurology of Eye Movements, Edition 3 (Contemporary Neurology Series)*. New York: Oxford University Press; 1999:1–646.
20. Tusa RJ, Mustari MJ, Burrows AF, et al. Gaze-stabilizing deficits and latent nystagmus in monkeys with brief, early-onset visual deprivation: eye movement recordings. *J Neurophysiol* 2001;86:651–61.
21. Mustari MJ, Tusa RJ, Burrows AF, et al. Gaze-stabilizing deficits and latent nystagmus in monkeys with brief, early-onset visual deprivation: role of the pretectal NOT. *J Neurophysiol* 2001;86:662–75.
22. Tusa RJ, Mustari MJ, Das VE, et al. Animal models for visual deprivation-induced strabismus and nystagmus. *Ann NY Acad Sci* 2002;956:346–60.