

Research report



Neuro-Ophthalmology
0165-8107/02/US\$16.00

Neuro-Ophthalmology – 2002, Vol. 25,
No. 3, pp. ■■–■■
© Swets & Zeitlinger 2002

Accepted 7 November 2001

Clinical, radiographic, and electrophysiologic findings in patients with achiasma or hypochiasma

Richard W. Hertle¹

Louis F. Dell'Osso²

Edmond J. FitzGibbon¹

Rafael C. Caruso³

John Butman⁴

Dongsheng Yang¹

Susan D. Mellow¹

¹The Laboratory of Sensorimotor Research and ³Ophthalmic Genetics and Clinical Services Branch, The National Eye Institute, and ⁴The Diagnostic Radiology Department, The National Institutes of Health, Bethesda, MD, and ²The Department of Neurology, Case Western Reserve University and The VA Medical Center, Cleveland, OH, USA

The authors have no proprietary interest in any equipment used in the analysis of these patients.

Abstract *Objective:* To report the clinical, electrophysiologic, and radiographic analysis of four patients presenting with nystagmus and diagnosed with achiasma or hypochiasma and summarize all 11 patients reported with this syndrome. *Methods:* Each patient underwent complete ophthalmologic examination, fundus photography, ocular motor recordings (OMR), visual evoked potentials (VEP), visual field testing (VFT), and magnetic resonance imaging (MRI) of the optic pathways. *Results:* Reduced vision, strabismus, optic nerve dysplasia, congenital nystagmus (CN), and see-saw nystagmus were present in all patients. One of these four patients had congenital hydrocephalus and three of the four patients had amblyopia. Monocular VFT was full in the older patients tested. OMR showed dysconjugate vertical, multiplanar ocular oscillations with CN slow phases, well-developed foveation periods, and occasional spontaneous unocular saccades. VEPs showed crossed asymmetry and depressed latencies consistent with uncrossed optic pathways and optic nerve dysplasia. Specific MRI studies showed no chiasm in three patients and a hypoplastic chiasm in one. *Conclusions:* These patients further eluci-

Correspondence and reprint requests to:

Richard W. Hertle, M.D.
Pediatric Ophthalmology,
Strabismus, and Eye Movement
Disorders
Columbus Children's Hospital
& Ohio State University
555 South 18th Street, Suite 4C
Columbus, OH 43205
USA
Tel: 614-224-6222
Fax: 614-241-5232
E-mail: HertleR@chi.osu.edu

date the spectrum of human achiasma/hypochiasma. Careful intraocular and ocular motor evaluation found optic nerve anomalies and see-saw nystagmus in all patients. Patients with congenital optic nerve hypoplasia/dysplasia with or without other midline neurologic defects should be carefully evaluated for the clinical presence of see-saw nystagmus (SSN). The occurrence of the conditions CN, SSN, and optic nerve anomaly strongly suggests chiasma/hypochiasma. Electrophysiologic and radiographic evaluations should be considered in these patients.

Key words Achiasma; hypochiasma; see-saw nystagmus

Introduction See-saw nystagmus (SSN) is a unique vertical-torsional eye movement disorder with a characteristic appearance. It is usually a pendular nystagmus with two distinct components: a conjugate torsional component and a disjunctive vertical component. In the early 1990s, a remarkable new visual system abnormality (canine 'achiasma') was first described by Williams and colleagues in a group of Belgian sheep dogs in whom optic nerve fibers failed to cross at the optic chiasm and who manifested see-saw nystagmus (SSN).¹⁻⁶ Williams and colleagues reported that the optic nerves, in seven of eight dogs studied, did not approach each other to form a chiasm. Achiasma or 'non-decussating retinal fugal fiber syndrome' was subsequently recognized in humans.⁷⁻⁹ Apkarian and coworkers described asymmetries in the distribution of the monocular, pattern onset, visually evoked potential (VEP) in two children who presented with poor distant vision. SSN, similar to that seen in the achiasmatic dogs, was recognized in 1993 from a video of one of these achiasmatic children.¹⁰ These findings suggested a chiasmal anomaly that subsequent magnetic resonance imaging (MRI) scans confirmed. The only other report in the literature was that of a girl who presented with a midline cleft, nasal encephalocele, and SSN.¹¹ Recently, Leitch and coworkers^{11,12} and Thompson et al.^{9,13} reported five additional cases of chiasmal hypoplasia or aplasia. They reported five infants, between several weeks and seven months of age, with electrophysiologic characteristics of chiasmal hypoplasia. Clinical ophthalmologic examinations, including funduscopy and flash electroretinography, flash and pattern VEP, and MRI brain scans were performed. They found that in all five patients a 'crossed asymmetry' (right cortex receives the right eye's visually evoked response and the left cortex receives the left eye's visually evoked response) in the monocular VEP occipital distribution existed, which is consistent with a paucity of fibers crossing at the chiasm. The MRI findings in these patients supported this electrophysiologic observation, illustrating degrees of chiasmal hypoplasia and variable coincidence of other midline abnormalities of the brain. Optic disc appearances varied from normal to hypoplastic and colobomatous.⁹

Experimental analysis of the achiasmatic mutant Belgian sheep dogs demonstrated that the entire nasal hemiretina with its misdirected ipsilateral projection made functional connections in the thalamus and in the ipsilateral primary visual cortex.⁴ A critical finding was that input from nasal and temporal sides of the same retina was integrated at the

cortical level. Adjacent neurons often responded to visual stimuli that were far apart – often on opposite sides of the vertical meridian. Given this radical mis-arrangement of maps of visual space, it is not surprising that the ocular motor system of these achiasmatic dogs did not develop normally. The syndrome is associated with CN, SSN, and strabismus. Previous studies of achiasma suggested that total failure of the retinal fibers from both eyes to decussate at the optic chiasm allowed the development of both CN and SSN in dogs and humans.^{6,14}

This report summarizes the clinical, electrophysiologic, and radiographic abnormalities in four additional patients and reviews all 11 patients reported with achiasma.

Materials and methods All testing was approved by the Institutional Review Board of The National Eye Institute, The National Institutes of Health. This protocol observed the declaration of Helsinki and informed consent was obtained.

CLINICAL EXAMINATION All patients underwent the following clinical evaluation. Visual acuity testing was performed with refraction in place both binocularly and monocularly using the EDTRS charts, single surrounded HOTV optotypes, or the Teller Visual Acuity Cards. Binocular function was assessed using the Worth 4-dot test at distance and near and the Randot^R Preschool Stereoacuity Test. Ocular motor examination also included the determination of heterophoria at distance (6m) and near (33 cm) in all diagnostic positions of gaze using the simultaneous prism cover test and alternate prism cover test. Versions and ductions were examined and color vision was tested using the Ishihara^R color plates. Visual field testing was performed in one of four patients old enough to cooperate in formal visual field testing using Humphrey field analyzer and a 30–2 program. The ocular examination also included tonometry, slit-lamp and ophthalmoscopic examination of the anterior and posterior segments, and fundus photographs. Clinical evaluation of the ocular motor oscillations included examination of the oscillation in primary position, at near, and in diagnostic positions of gaze under monocular and binocular conditions.

OCULAR MOTILITY RECORDINGS The presentation of stimuli, and the acquisition, display, and storage of data were controlled by a PC using both Visual EXperimentation (VEX) and a Real-time EXperimentation (REX) software packages developed by Hays et al.¹⁵

The eye movement recordings of three patients (Y.D., A.B., and S.N.) were made using an IR reflection method (Ober System, Permobil Meditech Inc., Woburn, MA, USA); the system bandwidth was 0–500 Hz. Eye movements were calibrated using three-degree pictures presented on a plasma screen at a distance of one meter from the patient to targets at $\pm 15^\circ$ or $\pm 20^\circ$ horizontally and $\pm 10^\circ$ vertically. Clinical observation alone showed extorsion of the eye elevating and intorsion of the depressed eye.

The horizontal and vertical positions of both eyes were recorded in the other patient (J.V.) with an electromagnetic induction technique¹⁶ using scleral search coils (Skalar Medical, Delft, the Netherlands)

embedded in silastin rings.¹⁷ The coil signals were calibrated (using the end of the fast phase during the nystagmus cycle) at the beginning of the recording session by having J.V. fixate small target lights located on a plasma screen at a distance of one meter. Data were sampled at 1 kHz.

After calibration, the patients were seated with their head stabilized by means of a chin cup and headrest and they were asked to fixate between 0 and $\pm 5^\circ$, $\pm 10^\circ$, $\pm 15^\circ$, and $\pm 20^\circ$ with the right eye, left eye, and both eyes. Lastly, fixation at 0° with both eyes was accomplished for 10 minutes (to rule out asymmetric (a)periodic alternating nystagmus). Y.D. had recordings accomplished monocularly and binocularly with attempts made to look at textured and interesting targets placed at 0 degrees and right and left 15 degrees for a total of 10 minutes.

Eye movement data analyzed for this study included the average binocular and monocular frequencies, horizontal and vertical conjugacy, and slow-phase velocities during target fixation. The type of waveforms present were classified according to the previously described 12 waveforms associated with horizontal CN. Due to the sensitivity of these recording techniques, foveation periods and fast and slow phases could be identified during all cycles.

VISUALLY EVOKED POTENTIAL Visual evoked potentials were elicited by a full-field (Ganzfeld) flash stimulus of 3.0 cd.s/m² luminance and a 9.3 Hz rate. Five active electrodes were placed at O₃, O₁, O_Z, O₂, and O₄, the common reference electrode was located at FZ, and the ground electrode at CZ. Signals were amplified (sensitivity: 100 or 200 μ V), filtered (bandpass: 1 to 100 Hz), digitized, and averaged (two reproducible averages of 100 sweeps each) with a Nicolet Pathfinder recording system (Nicolet Biomedical, Madison, WI, USA). Peak-to-peak amplitude was measured by manual placement of cursors (7–9).

MAGNETIC RESONANCE IMAGING MR imaging was performed on a 1.5 T GE Signa unit. Three-dimensional volumetric, axial, T₁-weighted sequences were obtained with a resolution of 0.92 \times 0.92 \times 1.0 cu. Mm using the following parameters: three-dimensional axial spoiled gradient repetition time (TR) 6.7 msec, echo time (TE) 1.7 msec, inversion time (TI) 300 msec, field of view (FOV) 22 square cm, slice thickness 1.0, and matrix (MAT) 256 \times 256 pixels. Coronal slices (2.5 mm thick) were obtained with an in-plane resolution of 0.85 \times 0.85 square mm using a fast spin echo STIR (short tau inversion recovery). The volumetric T₁ sequences were imported into MEDx (Sensor Systems) and reformatted into oblique axial planes along the approximate plane of the optic nerves, tract, and chiasm.

Results

PATIENT 1 Y.D. was a five-month-old African-American male, who presented to the NEI in May 2000. He had a history of strabismus and nystagmus since the first two-three weeks of life. He was the full-term product of a normal pregnancy, labor, birth, and delivery. He had normal growth and development with coarctation of the aorta diag-

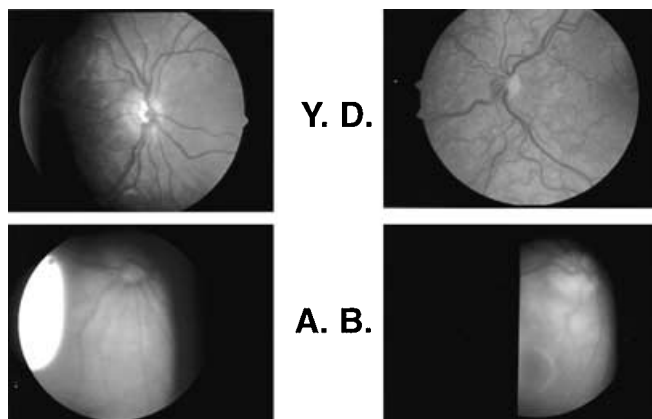


Fig. 1. Fundus photographs of the posterior poles of S.N. (top) and J.V. (bottom) showing varying amounts of optic disc anomalies. The small, obvious dysplastic nerves of J.V. are in contrast to the apparently normal appearing nerves of S.N. The overall size and neural rim area are reduced in J.V.

Patient	CN waveforms	CN amplitudes	CN frequency	CN conjugacy	CN plane	Avg foveation
Y.D.	P, AP, Pfs, Jef, PC, PJ, PPfs	3-6 Deg	4.2 Hz Avg	Yes	Multiplanar	135 msec
A.B.	P, Pfs, J, Jef, PC, PJ, PP, PPfs	1-6 Deg	3.5 Hz Avg	Yes	Multiplanar	72 msec
S.N.	P, Pfs, J, Jef, PC, PPfs	2-6 Deg	3.9 Hz Avg	Yes	Multiplanar	61 msec
J.V.	P, AP, Pfs, Jef, PP, PPfs	2-7 Deg	2.7 Hz Avg	Yes	Uniplanar	88 msec

CN, congenital nystagmus; AP, asymmetric pendular; Pfs, pendular with foveating saccades; PP, pseudopendular; PPfs, pseudopendular with foveating saccades; J, jerk; Jef, jerk with extended foveation; PC, pseudocycloid; PJ, pseudojerk; BDJ, bidirectional jerk; P, pendular; DEG, degrees; Hz, Hertz; Avg, average.

nosed shortly after birth for which he underwent repair at nine weeks of age. Examination at presentation revealed a Teller visual acuity of below normal for age (0.31 cycles/degree binocular presentation). His cycloplegic refraction was -5.00 sphere OU. He had a comitant, small-angle esotropia at distance and near with no preference and full versions and ductions. He had bilateral optic nerve anomalies OU (Figure 1). He had constant symmetric, multiplanar, conjugate (horizontally) and dysconjugate (vertically), moderate amplitude, moderate to high frequency, jerk and pendular involuntary ocular oscillations. Oculographic recording showed many CN waveforms (Table 1). The vertical component showed constant areas of 180-degree out-of-phase movements with the same characteristic slow phases. There were occasional grossly dysconjugate saccades in the two eyes. Magnetic resonance imaging showed no evidence of a chiasm (Figure 2). A VEP showed crossed asymmetry lateralization with the right eye projecting predominantly to the right cortex and the left eye to the left cortex (Figure 3).

PATIENT 2 A.B. was a four-year-old white male, who presented to the NEI in August 1999. He had a history of strabismus and nystagmus since the first few months of life. His past medical history was significant for microtia of the left ear with a conduction hearing loss in that ear and an asymptomatic atrial septal defect. Examination revealed best visual acuity of 20/160 OD, 20/160 OS, and 20/100 OU at distance and 20/80 vision at near using single surrounded HOTV optotypes. His

TABLE 1. Oculographic characteristics of the four patients in this report.

Fig. 2. Sagittal and axial T1-weighted MRI images of Y.D. show a hypoplastic corpus callosum and splenium (top left, arrowheads). Optic nerves transition to optic tracts without forming a chiasm (white arrows). The pituitary infundibulum (top left, black arrow) is present, but the chiasm (expected to be anterior to the infundibulum) is not.

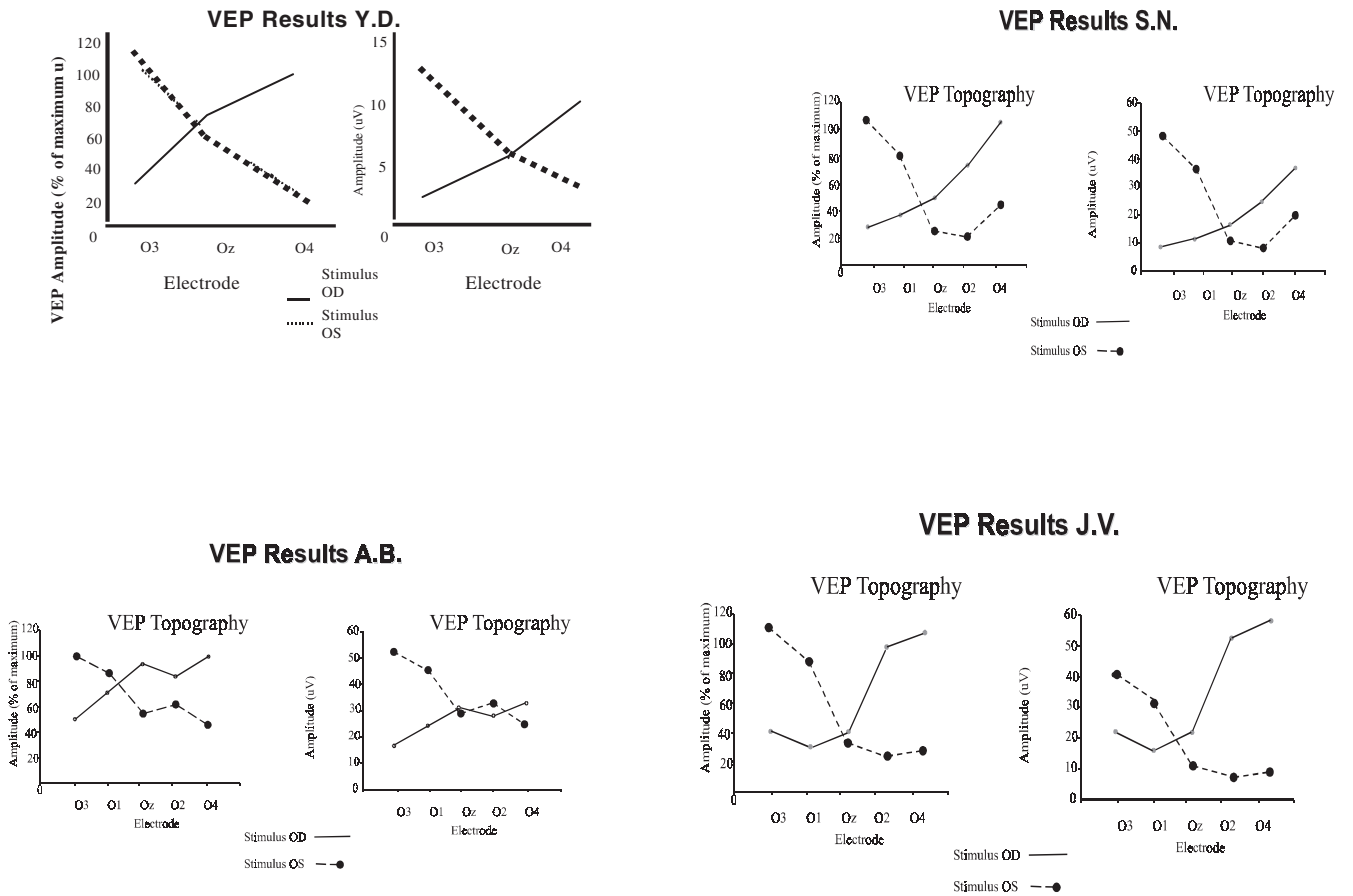
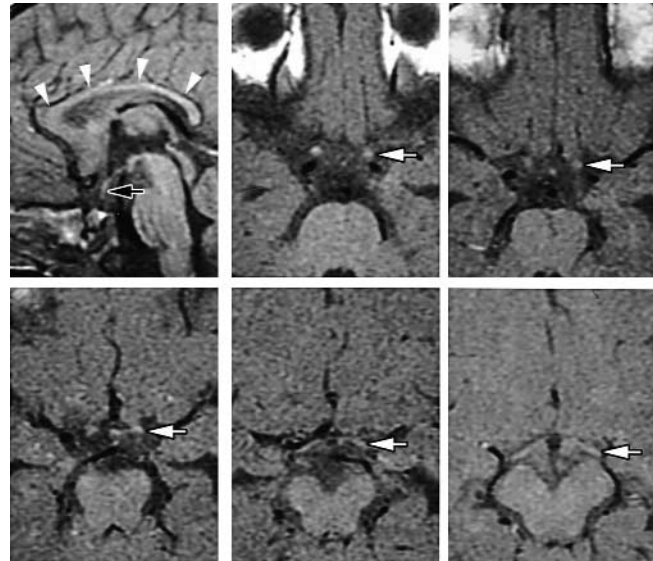


Fig. 3. Visual evoked response of all four patients showing crossed asymmetric response as both a percentage (%) of maximum response (left graph) and amplitude in microvolts (μ V) (right graph) plotted against electrode position (o3, o3 left side of scalp, o4 right side of scalp). VEP, visual evoked potential.

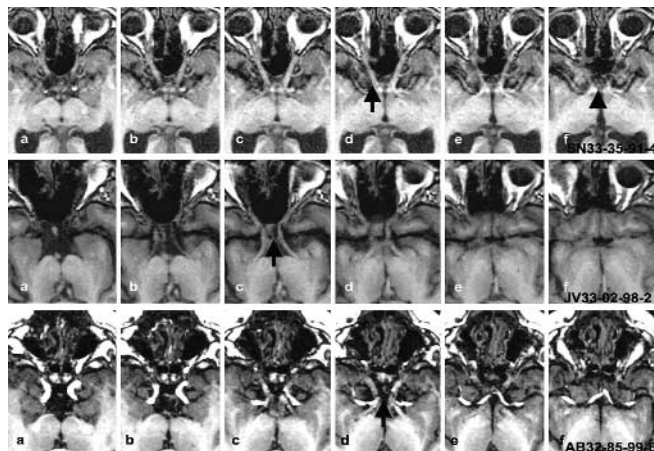


Fig. 4. Consecutive 1 mm-thick MRI reconstructions along the plane of the optic pathways in three patients (S.N. top, J.V. middle, A.B. bottom). Optic nerve (top arrow), expected location of the chiasm (middle arrow), and optic tract (bottom arrow) show that optic nerves transition into optic tracts without forming a chiasm in each patient. A rudimentary, hypoplastic chiasm may be present in S.N. (middle arrow).

cycloplegic refraction was $+3.50 +1.00 \times 110$ OD and $+3.00 +1.00 \times 90$ OS. He had a comitant, small-angle esotropia at distance and near with no preference, full versions and ductions, no fusion or stereopsis, and bilateral optic nerve anomalies OU (Tables 1, 2). He had constant symmetric, multiplanar, conjugate (horizontally) and dysconjugate (vertically), moderate amplitude, moderate to high frequency, jerk and pendular involuntary ocular oscillations. Oculographic recording showed many CN waveforms (Table 1). The vertical component showed constant areas of 180-degree out-of-phase movements with the same characteristic slow phases. A VEP showed crossed asymmetry lateralization with the right eye projecting predominantly to the right cortex and the left eye to the left cortex (Figure 3). An MRI showed no optic chiasm (Figure 4).

PATIENT 3 S.N. was an eight-year-old white male. His history was significant for a 14-day stay in the neonatal intensive care unit due to complications from aspiration. Using single surrounded HOTV optotypes, he had a best-corrected visual acuity of 20/70 OD and 20/200 OS at distance, 20/25 OD and 20/70 OS at near, and 20/60 OU at distance and 20/25 OU at near. He had a constant 20-prism-diopter esotropia at distance and near and all positions of gaze with a small right hypertropia. Versions and ductions were full with suppression of the left eye at distance and near and he had no fusion or stereopsis. Except for mildly dysplastic optic nerves (elongated, asymmetric cups and deficient neural rim tissue, OS > OD, Figure 1), he had an otherwise normal structural examination of the eyes. Ocular motility exam showed constant, symmetric, conjugate, moderate amplitude, moderate to low frequency horizontal, jerk, involuntary ocular oscillations. There was a slight clinical null position at 10 to 15 degrees up gaze, occasionally resulting a chin-down position at distance fixation. The oscillation had a large latent component and a clear 'see-saw' component. Oculographic recording showed many CN waveforms (Table 1). There was increased intensity with monocular cover. The vertical component showed constant 180-degree out-of-phase movements with the same characteristic slow phases (Figure 5, Table 1). There were occasional uniocular saccades and saccades or square-wave jerks with different

TABLE 2A. Summary of the clinical findings of all 11 patients known to have chiasmal developmental anomalies.

<i>PT</i>	<i>Age/sex</i>	<i>Vision</i>	<i>Refraction</i>	<i>Alignment</i>
1 - Hertle et al.	5 M.O.M.	F & F, CUSUM 20/160 OD/OS	(-)5.00 sph OU OD (+)2.00 (+)1.25 = 005	Comitant 10-15 ET
2 - Hertle et al.	4 Y.O.M.	20/100 OU 20/70 OD-20/250 OS	OS (+)2.75 (+)1.00 × 110 OD (-)2.25 (+)1.50 × 90	Comitant 12-15 XT Comitant 25 ET, Incomitant 8 RHT
3 - Hertle et al.	8 Y.O.M.	20/70 OU 20/100 OD-20/70 OS	OS (-)2.75(+1.50 × 120 OD (-)6.75 sphere	Comitant 5 ET, Incomitant 14 RHT
4 - Hertle et al.	19 Y.O.M.	20/70 OU	OS (-)6.25 sphere	N/A
1-Thompson et al.	7 M.O.M.	Poor F & F	'Not Significant'	N/A
2-Thompson et al.	14 M.O.M.	Good F & F	'Not Significant'	N/A
3-Thompson et al.	4 M.O.M.	N/A	N/A	N/A
4-Thompson et al.	35 M.O.M.	'poor'	N/A	N/A
1-Leitch et al.	4 M.O.F.	Good F & F	N/A	N/A
1-Apkarian et al.	14 Y.O.F.	20/80 OU	N/A	'Alternating ET'
2-Apkarian et al.	4 Y.O.	20/100 OU	N/A	'Alternating ET'

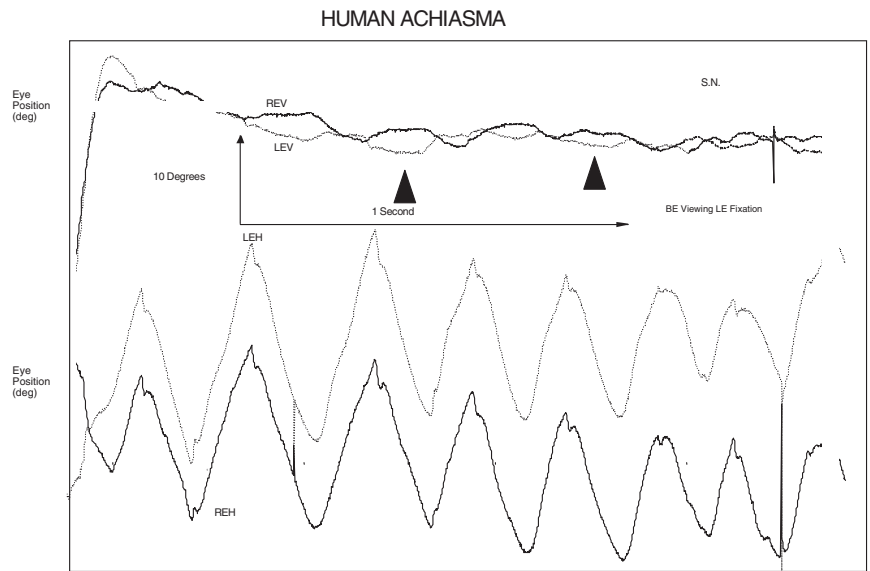
PT, patient; Y.O.M., year old male; M.O.M. (F.), month old male (female); OD, right eye; OS, left eye; OU, both eyes; XT, exotropia; ET, esotropia; RHT, right hyper-
tropia; Vision, Vision measured using single surrounded HOTV optotypes; F & F, fixation and following; N/A, not available.

TABLE 2B. Summary of the clinical findings of all 11 patients known to have chiasmal developmental anomalies.

PT	VEP	Ocular oscillation	Ocular defects	Chiasmal anatomy	Systemic
1 – Hertle et al.	Crossed Asymmetry	CN + SEE-SAW + UOS	Dysmorphic Optic Discs OU	NONE	Aortic Coarctation Left Microtia Atrial Septal defect
2 – Hertle et al.	Crossed Asymmetry	CN + SEE-SAW + UOS	Dysmorphic Optic Discs OU Dysmorphic Optic Discs OU Amblyopia OS	NONE NONE NONE	NONE Congenital Hydrocephalus Benign Parotid Gland Tumor 'Slow Development' White Matter Changes Cognitive and Motor Organizational Delay
3 – Hertle et al.	Crossed Asymmetry	CN + SEE-SAW + UOS	Iris Coloboma, Cataract OD Dysmorphic Optic Discs OU Amblyopia OD Normal Optic Nerve	NONE Hypoplasia Chiasm	
4 – Hertle et al. 1-Thompson et al.	Crossed Asymmetry Crossed Asymmetry	CN + SEE-SAW + SO Pendular			
2-Thompson et al.	Crossed Asymmetry	Pendular*	Peripapillary Pigment	Thin Strand' Posterior! Hypoplasia Chiasm Absent Septum Pellucidum	
3-Thompson et al.	Crossed Asymmetry	Not Tested	Hypoplasia OU		SOD+, Hypopituitarism, Global Delay Cleft Lip/Palate, Encephalocele, Developmental Delay Cleft Lip/Palate, Encephalocele,
4-Thompson et al.	Crossed Asymmetry	SEE-SAW*/Vertical Gaze Palsy	Bilateral Colobomatous 'Morning Glory'	NONE	
1-Leitch et al. 1-Apkarian et al. 2-Apkarian et al.	Crossed Asymmetry Crossed Asymmetry Crossed Asymmetry	SEE-SAW* SEE-SAW SEE-SAW	? Hypoplasia 'Normal' 'Normal'	NONE NONE NONE	Holoprosencephaly Normal Normal

PT, patient; VEP, visual evoked potential; CN, congenital nystagmus; SEE-SAW, see-saw nystagmus; UOS, uniocular saccades; SO, saccadic oscillations; SOD+, septo-optic dysplasia positive. *Clinically observed only, no ocular motility recordings.

Fig. 5. Position recording of patient S.N. showing horizontal in-phase oscillation, typical of congenital nystagmus. The low-amplitude vertical oscillation shows periods of out-of-phase oscillation, typical of see-saw nystagmus (arrowheads). Black triangles are areas of out-of-phase vertical oscillations depicting SSN. REV, right eye vertical; LEV, left eye vertical; BE, both eyes; LEH, left eye horizontal; REH, right eye horizontal; deg, degrees. Rightward and upward eye movements are up.



directions in the two eyes. A VEP showed crossed asymmetry lateralization with the right eye projecting predominantly to the right cortex and the left eye to the left cortex (Figure 3). An MRI showed no optic chiasm (Figure 4).

PATIENT 4 J.V. was a 19-year-old white male with congenital hydrocephalus and a cleft lip/palate. He had undergone 15 surgical procedures in 19 years related to a central nervous system shunt, cleft lip/palate and nasal repairs, and removal/reconstruction of a benign parotid gland tumor at 18 years of age. His past ophthalmic history was significant for nystagmus, strabismus, and iris coloboma and peripheral cataract, both OD. He had had ophthalmic treatment consisting of myopic spectacles for the last 10 years. He had occasional complaints of circular oscillopsia. His best-corrected vision was 20/100 OD, 20/70 OS, and 20/70 OU at distance and 20/40 OU at near with -6.25 sphere OU. He had deficient color vision testing, no fusion or stereopsis, and a comitant esotropia and right hypertropia. He had a typical iris coloboma OD and a peripheral cortical cataract OD with slightly dysmorphic optic nerves OU (small size, obscure peripapillary rim, and no central cup, Figure 1). He had a full visual field using an automated Humphrey^R 30-2 paradigm. He had constant, symmetric, conjugate horizontally and dysconjugate vertically, moderate amplitude, moderate to high frequency elliptical, jerk and pendular oscillations. When the OS elevated and intorted, the OD depressed and extorted and vice versa. Oculographic recording showed many CN waveforms (Table 1). There were good foveation periods OU (40–100 msec) consistent with good vision. He also had constant dysconjugate vertical slow phases consistent with SSN. The normally pendular SSN waveform of this patient showed the imposition of pendular with foveating saccades (Pfs) in the fixating eye that were phase-locked with those in the horizontal Pfs of the CN waveform (Figure 6). A VEP showed crossed asymmetry lateralization with the right eye projecting predominantly

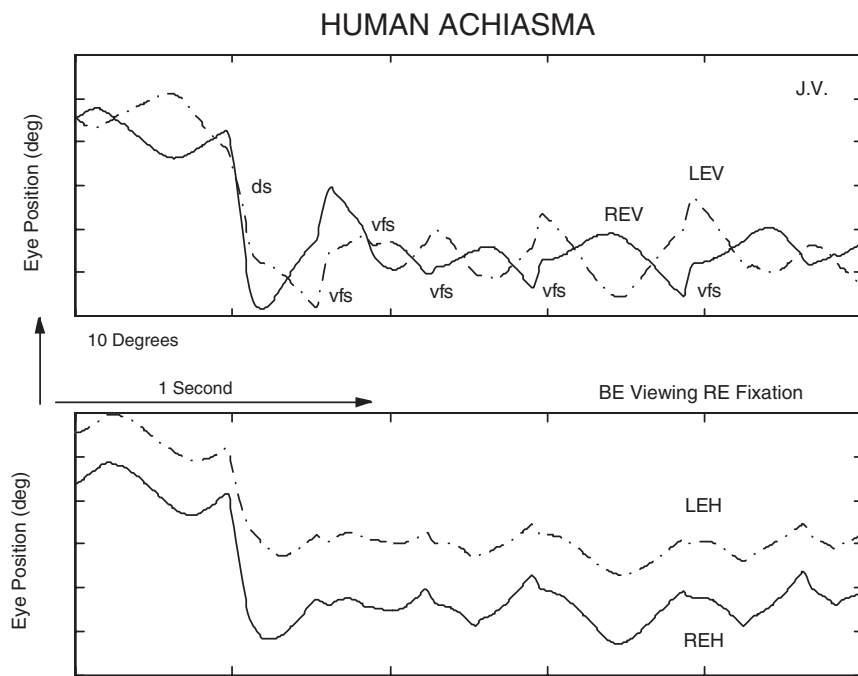


Fig. 6. Horizontal and vertical position recordings of patient J.V. showing a diagonal saccade (ds) and vertical foveating saccades (vfs) in the pendular see-saw nystagmus that are phase-locked with their counterparts in the horizontal congenital nystagmus. REV, right eye vertical; LEV, left eye vertical; BE, both eyes; LEH, left eye horizontal; REH, right eye horizontal; deg, degrees. Rightward and upward eye movements are up.

to the right cortex and the left eye to the left cortex (Figure 3). An MRI showed numerous 3rd ventricular and chiasmal structural abnormalities (Figure 4).

ALL PATIENTS All four patients had nystagmus, strabismus, and decreased vision since early infancy. They had a combination of anterior optic pathway anomalies (nerve/disc), amblyopia, refractive errors, and nystagmus that contributed to their visual loss. It was only after later consultation and/or electrophysiologic evaluation that their SSN was noted. Although all patients were cognitively normal, one patient (J.V.) had other structural defects of the brain leading to congenital hydrocephalus. Automated visual field examination was normal in J.V. despite the oscillation and abnormal sensory system. Three of the four patients had associated systemic findings including coarctation of the aorta, atrial septal defect, microtia, hydrocephalus, cleft lip/palate, and a parotid tumor.

Either absence of the chiasm or chiasmal hypoplasia was demonstrated in all cases, providing the anatomic basis for the VEP results. The transition from optic nerve to optic tract did not form a chiasm at the midline. To definitively diagnose this condition, thin sections should be obtained. Here, we used a 3D-volumetric acquisition with 1.0 mm slice thickness to demonstrate these patients' hypochiasma and achiasma. Notably, achiasma occurred without associated defects in most other midline structures, namely the anterior and posterior commissures, the pituitary gland, the third ventricle, the septum pellucidum, and the mammillary bodies. The only associated midline anomaly was that of the corpus callosum, particularly the splenium.

Ocular motility recordings were similar in all patients. They all had horizontal nystagmus typical of CN (Table 1, Figures 5, 6). In addition,

they all had a constant, low amplitude, vertical, out-of-phase, slower intensity, pendular/torsional oscillation characteristic of SSN. Three of the four patients (Y.D., A.B., and S.N.) also had occasional uniocular saccades.

The VEP hallmark of these three achiasmatic patients was a characteristic and unusual asymmetry in the peak-to-peak amplitude between the waveforms recorded to the right and left of the midline. With monocular stimulation OD, the amplitude of the VEPs recorded with electrodes to the left of the midline (O₃, O₁) was larger than that of the VEPs recorded with electrodes to the right of the midline (O₂, O₄). VEPs elicited by stimulation of OS have the opposite configuration. This crossed asymmetry is depicted in graphs of VEP amplitude as a function of electrode site (Figure 4), following the convention introduced by Apkarian et al.⁷ In these graphs, amplitude is expressed as a percentage of maximum amplitude, which in all cases was recorded with the lateral occipital electrode (O₃ or O₄) ipsilateral to the stimulated eye.

Tables 2A and 2B summarize the findings of the eleven known patients with achiasma/hypochiasma.

Discussion Congenital nystagmus (CN) (seen in all these patients) is an ocular motor disorder of unknown etiology, which presents at birth or early infancy and is clinically characterized by involuntary oscillations of the eyes.¹⁸⁻²² Estimations of the incidence of CN vary enormously from 1 in 350 to 1 in 20,000, although the generally quoted estimated incidence is 1 in 6550 or 0.015%.²³⁻²⁶ These movements most commonly have a slow and a fast phase, although they may be purely pendular. They are usually horizontal with a variable torsional component and may (rarely) have a vertical component. Other clinical characteristics, with variable association, include: increased intensity with fixation attempt and decreased with sleep or inattention; variable intensity in different positions of gaze (usually about a null position); changing direction in different positions of gaze (about a neutral position); decreased intensity (damping) with convergence; anomalous head posturing; strabismus; and the increased incidence of significant refractive errors. CN can occur in association with congenital or acquired defects in the visual sensory system (e.g., albinism, achromatopsia, and congenital cataracts). The causes and precise mechanisms of some CN waveforms have not been elucidated, but the pendular waveforms have been hypothesized to stem from the normal velocity oscillation of the smooth pursuit system – that is, *pursuit-system* nystagmus [Dell’Osso, 1972 #132; Dell’Osso, 1997 #131; Dell’Osso, 2000 #130]. The association of strabismus and congenital optic nerve and visual pathway disease is not unique. Infantile forms of strabismus are common with optic nerve hypoplasia and albinism. It is not unexpected that all of our patients also had strabismus.

In those cases of see-saw nystagmus in which a focal lesion has been identified, the lesion is usually a bilateral, symmetric lesion located at the mesodiencephalic junction.²⁷⁻³⁴ There are many afferent conditions associated with human CN that are not its direct cause. Similarly, achiasma and hemichiasma³⁵ are not causally related to either CN or SSN;

that is, they are not the direct cause of either. Motor oscillations, such as CN and SSN, are the direct result of unstable gain and phase relationships in their respective control systems.

Achiasma and chiasmal hypoplasia are conditions that may interfere with the proper calibration of the developing motor control system. Motor oscillations, such as CN and SSN, are the direct result of unstable gain and phase relationships in their respective control systems. Congenital SSN has been reported in two sibling patients with advanced retinitis pigmentosa (RP).³⁶ The SSN in our patients had a more typical type of torsional component (extorsion with elevation and intorsion with depression) unlike the report of the two siblings with advanced RP who demonstrated a unique torsional pattern (intorsion with elevation and extorsion with depression).³⁶ SSN is also associated with septo-optic dysplasia, a congenital syndrome of midline abnormalities of the central nervous system resulting in the absence of the septum pellucidum and dysplasia of the optic chiasm or optic nerves. The characteristic fundus findings of small, dysplastic discs and defects in the nerve fiber layer enable the clinician to predict this syndrome prior to radiographic studies.^{2,29}

In our patients, monocular flash visually evoked potentials showed the crossed asymmetry in scalp distribution indicative of compromise of chiasmal crossing fibers. These patients show diminished contralateral projections. This achiasmatic condition has been previously documented in a breed of Belgian sheep dogs.¹ Monocular VEP responses in these patients across the occiput, regardless of stimulus mode (full- or partial-field pattern onset, pattern reversal, luminance flash or high temporal frequency luminance flicker) showed unequivocal evidence of pathological VEP ipsilateral asymmetry. Marked attenuation of primary visual evoked responses from the occiput contralateral to the eye of stimulation indicated aberrant contralateral retinal-fugal projections.

This was confirmed by MRIs that depicted the achiasmatic condition. Colpocephaly (dilation of the occipital horns of the lateral ventricles) was variably present, a finding most commonly seen with callosal agenesis or hypogenesis due to a paucity of white matter in the occipital lobes. While the deficiency of the splenium seen in these cases of achiasma may be interpreted as an associated midline defect, it is also possible that it is secondary to the absence of the chiasm.

Although clinical, electrophysiologic, and radiographic data for all 11 patients is not complete (Table 2), some generalities regarding this condition can be stated. This condition is a developmental anomaly of the midline central nervous system that may or may not have other systemic findings, e.g. craniofacial, heart. The condition presents in early infancy or childhood with decreased visual behavior, nystagmus, and strabismus (a fairly common combination of clinical characteristics).^{21,37} The outstanding clinical sign is the presence of SSN in addition to the more typical oscillation of CN.³⁵ There is the associated finding of optic pathway (nerve/disc) anomalies (hypoplasia, dysplasia, and coloboma) in all patients seen clearly with 3-D volumetric MRI acquisition. Other systemic or central nervous system signs or symptoms can be present. Because of this, we recommend that these patients be followed for signs

of central pituitary dysfunction. The presence of the triad of SSN (plus CN), strabismus, and optic disc anomalies should prompt the clinician to conduct further electrophysiologic and/or radiographic investigations in search of structural abnormalities of the optic chiasm.

References

- 1 Williams RW, Garraghty PE, Goldowitz D. A new visual system mutation: achiasmatic dogs with congenital nystagmus. *Soc Neurosci Abstr.* 1991;17:187.
- 2 McCarty JW, et al. Ocular motility anomalies in developmental misdirection of the optic chiasm [see comments]. *Am J Ophthalmol.* 1992;113(1):86–95.
- 3 Williams RW, Dell'Osso LF. Ocular motor abnormalities in achiasmatic mutant Belgian sheepdogs. *Invest Ophthalmol Vis Sci.* 1993;34:1125.
- 4 Williams RW, Hogan D, Garraghty PE. Target recognition and visual maps in the thalamus of achiasmatic dogs [see comments]. *Nature.* 1994;367(6464):637–639.
- 5 Dell'Osso LF, Williams RW. Ocular motor abnormalities in achiasmatic mutant Belgian sheepdogs: unyoked eye movements in a mammal. *Vision Res.* 1995;35:109–116.
- 6 Hogan D, Williams RW. Analysis of the retinas and optic nerves of achiasmatic Belgian sheepdogs. *J Comp Neurol.* 1995;352(3):367–380.
- 7 Apkarian P, Bour L, Barth PG. A unique achiasmatic anomaly detected in non-albinos with misrouted retinal-fugal projections. *Eur J Neurosci.* 1994;6(3):501–507.
- 8 Apkarian P, Bour LJ, Barth PG, Wenniger-Prick L, Verbeeten Jr B. Non-decussating retinal-fugal fiber syndrome. An inborn achiasmatic malformation associated with visuotopic misrouting, visual evoked potential ipsilateral asymmetry and nystagmus. *Brain.* 1995;118(5):1195–1216.
- 9 Thompson DA, Kriss A, Chong K, Harris C, Russell-Eggitt I, Shawkat F, Neville BG, Aclimandos W, Taylor DS. Visual-evoked potential evidence of chiasmal hypoplasia. *Ophthalmology.* 1999;106(12):2354–2361.
- 10 Dell'Osso LF. See-saw nystagmus in dogs and humans: an international, across-discipline, serendipitous collaboration. *Neurology.* 1996;47:1372–1374.
- 11 Leitch RJ, Winter RM. Midline craniofacial defects and morning glory disc anomaly. A distinct clinical entity. *Acta Ophthalmol Scand Suppl.* 1996;219:16–19.
- 12 Leitch RJ, Thompson D, Harris CM, Chong K, Russell-Eggitt I, Kriss A. Achiasma in a case of midline craniofacial cleft with seesaw nystagmus [letter]. *Br J Ophthalmol.* 1996;80(11):1023–1024.
- 13 Thompson DA, Kriss A, Cottrell S, Taylor D. Visual evoked potential evidence of albino-like chiasmal misrouting in a patient with Angelman syndrome with no ocular features of albinism. *Dev Med Child Neurol.* 1999;41(9):633–638.
- 14 Dell'Osso LF, Williams RW, Jacobs JB, Erchul DM. The congenital and see-saw nystagmus in the prototypical achiasma of canines: comparison to the human achiasmatic prototype. *Vision Res.* 1998;38:1629–1641.
- 15 Hays AV, Richmond BJ, Optican LM. A Unix-based multiple system for real-time data acquisition and control. In: *Wescon Conference Proceedings.* 1982.
- 16 Robinson DA. A method of measuring eye movement using a scleral search coil in a magnetic field. *IEEE Trans Bio-Med Electron.* 1963;BME(10):137–145.
- 17 Collewijn H, Van Der Mark F, Jansen TC. Precise recordings of human eye movements. *Vision Res.* 1975;15:447–450.
- 18 Parks MM. Symposium nystagmus.

- Congenital nystagmus surgery. *Am Orthop J*. 1973;23:35–39.
- 19 Dell'Osso LF, Daroff RB. Congenital nystagmus waveforms and foveation strategy. *Doc Ophthalmol*. 1975;39:155–182.
- 20 Dell'Osso LF, Schmidt D, Daroff RB. Latent, manifest latent, and congenital nystagmus. *Arch Ophthalmol*. 1979;97(10):1877–1885.
- 21 Hertle RW, Dell'Osso LF. Clinical and ocular motor analysis of congenital nystagmus in infancy [see comments]. *J AAPOS*. 1999; 3(2):70–79.
- 22 Spielmann A. Congenital nystagmus: clinical types and their surgical treatment. *Ophthalmologica*. 1981; 182:65–72.
- 23 Norn MS. Congenital idiopathic nystagmus. Incidence and occupational prognosis. *Acta Ophthalmol*. 1964;42(4):889–896.
- 24 Forssman B, Ringnér B. Prevalence and inheritance of congenital nystagmus in a Swedish population. *Ann Hum Genet (London)*. 1971; 35(2):139–147.
- 25 Hu DN. Prevalence and mode of inheritance of major genetic diseases in China. *J Med Genet*. 1987;24(10):585–588.
- 26 Stewart-Brown SL, Haslum MN. Partial sight and blindness in children of the 1970 birth cohort at 10 years of age. *J Epidemiol Community Health*. 1988;42(1): 17–23.
- 27 Arnott EJ, Miller SJ. See saw nystagmus. *Trans Ophthalmol Soc UK*. 1970;90:491–496.
- 28 Daroff RB. Ocular oscillations. *Ann Otol Rhinol Laryngol*. 1977;86(1 Pt 1):102–107.
- 29 Davis GV, Shock JP. Septo-optic dysplasia associated with see-saw nystagmus. *Arch Ophthalmol*. 1975;93(2):137–139.
- 30 Drachman DA. See-saw nystagmus. *J Neurol Neurosurg Psychiatry*. 1966;29(4):356–361.
- 31 Halmagyi GM, Aw ST, Dehaene I, Curthoys IS, Todd MJ. Jerk-waveform see-saw nystagmus due to unilateral meso-diencephalic lesion. *Brain*. 1994;117(4):789–803.
- 32 Mewis L, Tang RA, Mazow ML. See-saw nystagmus after strabismus surgery. *J Pediatr Ophthalmol Strabismus*. 1982;19(6):302–305.
- 33 Samkoff LM, Smith CR. See-saw nystagmus in a patient with clinically definite MS. *Eur Neurol*. 1994;34(4):228–229.
- 34 Williams IM, et al. See-saw nystagmus. *Aust J Ophthalmol*. 1982;10(1):19–25.
- 35 Dell'Osso LF, Daroff RB. Two additional scenarios for see-saw nystagmus: achiasma and hemichiasma. *J Neuro Ophthalmol*. 1998;18:112–113.
- 36 Bergin DJ, Halpern J. Congenital see-saw nystagmus associated with retinitis pigmentosa. *Ann Ophthalmol*. 1986;18(12):346–349.
- 37 Hertle RW, Zhu X. Oculographic and clinical characterization of thirty-seven children with anomalous head postures, nystagmus, and strabismus: the basis of a clinical algorithm. *J AAPOS*. 2000;4(1):25–32.

