

Ocular motor stability of foveation periods

Required conditions for suppression of oscillopsia [◊]

L. F. DELL'OSSO^{1-3*} and R. J. LEIGH¹⁻⁴

Ocular Motor Neurophysiology Laboratory¹ and Neurology Service⁴, Veterans Affairs Medical Center; and the Departments of Neurology² and Biomedical Engineering³, Case Western Reserve University and University Hospitals of Cleveland; Cleveland, OH; USA

ABSTRACT. Individuals with congenital nystagmus (CN) usually do not experience oscillopsia. We hypothesized that the ability to suppress oscillopsia in CN is the result of perceptual mechanisms that differentiate retinal image motion caused by the oscillation itself from that of real target motion. In previous studies we showed that: (1) by inducing oscillopsia in CN subjects who did not experience it under normal conditions, retinal image stability was insufficient to suppress oscillopsia in the presence of nystagmus; (2) the presence of *repeatable, well-developed* (retinal error position $\leq 0.5^\circ$ and error velocity $\leq 4^\circ/\text{sec}$) foveation periods was necessary for visual constancy. The present study is of a subject with *diagonal* CN whose direction of perceived oscillopsia varied with the eye used for fixation; the oscillopsia corresponded to the absence of well-developed foveation periods in either (horizontal or vertical) or both planes. Thus, poorly developed foveation periods in the horizontal, vertical or both planes resulted in horizontal, vertical or diagonal oscillopsia respectively; except for the diagonal condition, the direction of oscillopsia was *not* directly linked to that of the CN. Based on this and our previous studies of CN foveation dynamics during the perception and suppression of oscillopsia, we hypothesize that the necessary and sufficient conditions for visual constancy in either plane are the presence of repeatable, well-developed foveation periods of sufficient time duration in that plane (perhaps as little as 15 msec), and that these conditions must be simultaneously satisfied in both planes to preclude oscillopsia in either plane.

Key words: oscillopsia; congenital nystagmus; foveation; spatial constancy

INTRODUCTION

Since the first description of oscillopsia¹, its relationship to eye motion has been a subject of spec-

[◊] This work was supported in part by the Department of Veterans Affairs and by NIH Grant EY06717 (R.J.L).

* *Reprint requests and correspondence to:* L.F. Dell'Osso, Ph.D., Ocular Motor Neurophysiology Laboratory, Veterans Affairs Medical Center (127A), 10701 East Boulevard, Cleveland, OH 44106 USA, Telephone: (216) 421-3224, FAX: (216) 844-3160

ulation. Although reports exist of oscillopsia occurring in the absence of clinically apparent ocular motor dysfunction ('central oscillopsia')² or induced by transcutaneous nerve stimulation³, accurate recording methods have demonstrated that oscillopsia is usually caused by excessive retinal image slip due to spontaneous nystagmus or an abnormal vestibulo-ocular reflex (VOR). Under normal conditions, despite the retinal image slip caused by normal eye movements (*e.g.*,

smooth pursuit of a small target across a textured background), no oscillopsia is present. However, if one places an after-image on the retina of a normal individual and he moves his eyes voluntarily, he will perceive movement of the after-image across the stationary background in his visual field (this is a well-known phenomenon to anyone who has experienced the bright flash of a photographer's flash bulb – pre-electronic flash); in complete darkness, the after-image may be perceived as moving (oscillopsia) or stationary since there is no other image with which it might be compared⁴. Under these same conditions, individuals with congenital nystagmus (CN) also experience the perception of oscillopsia of the after-image across the stationary background and report either oscillopsia or a stationary after-image in the dark⁵⁻⁹. The perceived motion of after-images in CN was used in an early study of fixation in an attempt to determine if the waveform was biased¹⁰. Thus, for the dark condition, given the same retinal and ocular motor conditions, the resulting perception of motion is not unique (*i.e.*, the brain has some latitude in determining what shall be perceived as stationary or moving). If there is no eye movement, there is no oscillopsia of the after-image. During head movement while fixating a distant target, the VOR acts to move the eyes in the head to achieve eye stability in space and no oscillopsia results. If, however, the head movement contains components outside of the normal operating range of the VOR (*e.g.*, vigorous voluntary head movements), the eyes will not remain stationary in space and oscillopsia will result¹¹.

In individuals with acquired nystagmus (AN), oscillopsia is usually present but in those with CN, oscillopsia is rare. The waveforms of horizontal AN are either pendular, linear or decreasing-velocity exponentials; vertical AN some-

times exhibits increasing-velocity exponentials^{12,13}. The feature that distinguishes CN from AN, besides the increasing-velocity nature of the slow phases, is the presence of foveation periods occurring just prior to the initiation of the slow phases. Both linear and decreasing-velocity slow phases have an initial velocity that is usually high enough to preclude good vision or provide for visual stability. Pendular waveforms and increasing-velocity slow phases have an initial velocity at or near zero that allows the individual's fixation mechanism to grasp the target image, if it is on the fovea at that point in the cycle, and extend the time that the eyes either remain motionless or drift with a low velocity. The extent to which this extension occurs (*i.e.*, how *well-developed* the foveation periods are), is related to both the visual acuity^{14,15} and visual stability¹⁶⁻¹⁹ of the individual.

In a previous study of a CN patient who developed oscillopsia in later life following an episode of loss of consciousness, we showed the necessity of well-developed foveation periods in his horizontal CN to suppress horizontal oscillopsia¹⁷. This suppression required extended foveation time and low beat-to-beat variation of both the position and velocity of the foveation periods. A 'foveation window' was defined where the eye position was $\leq 0.5^\circ$ from the target and eye velocity was $\leq 4^\circ/\text{sec}$ simultaneously. When the CN waveform had well-developed foveation periods (within the window), no oscillopsia resulted; when it did not, horizontal oscillopsia resulted. Thus, when the speed of image motion was below $4^\circ/\text{sec}$ as it crossed the foveal region, vision was reported as stable; when image motion exceeded this value, he reported oscillopsia. All vertical components of the CN were of such low amplitude that they always remained within the window and no vertical oscillopsia was experienced.

This study is of an individual with *diagonal* CN whose oscillopsia direction was dependent on the eye used for fixation. Taken together, these studies of oscillopsia and CN suggest the necessary and sufficient conditions for oscillopsia (horizontal, vertical or diagonal) in the presence of involuntary eye movements or, conversely, those conditions needed to suppress oscillopsia. They form the basis for therapeutic intervention in cases of AN with oscillopsia to alleviate this debilitating symptom and suggest the mechanism by which normals perceive spatial constancy in the presence of eye movements.

CASE HISTORY

A 28-year-old woman underwent surgery for strabismus at 18 months of age. At 13 years of age, CN was diagnosed and she noted intermittent oscillopsia during her teens. At 23 years of age, following the birth of a son, she developed post-partum depression and was treated with a variety of medications. She had been taking lithium for two years and discontinued its use three weeks before seeing us; she had also taken buspirone (discontinued three months prior to seeing us) and was currently taking fluoxetine hydrochloride. We presume the horizontal component of her CN has been present since infancy and the vertical component resulted either wholly or partially from the drug therapy.

Her chief complaint, both to her referring physician and during her first recording session in our laboratory, was oscillopsia that was mainly horizontal in the right eye and vertical in the left; the oscillopsia was most troublesome when her eyes tended to 'cross'; she did not complain of diplopia. Her visual acuity with correction was approximately 20/50 OD and 20/40 + 2 OS. She had no stereopsis and normally fixated with her right eye. During her second recording session, two months after the first, she elaborated on her previous report that during right-eye fixation the oscillopsia could sometimes be diagonal and during left-eye fixa-

tion, it could sometimes be elliptical with a counterclockwise motion along a major axis of approximately 135°. She drew pictures of the perceived motion under each fixation condition. These clearly showed the trajectories, including the relative amplitudes of the horizontal and vertical components when both were present; the latter allowed us to quantify the relative amplitudes and compare the oscillopsia to the CN trajectories for each fixation condition.

Our examination revealed that, in addition to a horizontal CN, she had a see-saw vertical component that resulted in a diagonal nystagmus of both eyes. The fixating eye, either the right or left, beat downward and nasally while the tropic eye beat upward and temporally. Thus, the horizontal component of the fast phases beat toward the non-fixating eye (*i.e.*, a *reversed* latent component). Convergence did not suppress her CN. With both eyes open, she fixated with her right eye while her left was approximately 14° esotropic and 5° hypotropic; during right-eye fixation, covering the left had no effect. Forced fixation with her left eye resulted in the right eye becoming 14° esotropic and 1° hypotropic (these measurements were taken from the eye-movement data).

METHODS

Recording

Horizontal and vertical eye motion of both eyes was recorded using the scleral search coil method with 6-foot field coils (CNC Engineering, Seattle, WA). The coil system bandwidth was 0-150 Hz, linear range of greater than $\pm 20^\circ$ and sensitivity of 0.1° in both planes. The subject's stabilized head remained within the 30 cm cube of the magnetic field where the translation artifact was less than 0.03°/cm. Data were filtered (bandwidth 0-90 Hz) and digitized at 200 Hz with 16-bit resolution. Scleral-coil (Skalar, Delft, The Netherlands) gain was calibrated using a protractor device capable of rotations in each plane. During analysis, the mean foveation position of each eye was set to 0° to align the target position when that eye was viewing. This is routinely done for most other types of eye-move-

ment recording methods and although it does not guarantee that the 0° eye position coincides with a target image on the center of the fovea, it does place 0° at the subject's chosen point of fixation; except for rare cases of extrafoveal fixation or certain types of foveal aplasia, it is reasonable to equate 0° with the foveal center, especially when the subject has good vision. In addition, data could be stored on magnetic tape and displayed on a rectilinear strip chart recorder (Beckman Type R612 Dynograph, bandwidth 0-100 Hz). Horizontal eye movement recordings were also made using infrared reflection. Eye velocities were obtained by analog differentiation of the position channels. The strip chart recording system and tape capabilities were the same as described above and the total system bandwidth (position and velocity) was 0-100 Hz.

Protocol

The subject was instructed to fixate on the center dot, located in primary position, on a 20° square Amsler grid while one eye was occluded or with both unoccluded. Also recorded was fixation at the cardinal gaze positions. Retinal image stabilization (RIS) of a 20° square Amsler grid was accomplished in the horizontal plane using the horizontal signal from the scleral search coil to drive a mirror galvanometer that reflected the target onto the back of a translucent screen. While the subject fixated the center of the grid, a bias voltage was added to the search coil signal until there was no horizontal drift of the display; this ensured that the image was foveally stabilized. This method is independent of whether the subject has nystagmus (congenital or acquired) or oscillopsia. In all cases, the subject senses the slow drift produced by a parafoveal image and can inform the experimenter when the drift has ceased. The experimenter can also see the target drifting, even when it is oscillating with the subject's nystagmus. Ambient illumination was dim. Further details may be found elsewhere²⁰.

Analysis

Data analysis, statistical computation of means

and standard deviations (SD) and graphical presentation were accomplished on an IBM PS/2 Model 80 using the ASYST software for scientific computing. Further details on ASYST may be found elsewhere²¹.

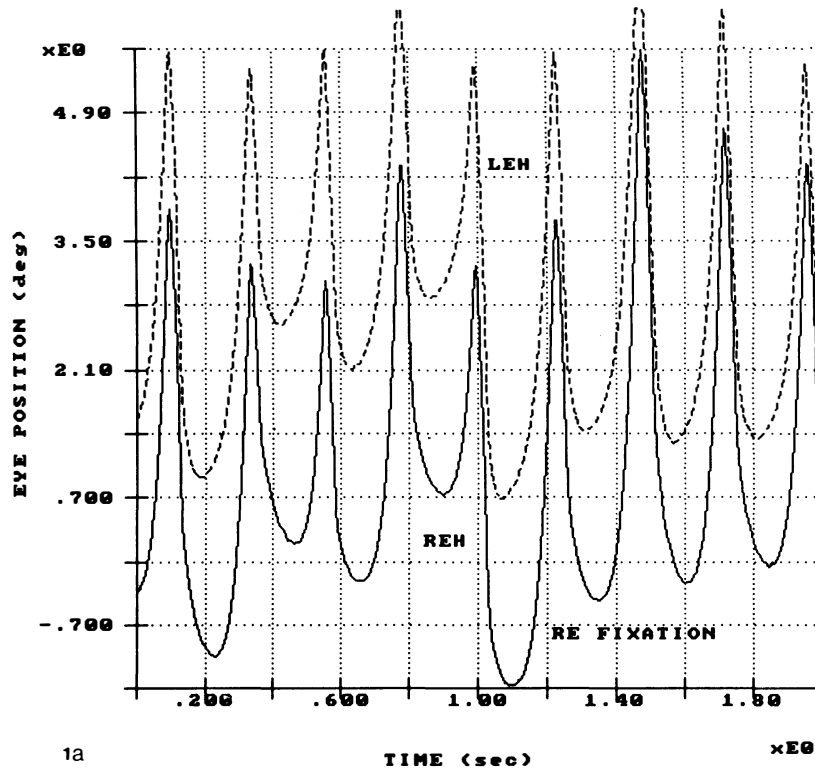
To calculate the SD of the CN waveform's foveation periods in a given interval of fixation, the point of minimum eye velocity (minimum slope) corresponding to the beginning of each slow phase was identified on the position record (foveation periods calculated in this way may not have actually resulted in accurate target foveation). These points (most easily identified on eye position records) were entered into an array using interactive graphics and the SD of foveation-period position was then calculated. To calculate the SD of foveation-period velocity, the velocities of the *same* points (previously identified on the position record) were read into an array using interactive graphics. The foveation-period time interval was calculated by subtracting the point when the eye speed fell to $4^\circ/\text{sec}$ from the point when it rose to that value; these intervals were identified on the velocity record using interactive graphics and the mean values were then calculated. Note again that foveation periods, so defined, may not correspond to when the image of the target of regard was on the fovea. For those waveforms whose phase-plane contours did not cross the velocity limit (slow-phase velocity $>4^\circ/\text{sec}$), the $\pm 0.5^\circ$ limits were used from the position record. Both methods allowed inclusion of foveation periods that fell outside the foveation window so that the statistics of these periods could be calculated. To calculate the total time per second (or per cycle) that the target was truly foveated, the eye-position and eye-velocity arrays were analyzed (using array mathematics) for all points when both the $\pm 0.5^\circ$ and $\pm 4^\circ/\text{sec}$ limits of the predefined foveation window were satisfied. If the eye-position records showed that all foveation periods of interest during an interval of fixation were well-developed (*i.e.*, they fell within the $\pm 0.5^\circ$ limits), the easier method using array mathematics was employed to calculate the position and velocity SD's.

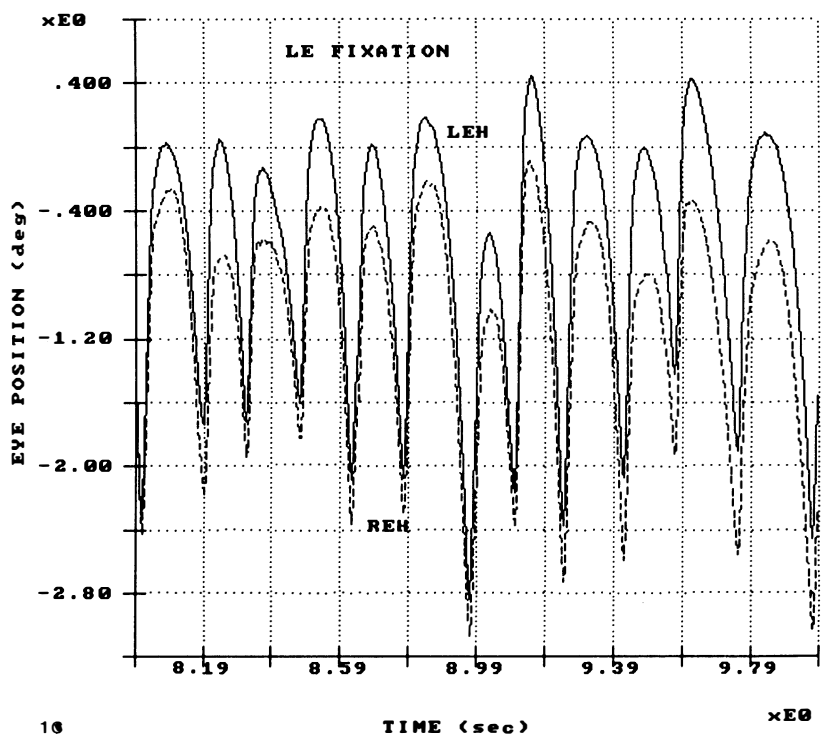
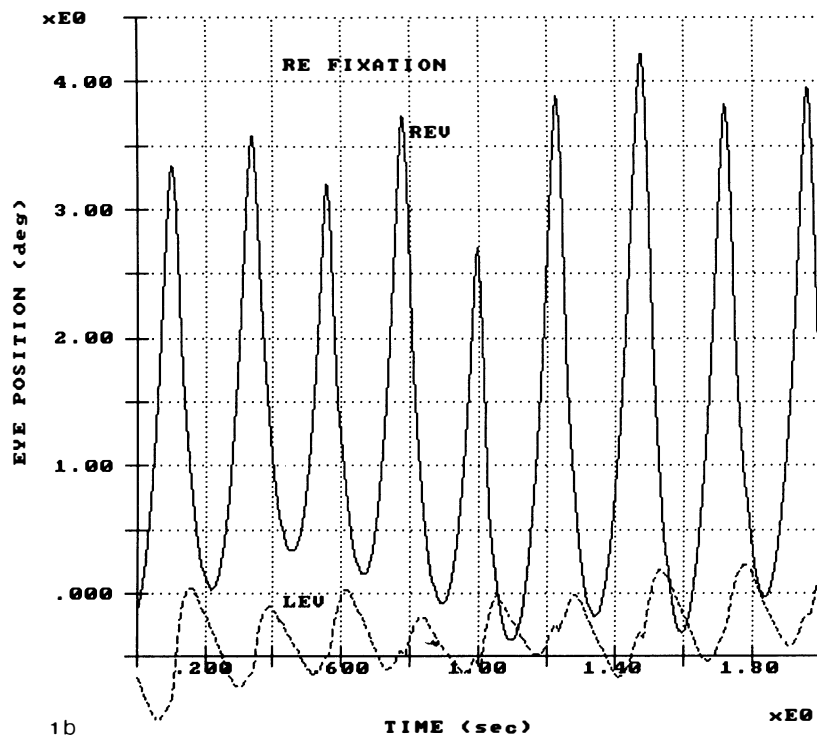
The use of *phase planes* in CN analysis first appeared in the study of foveation dynamics and was later applied in studying smooth pursuit and the

VOR in CN. Their utility lies in the simultaneous presentation of both eye (or retinal image) position and velocity. During fixation, this enables immediate identification of those periods when the target image is both stable and on the fovea. During smooth pursuit or VOR analysis, phase planes of retinal image motion identify those periods of gaze stability indicative of perfect pursuit or VOR. Further details on the use of phase planes may be found elsewhere^{15, 22, 23}. *Scan-path* plots (vertical vs horizontal motion) of both position and velocity allowed us to determine if the minima for eye position or velocity were synchronous in the horizontal and vertical planes. These and the phase planes combined to provide evidence of *simultaneous* satisfaction of the position and velocity criteria in both planes. *Conjugacy* plots (left eye vs right eye) for both the horizontal and vertical planes of motion demonstrated the relative amplitudes and phases of the motions of the two eyes.

RESULTS

Eye-movement recordings showed that the CN waveforms were pseudocycloid and pseudo-pendular at frequencies of 4-6 Hz²⁴. The nystagmus in the right eye was diagonal with approximately equal horizontal and vertical components but that of the left eye was mainly horizontal-elliptical. Fixation with the right eye (her normal condition) resulted in a jerk left CN (OU) with a downbeating component in that eye and a slightly upbeating component in the left eye. Forced fixation with the left eye (by occluding the right eye) resulted in a jerk right CN (OU) with a slightly downbeating component in that eye and a larger upbeating component in the right eye. Fig. 1 shows the relationships between the horizontal and vertical components of the





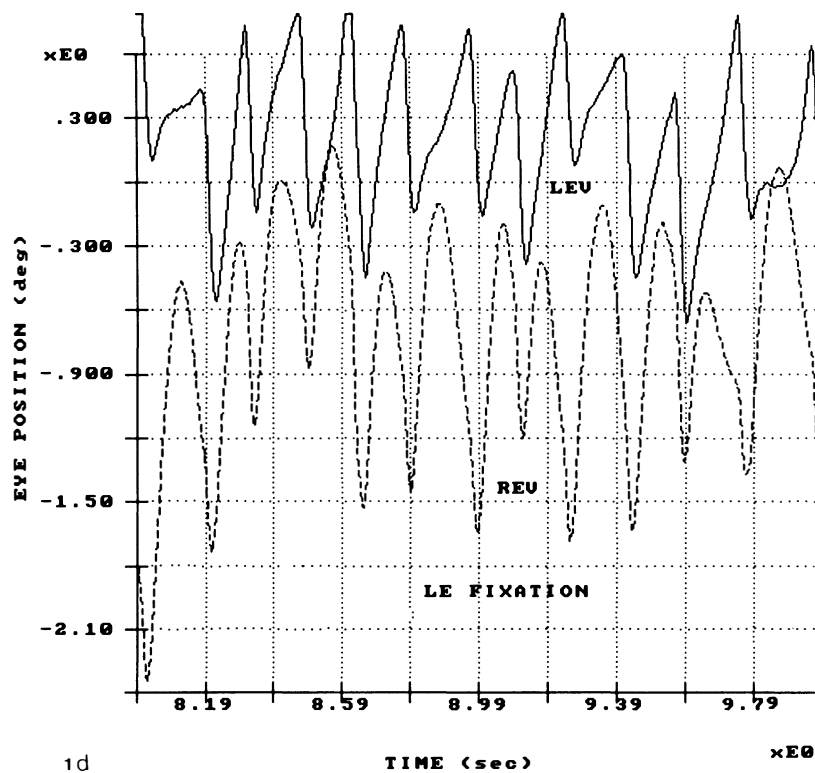


Fig. 1. Eye position vs time plots of 2 sec of fixation with the right (a, b) and left (c, d) eye. In each, both horizontal (H) and vertical (V) eye movements of both the right (RE) and left (LE) eye are shown. In both b. and d. the see-saw nature is evident from the vertical plots showing the downbeating fixing eye and the upbeatting suppressed eye; horizontally, the oscillation was a conjugate jerk left a. or jerk right c. nystagmus. In all figures, the positions of the non-fixating eye (when present) have been shifted for clarity and the above abbreviations apply.

nystagmus of both eyes during 2 sec of fixation with the right (Fig. 1a, b). or left (Fig. 1c, d) eye. Each part of Fig. 1 (a-d) shows *intereye* and *intraplane* differences. Regardless of which eye was fixating, the nystagmus in the right eye was diagonal while that of the left was mainly horizontal-elliptical with only a small vertical component. The amplitudes of both the horizontal and vertical components of the right eye and the horizontal component of the left eye were similar but that of the vertical component of the left eye was smaller. During right-eye fixation, the horizontal waveform of both eyes was left pseudocycloid and both eyes were in phase since the fast phases were synchronized (Fig. 1a). The vertical waveform of the right eye was a downbeating pseudocycloid but that of the left was an upbeatting jerk; the phase shift between the two eyes, again determined by the fast phases, varied from -90 to -180° (Fig. 1b). Some of the fast phases of the upbeatting left eye contained small downward saccades synchronized to the right-eye fast phases similar to the yoking effect seen during other disconjugate oscillations. During left-eye fixation, the horizontal waveform of both eyes was right pseudocycloid and both eyes were in

phase since the fast phases were synchronized (Fig. 1a). The vertical waveform of the right eye was a downbeating pseudocycloid but that of the left was an upbeatting jerk; the phase shift between the two eyes, again determined by the fast phases, varied from -90 to -180° (Fig. 1b). Some of the fast phases of the upbeatting left eye contained small downward saccades synchronized to the right-eye fast phases similar to the yoking effect seen during other disconjugate oscillations. During left-eye fixation, the horizontal waveform of both eyes was right pseudocycloid and both eyes were in

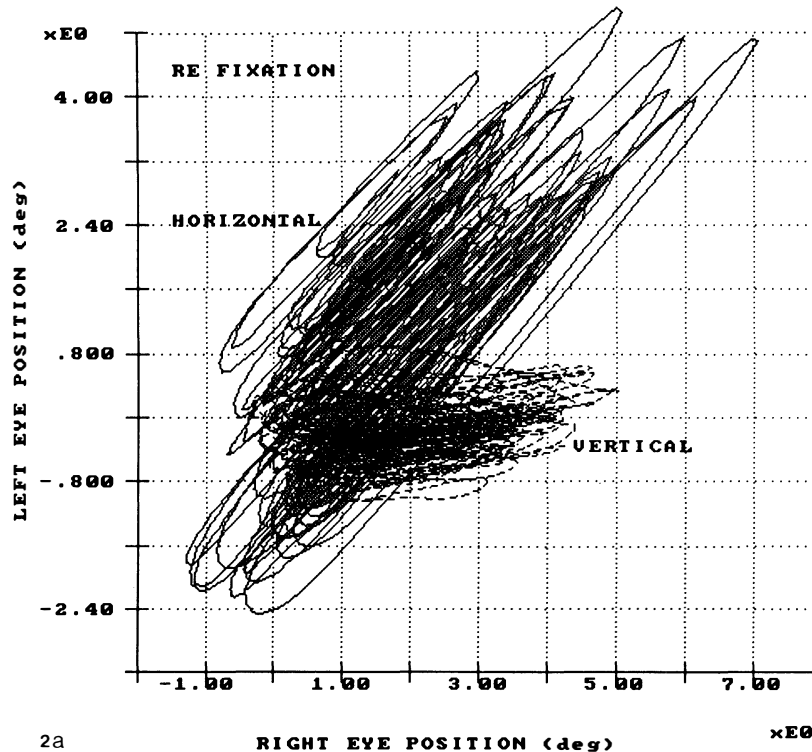
phase (Fig. 1c). The vertical waveform of the left eye was a downbeating jerk (with occasional dynamic overshoots) and that of the right was an upbeating jerk. The phase shift between the two eyes varied from -90 to -180° (Fig. 1d). In summary, this was a 4-6 Hz, diagonal, see-saw CN with a downbeating, *reversed* latent component in the fixating eye.

Right-eye fixation

The data taken when both eyes were unoccluded were the same as when the left eye was occluded since the subject preferred right-eye fixation. The conjugacy position plots shown in Fig. 2a compare the left and right eyes in both the horizontal and vertical planes during a 15-second record. The relatively straight lines at 45° shown

in the horizontal plots are equivalent to a 0° phase relationship between the right and left eyes. The horizontal ellipses shown in the vertical plot and the occasional straight lines at approximately 135° (seen in some records) indicate a phase relationship varying between -90 and -180° . The relative flatness of these ellipses is due to the small vertical component in the left eye. Fig. 2b is a scan path of the right eye taken at the cardinal positions and demonstrates that the nystagmus remained diagonal at these gaze angles. The fast phases brought the eye downward and to the left where target foveation occurred before the slow phases took the eye upwards and to the right.

To begin evaluating the foveation periods of the right eye during right eye fixation, we constructed phase portraits in both the horizontal



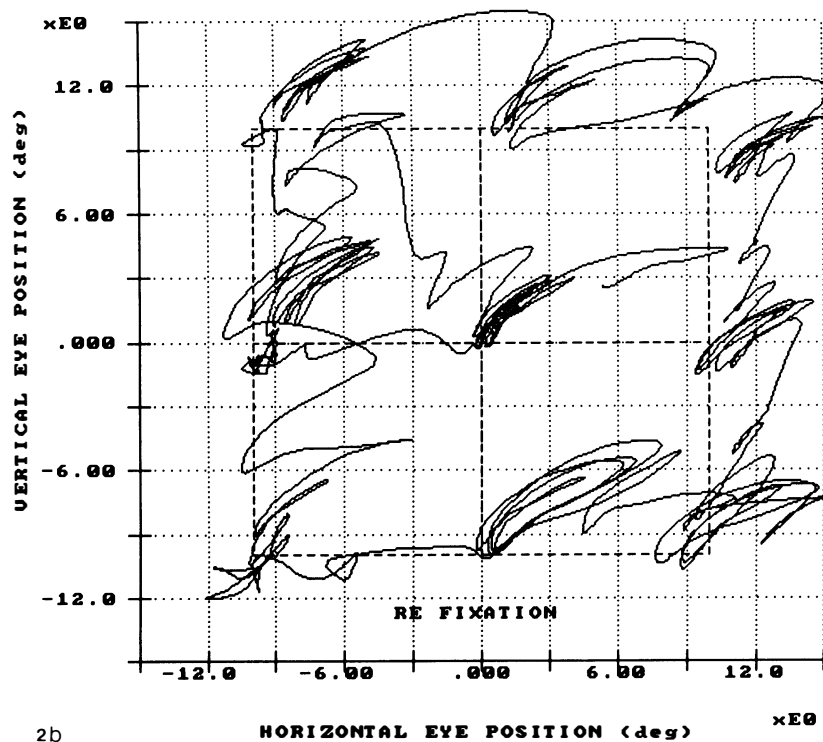


Fig. 2. a. Conjugacy position-plots (left vs right eye) in both the horizontal and vertical planes for 15 sec of fixation with the right eye, demonstrating the phase relationships between the right and left eye motions (0° in the horizontal plane and -90 to -180° in the vertical plane). The motion of the right eye was diagonal (equal horizontal and vertical motion) and that of the left was primarily horizontal-elliptical. b. Position scan path (vertical vs horizontal position) of the right eye at the cardinal gaze positions, demonstrating the consistent diagonal nature of the nystagmus in the right eye.

and vertical planes. Fixation segments ranging from 1.5 to 3 sec were analyzed separately. These segments did not include $1-2^\circ$ shifts in fixation that would falsely raise the calculated SD and obfuscate the graphical analyses. Such fixation shifts are common in untrained subjects who are merely asked to look at a small target and are not repeatedly urged to maintain perfect fixation. The shifts are easily identified in the records by occasional saccades that move the eyes off target where they remain for several CN cycles. Fig. 3 shows both the horizontal and vertical phase planes. The horizontal plot shows considerable scatter of foveation periods in and outside of the

foveation window. The large negative peak velocities on contours that start to the right of center and move the eye toward the left, reflect the downward and leftward saccades whereas the slow drift to the left through zero velocity and then towards a peak velocity of $90^\circ/\text{sec}$ to the right, are contours reflecting the upward and rightward slow phases of this nystagmus. The foveation periods occur as eye position goes from leftward to rightward and passes through $0^\circ/\text{sec}$. In comparison, the vertical phase plane contains much less position scatter and almost all of the foveation periods are within the foveation window throughout the 2 sec of fixation.

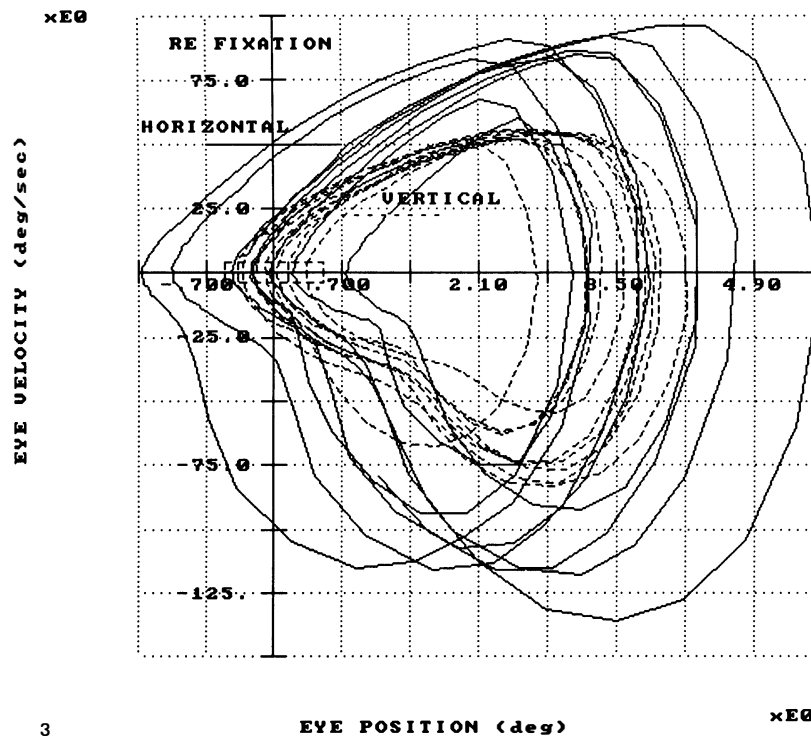


Fig. 3. Horizontal and vertical phase planes (eye velocity vs position) of the right eye during 2 sec of fixation with the right eye. There was more scatter of the foveation-period positions in the horizontal than vertical direction. In this and all other phase planes, the foveation window is located at the intersection of the axes and indicated by the rectangular area enclosed by the dashed lines demarking the predetermined position and velocity limits.

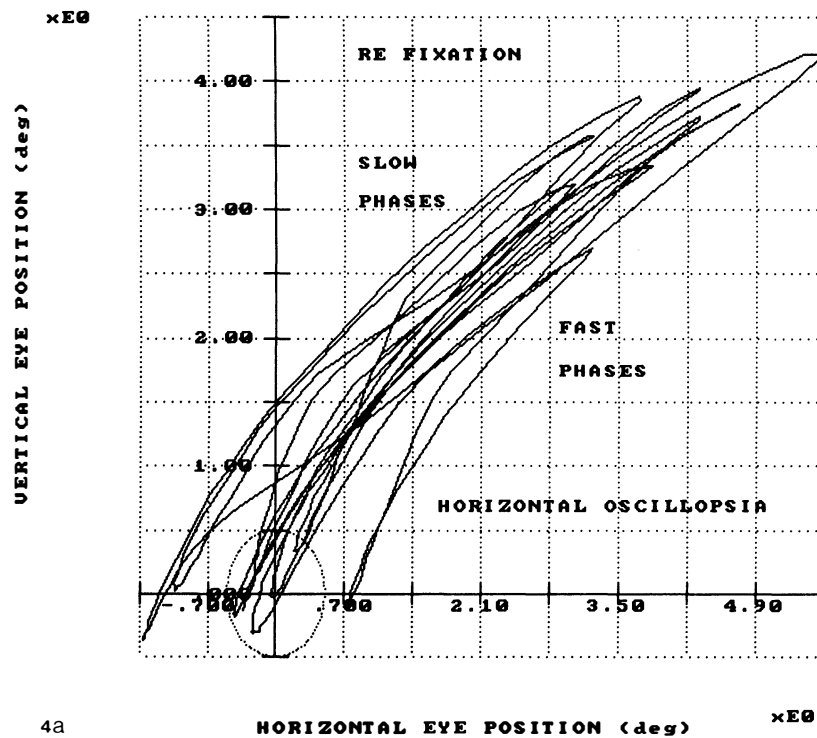
The phase planes allowed us to determine if position and velocity criteria were simultaneously met in a given plane; the determination of the simultaneous satisfaction of these criteria in *both* planes was accomplished by the use of scan paths for both position and velocity. Fig. 4a shows the position scan path during 2 sec of right-eye fixation demonstrating the diagonal nature of the nystagmus and the foveation periods falling in or around the probable center of the fovea (indicated on the figure by an ellipse of diameter 0.5°). Horizontal *position* scatter is evident since most of the foveation periods fall outside the ellipse. In Fig. 4b, the velocity scan path, there is a tight bundling of the slow phases pass-

ing through the 0,0 point. Thus, the velocity criteria were satisfied for all cycles in this 2-sec period of fixation. The $4^\circ/\text{sec}$ retinal slip velocity ellipse drawn on this figure encloses the tightly overlapping slow-phase trajectories through the window.

When we employed retinal image stabilization (RIS) of the target during right-eye fixation, there was no change in the perception of oscillopsia or of the nystagmus in both the horizontal and vertical planes.

Left-eye fixation

We also took data while the left eye was fixating



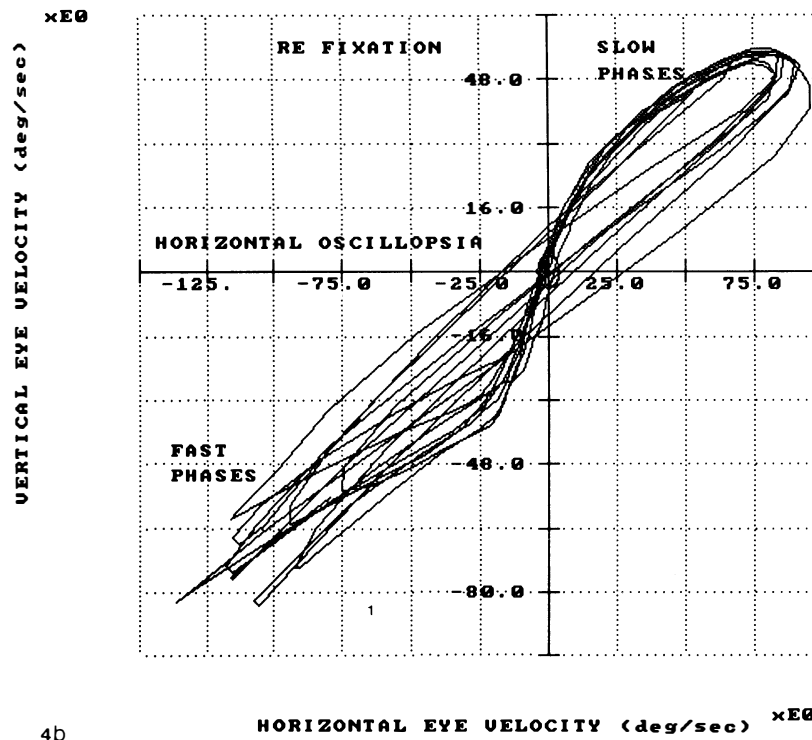
4a

(the right eye was occluded). The eye position waveforms during left-eye fixation were more variable than during the preferred right-eye fixation. Fig. 5 shows the conjugacy position plots in both planes during fixation with the left eye. Again, the right-eye CN was essentially diagonal and the left, primarily horizontal. Similar to the case when the right eye was fixating, the phase shift was approximately 0° in the horizontal plane and -90 to -180° in the vertical plane. The horizontal phase plane of the left eye (Fig. 6) showed some scatter of the foveation-period positions. However, as Fig. 6 also shows, the foveation-period velocity in the vertical direction never entered the foveation window. In Fig. 7a, which shows the counterclockwise elliptical eye trajectory, the position scatter of the foveation period is minimal and satisfies the position

criteria but Fig. 7b shows that the *velocity* criteria was not often satisfied during the foveation period; this is evidenced by the slow phases that lie outside the $4^\circ/\text{sec}$ retinal slip velocity ellipse.

Time relationships

Examination of the position vs time records, with both the horizontal- and vertical-plane data plotted on the same axes, revealed the time relationship of the foveation periods in the respective planes. Fig. 8a and 8b show *intraeye* and *interplane* differences. In Fig. 8a, which shows the horizontal and vertical motions of the right eye during right-eye fixation, it is evident that foveation periods (indicated by the small circles) almost always coincided and occurred as the eye slowed to zero velocity and reversed direction.



4b
 Fig. 4. Position a. and velocity b. scan paths of the right eye during 2 sec of fixation with the right eye. Horizontal position scatter is evident in a. but b. shows that the velocity criteria are satisfied. In this and the following position and velocity scan paths, the foveal area a. and retinal slip velocity criterion b. are shown by the superimposed ellipses at the intersection of the axes on the respective diagrams.

However, as Fig. 8b shows, during left-eye fixation the horizontal and vertical components of the left-eye motion did not contain foveation periods that were easily identified on the latter. More importantly, these horizontal foveation periods occurred *during* the vertical slow phases rather than at their beginning when low eye velocity could have been maintained to extend them. The x's in Fig. 8b indicate the positions in the vertical waveform where foveation periods would normally occur; for some cycles the slow phases were distorted to produce low-velocity foveation periods that coincided with those in the horizontal plane. The other segments of left-eye fixation also contained instances where horizon-

tal and vertical foveation periods did not coincide. The resulting high velocities of the target image crossing the fovea are shown in Figs. 6 (vertical) and 7b.

During one interval of right-eye fixation (Table 1, 1.5 sec), a similar asynchrony between the horizontal and vertical foveation periods occurred for some of the CN cycles. This resulted in the high SD for vertical velocity ($7.72^\circ/\text{sec}$) and may have caused some transient diagonal oscillopsia during this interval where, for most of the cycles, only horizontal variability was found. Thus, although Table 1 shows this as an interval of horizontal oscillopsia, it could be considered as one with both horizontal and diagonal oscil-

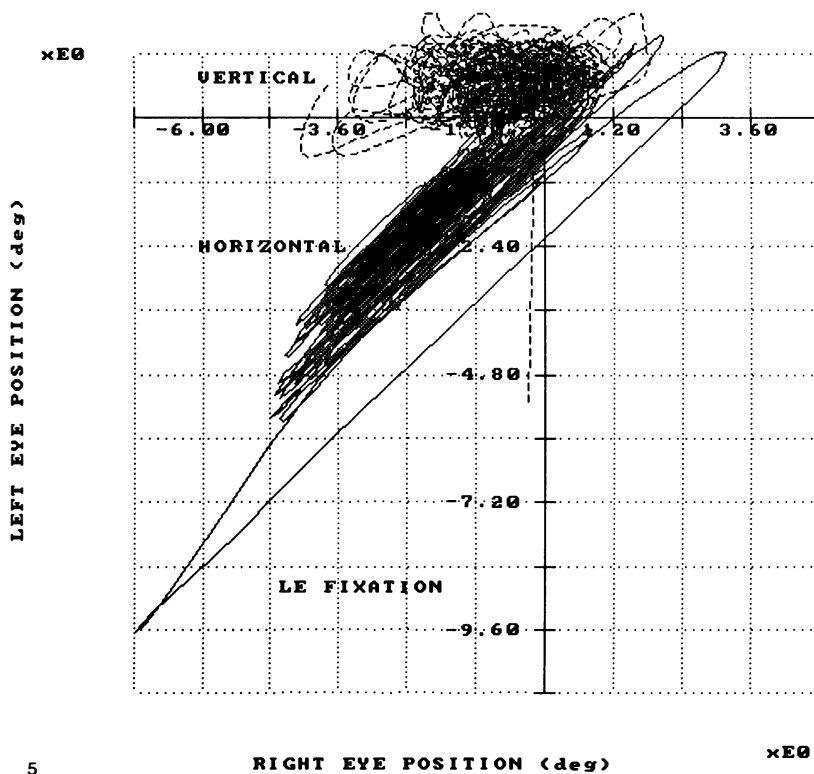


Fig. 5. Conjugacy position-plots (left vs right eye) in both the horizontal and vertical planes for 15 sec of fixation with the left eye, demonstrating the diagonal (equal horizontal and vertical motion) of the right eye and the primarily horizontal motion of the left. The phase relationships between the right and left eye motions are 0° in the horizontal plane and -90 to -180° in the vertical plane.

loppia. This would be consistent with the patient's reports of occasional diagonal oscillopsia during right-eye fixation.

Numerical analysis

Table 1 contains average values for the SD of foveation-period position and velocity as well as foveation-period duration in both planes for three intervals of fixation with either the right or left eye. In Tables 1 and 2, the oscillopsia directions shown are those that both matched the numerical or graphical variabilities found and remained constrained to the oscillopsia directions

reported and drawn by Subject 1 for fixation with each eye. For Subjects 2 and 3, the oscillopsia directions shown are those actually corresponding to each interval. We used the calculations summarized in Table 1 to identify the factors responsible for the occurrence of specific directions of oscillopsia when fixating with a particular eye. For comparison, the equivalent values are shown for two other subjects with purely horizontal CN; the first had transient horizontal oscillopsia and the second did not have oscillopsia^{14,15,17}. The values for all three subjects are comparable under the conditions when oscillopsia was suppressed as were the val-

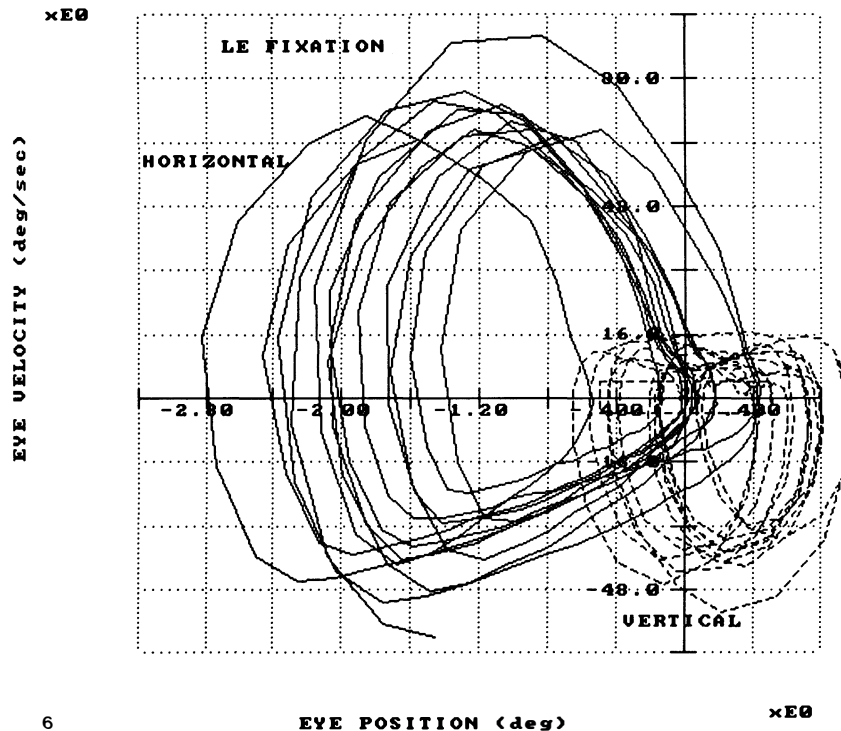


Fig. 6. Horizontal and vertical phase planes (eye velocity vs position) of the left eye during 2 sec of fixation with the left eye. Although there was some scatter of the horizontal foveation-period positions, the foveation-period velocities in the vertical direction did not enter the window.


ues for both subjects who experienced oscillopsia. These values of SD for both position and velocity were not directly related to the CN amplitudes in the planes for which they were measured.

During RE fixation, the average durations of the foveation periods in the horizontal plane were greater than in the vertical and they occurred at the beginnings of the slow phases. The SD of foveation-period position was greater in the horizontal than in the vertical plane and the SD of foveation-period velocities showed no plane specificity. During LE fixation, the average durations of the foveation periods in the vertical plane were greater than during RE fixation. The major factor determining oscillopsia direction appeared to be the occurrence of horizontal fo-

veation periods *during* the vertical slow phases; this resulted in high vertical-velocity SD's. Thus, during LE fixation, there was little chance for any extended foveation at low eye velocities in the vertical plane. Calculations comparing the timing of horizontal foveation periods with those points on the vertical CN waveforms where foveation periods *normally* occur (*i.e.*, at the start of the slow phases), yielded time differences ranging from 30 to 40 msec; this asynchrony precluded simultaneous foveation periods in both planes.

DISCUSSION

CN waveforms usually contain periods of low velocity that precede the slow phase accelera-



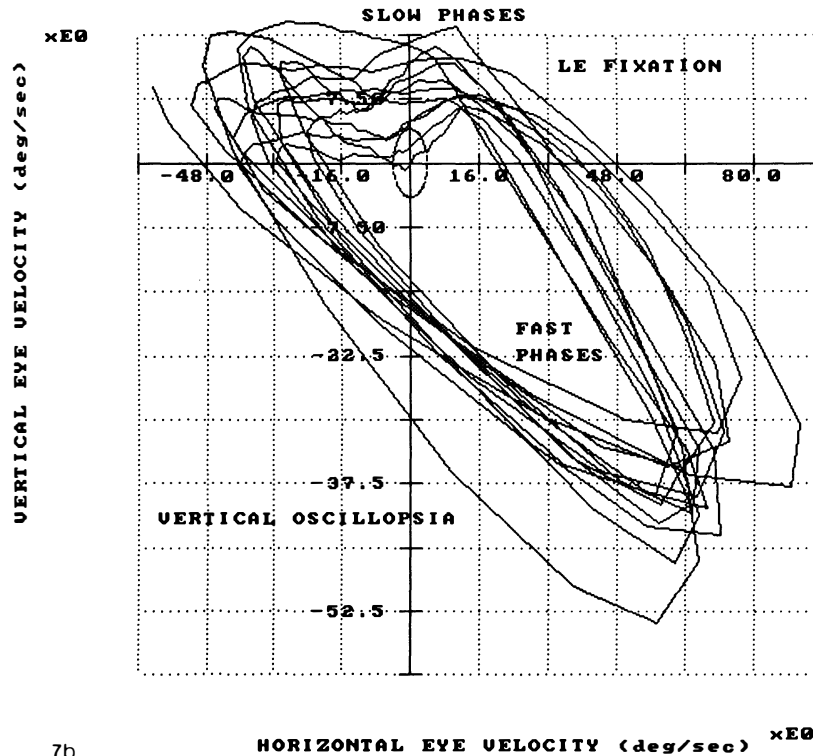
7a

tions away from the target. This fact was originally hypothesized based on the known cases of CN with high acuity; that would have been impossible if the CN was not biased to cause the oscillation to take the eyes away from and back to the target¹⁰. These periods were found in all non-transient (stable) CN waveforms and identified as *foveation periods*²⁴. They are easily identified by the flattened portions of each recorded CN cycle. Most individuals with CN do not experience oscillopsia because the foveation periods of their CN waveforms result in accurate target foveation. In individuals who do experience oscillopsia, some of the foveation periods do not satisfy the necessary criteria for accurate target foveation. Regardless of their accuracy, foveation periods of CN waveforms are the *critical* intervals during each cycle in which clear and

stable vision is possible; at all other times the retinal images are moving with high velocities and targets of interest are far from the fovea. However, this critical interval of both high acuity and visual stability does not prevent other visual input throughout the CN cycle, especially transient stimuli, such as brief flashes of light²⁵, or retinally stabilized images²⁶. Foveation periods allow clear and stable snapshots of vision superimposed on less-useful, continuous visual input that the brain processes by allowing for the eye-movement induced retinal image motion; they are *not* separated by long periods of no visual input.

Graphical analysis

Each of the graphical methods used in the analy-

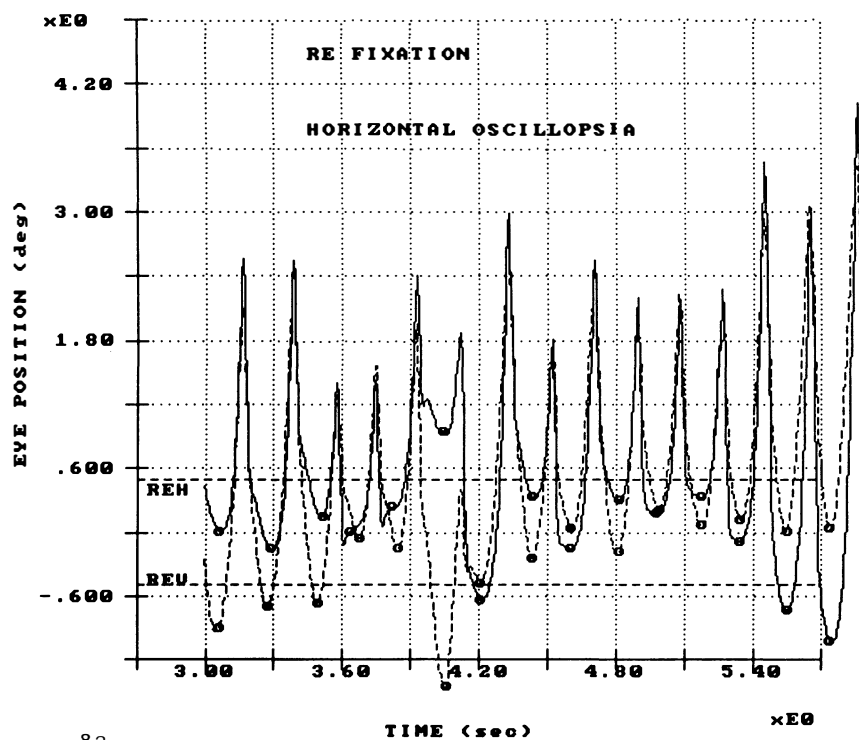


7b
 Fig. 7. Position a. and velocity b. scan paths of the left eye during 2 sec of fixation with the left eye. Little position scatter is evident in a. but b. shows that the vertical velocity criteria are not often satisfied during the foveation periods.

sis of this case provided a portion of the information required to identify the key factors in oscillopsia suppression. Phase planes provided the position and velocity of the eye in one plane and using them in each plane allowed us to determine if foveation periods were well developed in that plane. Scan paths (vertical vs horizontal motion) provided either the horizontal and vertical eye position or velocity. Simultaneous time plots of horizontal and vertical eye position allowed for the comparison of the time relationship between the respective foveation periods. When the phase plane and both the position and velocity scan paths satisfied their respective conditions in one plane, no oscillopsia resulted in that plane.

Table 2 summarizes our analysis of the differ-

ent graphical methods used to study the fixation characteristics of this subject and those of two other subjects with horizontal CN and, in one, transient oscillopsia. Where the foveation periods of the CN waveform did not always occur in the foveation window, the predominant plane of this 'scatter' is indicated. When the foveation periods were not repeatable and well-developed in both planes (for the subject of this report), the oscillopsia was diagonal for RE fixation and counterclockwise elliptical for LE fixation. As was first reported by Traccis *et al.*, elliptical nystagmus causes oscillopsia in the *same* direction (*i.e.*, clockwise or counter-clockwise) as the eye motion²⁷; in all other types of nystagmus, the oscillopsia is in the opposite direction to the slow



8a

eye motion.

Right-eye fixation

Analysis of the horizontal and vertical waveforms and their respective foveation periods during right-eye fixation revealed that there was horizontal *position* scatter of the foveation periods (high SD) that produced the horizontal oscillopsia. Thus, the different image positions on the retina during each foveation period presumably caused the illusion of horizontal movement. The horizontal scatter was shown in the phase planes (Fig. 3), position scan paths (Fig. 4a) and in the values in Table 1. The foveation-period velocities were within the velocity limits of the foveation window in both planes (Fig. 4b) as were the vertical trajectories (Figs. 3 and 4a and Table 1).

In addition, there was occasional vertical scatter that presumably resulted in a diagonal (upper right to lower left) oscillopsia. A high position or velocity SD can represent a transient variability in another plane (with accompanying oscillopsia) and not contribute to the predominant plane of the oscillopsia; this was the case in the 1.5 sec interval of Table 1. Because of the variability seen, several types of plots were required to demonstrate the different problems with foveation (*e.g.*, position or velocity errors in the horizontal or vertical planes). Vertical scatter in the absence of horizontal scatter was never seen.

Left-eye fixation

During left-eye fixation, both horizontal and vertical position scatter was usually within the

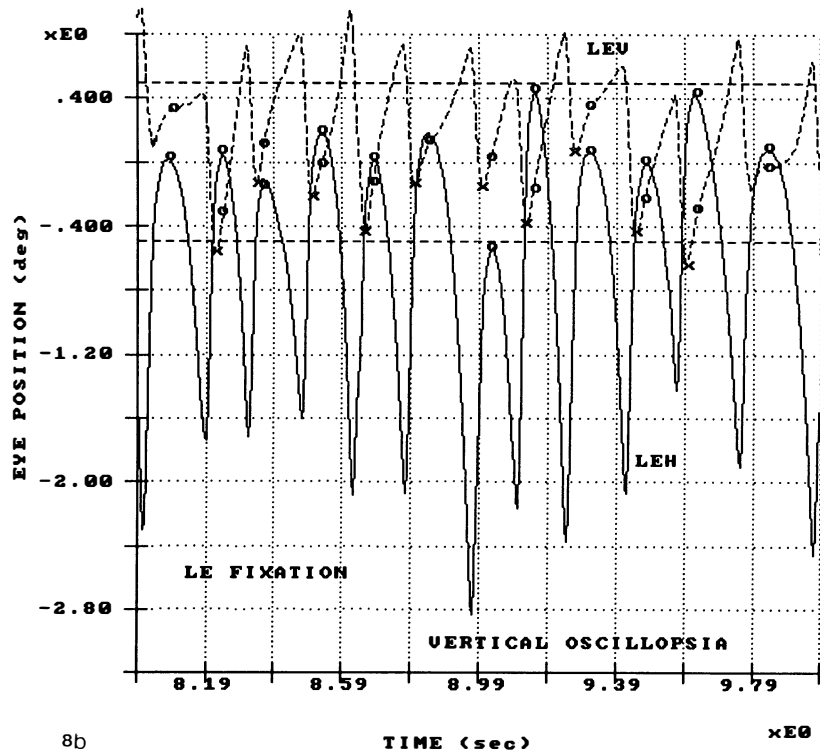


Fig. 8. Horizontal and vertical eye position vs time plotted on the same axes for both the right a. and left b. eyes during fixation with the right a. and left b. eyes respectively. During right-eye fixation a., the horizontal and vertical foveation periods coincided (overlapped) in time and occurred during the reversal of eye motion but during left-eye fixation b., the vertical foveation periods were not well defined by low-velocity intervals. The $\pm 0.5^\circ$ extent of the central fovea is indicated by the dashed lines, the foveation periods by small circles and, where different, the preferred vertical foveation-period positions by x's.

TABLE 1. Foveation period statistics

S	FE	T (s)	STANDARD DEVIATIONS				DURATION (ms)		OSOP
			POSITION ($^\circ$)		VELOCITY ($^\circ/s$)		H	V	
1	RE	3	.472	.499	.88	1.74	37.3	14	↔↕
	RE	1.5	.669	.266	2.01	7.72	44.2	15	
	RE	2	.620	.219	.604	1.45	31.9	16.2	
	LE	2	.307	.193	3.16	1.46	23.1	43.9	↕↔
	LE	2	.266	.427	1.63	3.39	20.0	88.3*	
	LE	2	.243	.226	1.40	2.99	19.2	103.3*	
2	RE	5	.723		7.46				↔
	RE	5	.244		1.87		114		
3	LE	5	.214		1.97		57		NONE

* position criteria used

S: subject




FE, RE, LE: fixating, right and left eye

T: time interval of fixation record

H: horizontal, V: vertical





OSOP: oscillopsia

TABLE 2. Foveation period graphics

S	FE	T (s)	FOVEATION PERIOD SCATTER				OSOP
			PHASE	PLANES	SCAN	PATHS	
			H	V	POS	VEL	
1	RE	3	YES	YES	H&V	NO	
	RE	1.5	YES	NO	H>V	NO	
	LE	2	YES	NG	NO	NG	
	LE	2	NO	NG	NO	NG	
2	RE	5	NG	NO			
	RE	5	NO	NO			
3	LE	5	NO	NO			NONE

S: subject
 T: time interval of fixation record
 POS: position
 NG: all data out of foveation window
 OSOP: oscillopsia
 FE, RE, LE: fixating, right and left eye
 H: horizontal, V: vertical
 VEL: velocity
 SCATTER: includes data in window

TABLE 3. Oscillopsia direction

Fixation	OSOP	Nystagmus		Fixating Eye Motion
		LE	RE	
RE	H > D			H ≈ V
LE	V > D			H > V

--> OSOP ≠ Fixating Eye Motion <--

H: horizontal, V: vertical, D: diagonal, OSOP: oscillopsia

position limits (Figs. 6 and 7a and Table 1) but there was a failure to meet the *velocity* criteria in the vertical plane (Figs. 6 and 7b), accompanied by high SD's and that presumably resulted in vertical oscillopsia. This necessitated the use of position criteria to determine foveation-period durations and yielded high values in the vertical plane (Table 1) despite the high eye velocity. When there was an additional horizontal position scatter, diagonal-elliptical (counterclockwise from lower right to upper left) oscillopsia that conformed to the CN waveform's trajectory could result. Horizontal scatter in the absence of vertical scatter was never seen. The importance of satisfying velocity as well as position criteria in the suppression of oscillopsia parallels that for

visual acuity in CN where a nystagmus foveation function has been suggested as a more sensitive acuity measure^{14, 15, 28, 29}. Although both foveation-period position and velocity variability may change together, this case shows that foveation-period velocity may vary without an accompanying position variability; such velocity variability can only degrade visual acuity and can cause oscillopsia.

Oscillopsia direction

Our previous study of oscillopsia accompanying CN involved a subject with purely horizontal CN who had two horizontal waveforms. During one CN waveform there were long (114 msec) periods of extended foveation when the image speed was less than 4°/sec¹⁷. The extent of vertical motion was so small that the whole slow-phase waveform remained within the foveation window during both horizontal waveforms. Horizontal foveation periods were always well-developed and no oscillopsia occurred. During the second waveform, in which no horizontal foveation periods were within the foveation window, oscillopsia occurred. During RIS, the periods of oscillopsia

continued to occur only during the second waveform. Since oscillopsia was directly related to the presence or absence of well-developed foveation periods and was in the plane of the CN, it was not possible to separate the CN oscillation itself from the variation in foveation periods as the main cause of the oscillopsia; nor was it possible to judge the relative effects of the position and velocity criteria.

Several studies in both normals and individuals with CN contain findings that may relate to oscillopsia suppression. In normals, oscillopsia may be perceived only when the 'normal' retinal image motion of an individual is exceeded³⁰⁻³². Although subjects with CN have sensitive differential velocity discrimination³³, one study suggests an elevated motion detection threshold³⁴ when compared to normals with still eyes. Since no comparison was made to normals under conditions of retinal image motion equivalent to CN, this may not reflect a true threshold elevation. Studies of saccadic suppression³⁵⁻³⁸ have not provided convincing evidence that the oscillopsia suppression in CN can be accounted for by the fast phases of the CN waveforms. These possibilities are more fully discussed in our previous paper¹⁷.

In the present subject, the CN had both horizontal and vertical components with short foveation periods (15-45 msec) that fell both inside and outside of the foveation window. This occurred in both planes on a beat-to-beat basis and in differing amounts, depending on the fixating eye. Table 3 illustrates the relationship between the relative preponderance of each oscillopsia direction (as she reported and drew) and her CN. With RE fixation, horizontal oscillopsia was more prevalent than diagonal despite the diagonal nature of the CN; vertical oscillopsia did not occur. With LE fixation, vertical oscillopsia was more prevalent than diagonal despite the

mainly horizontal-elliptical nature of the CN; horizontal oscillopsia did not occur. During RE fixation, her horizontal oscillopsia correlated with horizontal *position* variation; during LE fixation, her vertical oscillopsia correlated with vertical *velocity* variation. Thus, exceeding either the position or velocity criteria was sufficient to cause oscillopsia. During RE fixation, there was never a uniplanar vertical variation in foveation (position or velocity) and during LE fixation, there was never a uniplanar horizontal variation in foveation (position or velocity). The condition of a uniplanar variation in foveation without the corresponding uniplanar oscillopsia did not exist. When only uniplanar variation in foveation periods was found, the oscillopsia was in that same plane and was independent of the major plane of the CN oscillation. When foveation-period variation was in both planes, the oscillopsia was also biplanar and conformed to the CN waveform. Thus, when well-developed foveation periods existed in one plane only, the oscillopsia in the other plane was caused by the variation in those foveation periods and only when no well-developed foveation periods existed in either plane, was the oscillopsia determined by the CN waveform. As we found for the previous subject, RIS did not affect the perception of oscillopsia.

Normally, CN is mainly horizontal with a small torsional component and any oscillopsia that might be present or induced under laboratory conditions is also horizontal. Acquired conditions that alter the horizontal CN waveform can cause horizontal oscillopsia¹⁷. From this, it might be expected that a diagonal CN should cause diagonal oscillopsia; this is not always the case, as shown in the present study. The plane of any oscillopsia present is only secondarily dependent on the plane of the CN; the primary factor is the plane of the beat-to-beat variation

in either the foveation-period positions or velocities of image slip across the fovea. Although they may be directly related to the relative amplitudes of the CN in each plane, they need not be. Thus, a predominantly horizontal CN can (and in this case, did) produce a primarily vertical oscillopsia. When there is motion in more than one plane, the SD of both foveation-period position and velocity must fall within the foveation window in both the horizontal and vertical planes and these well-developed foveation periods must occur simultaneously if oscillopsia is to be suppressed in both planes. Failure to satisfy these stringent conditions results in oscillopsia in either or both planes. Stress is known to intensify CN and it is under these conditions that oscillopsia may be experienced by some individuals with CN. We can now infer that such stress also results in less accurate control of the foveation periods. The absolute size of the foveation window may vary in individuals³⁹, especially if there are foveal malformations⁴⁰, and when that variability is increased, oscillopsia may result.

Foveation-period duration

Since the durations of the foveation periods were lower in this subject than those previously studied (Table 1), there is the possibility that, at times, they fell below some minimum value necessary for perceptual stability¹⁹. However, the perception of horizontal oscillopsia with RE fixation (despite the 14-15 msec durations of vertical foveation periods) and vertical oscillopsia with LE fixation (despite the 19.2-20.0 msec durations of horizontal foveation periods) argues against this possibility. Previous studies show that many individuals with CN and no oscillopsia have foveation periods on the order of 30 msec. The data from this study suggest that the minimum duration of well-developed foveation

periods, below which oscillopsia would occur, may be less than approximately 15 msec. Although such low foveation-period durations would cause an acuity deficit, they appear to be sufficient for the suppression of oscillopsia; poor acuity does not cause oscillopsia in individuals with or without CN.

In our studies of oscillopsia in subjects with CN and normal foveal function, we used the stability of their CN foveation periods as the best measure of their ability to stabilize *all* retinal images. When an image of a target of interest is stable on the fovea, all images in the visual field are likewise stable on the retina. Similarly, the position and velocity SD's of the foveation periods apply equally to the rest of the retina since the whole retina moves in unison with the fovea. The fovea is not preferentially sensitive to motion detection or oscillopsia suppression. Patients with poor foveas are not more likely to be unable to suppress oscillopsia due to nystagmus. Although the foveation periods of their CN may be less stable, their threshold for oscillopsia may also be elevated; we cannot predict the size of their foveation windows from studies of those with good foveal function. We have not found our CN patients with amblyopia, eccentric fixation or macular degeneration to exhibit oscillopsia. This suggests that either they can maintain low SD's during their foveation periods or they have an elevated threshold for oscillopsia.

CONCLUDING REMARKS

We also performed an analysis of the presence/absence of repeatable, well-developed foveation periods and the presence/absence of oscillopsia using symbolic logic. The results, presented elsewhere⁴¹, yielded a truth table for our data that was the same as that for an equivalence relationship (*i.e.*, if and only if or, necessary and suffi-

cient). Translating those results back to their original statements: if and only if there are repeatable, well-developed foveation periods then there will be visual stability (oscillopsia suppression). This applies to each plane of the ocular motor oscillation and the requirement must be met in both planes *simultaneously* to allow visual constancy in both planes.

The ocular motor system of individuals with CN has proven to be a valuable model for the study of both normal and acquired pathological ocular motor instabilities. Despite the presence of nystagmus, fixation^{14, 15, 39, 42}, saccades^{38, 43}, pursuit^{22, 44-53} and VOR^{23, 48, 52, 54} are within normal limits and allow the full range of ocular motility necessary for both the tasks required of the ocular motor system and the prevention of the perception of oscillopsia. A recent study of pursuit in normals under imposed conditions of a sampled visual input showed how the pursuit system's performance was affected by both sampling frequency and duration⁵⁵. For sampling durations equivalent to those imposed on the pursuit system of individuals with CN by their

foveation periods but at sampling frequencies (0.32-0.96 Hz) well below those of CN waveforms (3-5 Hz), pursuit was slightly below normal. It is reasonable to extrapolate those results upward if sampling frequencies were increased to those usually found in CN. Thus, this study of normals whose pursuit systems were operating with a sampled visual input confirms previous studies showing that the pursuit system in CN is normal.

In cases where an acquired condition is superimposed on the CN, it is now possible to separate the eye movements of the former from the CN and determine the characteristics of the motility deficits that lead to the perception of oscillopsia^{17, 19}. Further studies are underway applying these results to the alleviation of oscillopsia in AN.

ACKNOWLEDGEMENTS

The authors wish to thank Dr. Gregory Kosmorsky for referring patients for this study. We gratefully acknowledge Ms. Andrea Hogan for help in preparing the manuscript.

REFERENCES

1. Brickner R. Oscillopsia: New symptom commonly occurring in multiple sclerosis. *Arch Neurol Psychiat* 1936; 36:586.
2. Bender MB. Oscillopsia. *Arch Neurol* 1965; 13:204-213.
3. Katims JJ, Long DM, Ng LKY. Transcutaneous nerve stimulation: frequency and waveform specificity in humans. *Appl Neurophysiol* 1986; 49:86-91.
4. Lackner JR, Zabkar JJ. Proprioceptive information about target location suppresses autokinesis. *Vision Res* 1977; 17:1225-1229.
5. Goddé-Jolly D, Lanthony MP. Nystagmus congénital: étude de l'oscillopsie des objets réels et des post-images. *Bull Soc Ophthalmol Fr* 1971; 71:863-972.
6. Goddé-Jolly D, Larmande A. *Les Nystagmus*. Paris: Masson & Co 1973.
7. Kommerell G. Congenital nystagmus: control of slow tracking movements by target offset from the fovea. *Graefes Arch Clin Exp Ophthalmol* 1986; 224:295-298.
8. Dell'Osso LF, Leigh RJ. Oscillopsia and retinal image stabilization in congenital nystagmus. *Invest Ophthalmol Vis Sci (ARVO Suppl)* 1987; 28:34.
9. Leigh RJ, Dell'Osso LF, Yaniglos SS, Thurston SE. Oscillopsia, retinal image stabilization and congenital nystagmus. *Invest Ophthalmol Vis Sci* 1988; 29:279-282.
10. Dell'Osso LF. Fixation characteristics in hereditary congenital nystagmus. *Am J Optom Arch Am Acad Optom* 1973; 50:85-90.

11. Grossman GE, Leigh RJ, Bruce EN, Huebner WP, Lanska DJ. Performance of the human vestibuloocular reflex during locomotion. *J Neurophysiol* 1989; 62:264-272.
 12. Abel LA, Traccis S, Dell'Osso LF, Ansevin CF. Variable waveforms in downbeat nystagmus imply short-term gain changes. *Ann Neurol* 1983; 13:616-620.
 13. Lavin PJM, Traccis S, Dell'Osso LF, Abel LA, Ellenberger Jr C. Downbeat nystagmus with a pseudocycloid waveform: improvement with base-out prisms. *Ann Neurol* 1983; 13:621-624.
 14. Dell'Osso LF, Van der Steen J, Collewijn H, Steinman RM. Foveation dynamics in congenital nystagmus. *Invest Ophthalmol Vis Sci (ARVO Suppl)* 1988; 29:166.
 15. Dell'Osso LF, Van der Steen J, Steinman RM, Collewijn H. Foveation dynamics in congenital nystagmus: I. Fixation. *Doc Ophthalmol* 1992; 79:1-23.
 16. Dell'Osso LF, Leigh RJ. Foveation periods and oscillopsia in congenital nystagmus. *Invest Ophthalmol Vis Sci (ARVO Suppl)* 1990; 31:122.
 17. Dell'Osso LF, Leigh RJ. Foveation period stability and oscillopsia suppression in congenital nystagmus: an hypothesis. *Neuro-ophthalmology* 1992; 12:169-183.
 18. Abel LA, Williams IM, Levi L. Oscillopsia suppression in congenital nystagmus: dependence on foveation stability and duration. *Invest Ophthalmol Vis Sci (ARVO Suppl)* 1990; 31:122.
 19. Abel LA, Williams IM, Levi L. Intermittent oscillopsia in a case of congenital nystagmus. Dependence upon waveform. *Invest Ophthalmol Vis Sci* 1991; 32:3104-3108.
 20. Leigh RJ, Rushton DN, Thurston SE, Hertle RW, Yaniglos SS. Effects of retinal image stabilization in acquired nystagmus due to neurological disease. *Neurology* 1988; 38:122-127.
 21. Hary D, Oshio K, Flanagan SD. The ASYST software for scientific computing. *Science* 1987; 236:1128-1132.
 22. Dell'Osso LF, Van der Steen J, Steinman RM, Collewijn H. Foveation dynamics in congenital nystagmus: II. Smooth pursuit. *Doc Ophthalmol* 1992; 79:25-49.
 23. Dell'Osso LF, Van der Steen J, Steinman RM, Collewijn H. Foveation dynamics in congenital nystagmus: III. Vestibulo-ocular reflex. *Doc Ophthalmol* 1992; 79:51-70.
 24. Dell'Osso LF, Daroff RB. Congenital nystagmus waveforms and foveation strategy. *Doc Ophthalmol* 1975; 39:155-182.
 25. Jin YH, Goldstein HP, Reinecke RD. Absence of visual sampling in infantile nystagmus. *Invest Ophthalmol Vis Sci (ARVO Suppl)* 1989; 30:50.
 26. Gottlob I, Goldstein HP, Fendick MG. Visual remapping in patients with infantile nystagmus. *Invest Ophthalmol Vis Sci (ARVO Suppl)* 1990; 31:602.
 27. Traccis S, Rosati G, Monaco MF, Aiello I, Agnetti V. Successful treatment of acquired pendular elliptical nystagmus in multiple sclerosis with isoniazid and base-out prisms. *Neurology* 1990; 40:492-494.
 28. Dell'Osso LF. Eye movements, visual acuity and spatial constancy. *Neuro-ophthalmology* 1991; 11:151-156.
 29. Dell'Osso LF. Eye movements, visual acuity and spatial constancy. *Acta Neurol Belg* 1991; 91:105-113.
 30. Steinman RM, Collewijn H. Binocular retinal image motion during active head rotation. *Vision Res* 1980; 20:415-429.
 31. Steinman RM, Levinson JZ, Collewijn H, Van der Steen J. Vision in the presence of known natural retinal image motion. *J Opt Soc Am A* 1985; 2:226-233.
 32. Steinman RM, Cushman WB, Martins AJ. The precision of gaze. *Human Neurobiol* 1982; 1:97-109.
 33. Kommerell G, Horn R, Bach M, Keller EL, Zee DS. Motion perception in congenital nystagmus. In: *Adaptive Processes in Visual and Oculomotor Systems*. Oxford: Pergamon Press 1986; 485-491.
 34. Brandt T, Dieterich M, Kennard C, Rose FC. Oscillopsia and motion perception. In: *Physiological Aspects of Clinical Neuro-ophthalmology*. London: Chapman and Hall 1988; 321-339.
 35. Latour PL. Visual threshold during eye movements. *Vision Res* 1962; 2:261-262.
 36. Li W, Matin L. Saccadic suppression of displacement: influence of postsaccadic exposure duration and of saccadic stimulus elimination. *Vision Res* 1990; 30:945-955.
 37. O'Regan JK, Lévy Schoen A. Integrating visual information from successive fixations: does transsaccadic fusion exist? *Vision Res* 1983; 23:765-768.
 38. Worfolk R, Abadi RV. Quick phase programming and saccadic re-orientation in congenital nystagmus. *Vision Res* 1991; 31:1819-1830.
 39. Bedell HE, White JM, Abplanalp PL. Variability of foveations in congenital nystagmus. *Clin Vision Sci* 1989; 4:247-252.
 40. Abadi RV, Pascal E, Whittle J, Worfolk R. Retinal fixation behavior in human albinos. *Optom Vis Sci* 1989; 66:276-280.
 41. Dell'Osso LF, Leigh RJ. Required ocular motor conditions for visual constancy. *Invest Ophthalmol Vis Sci (ARVO Suppl)* 1991; 32:901.
-

42. Reinecke RD, Suqin G, Goldstein HP. Waveform evolution in infantile nystagmus: an electro-oculographic study of 35 cases. *Binoc Vision* 1988; 3: 191-202.
43. Bedell HE, Abplanalp PL, McGuire CA. Oculomotor responses to target displacements by patients with congenital idiopathic nystagmus and nystagmus associated with albinism. *Clin Vision Sci* 1987; 2: 21-31.
44. Dell'Osso LF. A Dual-Mode Model for the Normal Eye Tracking System and the System with Nystagmus. Ph.D. Dissertation. University of Wyoming, January 1968.
45. Dell'Osso LF, Gauthier G, Liberman G, Stark L. Eye movement recordings as a diagnostic tool in a case of congenital nystagmus. *Am J Optom Arch Am Acad Optom* 1972; 49: 3-13.
46. Halmagyi GM, Gresty MA, Leech J. Reversed optokinetic nystagmus (OKN): mechanism and clinical significance. *Ann Neurol* 1980; 7: 429-435.
47. Gresty MA, Ell JJ. Spasmus nutans or congenital nystagmus? Classification according to objective criteria. *Br J Ophthalmol* 1981; 65: 510-511.
48. Dell'Osso LF. Evaluation of smooth pursuit in the presence of congenital nystagmus. *Neuro-ophthalmology* 1986; 6: 383-406.
49. Dell'Osso LF. A model for the horizontal tracking system of a subject with nystagmus. *Proc 20th Ann Conf Eng Med Biol* 1967; 9: 24.2.
50. Dell'Osso LF. A dual-mode model for the normal eye tracking system and the system with nystagmus. *IEEE Trans Biomed Engin BME-17* 1970; 87.
51. Dell'Osso LF, Abel LA. The smooth pursuit system in CN is normal. *Invest Ophthalmol Vis Sci (ARVO Suppl)* 1985; 26: 46.
52. Kurzan R, Büttner U. Smooth pursuit mechanisms in congenital nystagmus. *Neuro-ophthalmology* 1989; 9: 313-325.
53. Dell'Osso LF, Van der Steen J, Collewijn H, Steinman RM. Pursuit and VOR dynamics in congenital nystagmus. *Invest Ophthalmol Vis Sci (ARVO Suppl)* 1989; 30: 50.
54. Gresty MA, Barratt HJ, Page NG, Ell JJ. Assessment of vestibulo-ocular reflexes in congenital nystagmus. *Ann Neurol* 1985; 17: 129-136.
55. Barnes GR, Asselman PT. The mechanism of prediction in human smooth pursuit eye movements. *J Physiol* 1991; 439: 439-461.