

Torsional, see-saw, 'bow-tie' nystagmus in association with brain stem anomalies

JOSEPH D. WEISSMAN^{1*}, SCOTT H. SEIDMAN^{1,3}, LOUIS F. DELL'OSSO^{1,3},
MOHAMMAD H. NAHEEDY² and R. JOHN LEIGH^{1,3}◇

Departments of ¹Neurology, ²Radiology and ³Biomedical Engineering, VA Medical Center and University Hospitals, Case Western Reserve University, Cleveland, OH 44106, USA

ABSTRACT. The authors report a patient with syringomyelia, syringobulbia, and the Arnold-Chiari malformation who was noted clinically to have torsional nystagmus. Measurement of the nystagmus using the magnetic search coil technique revealed a mixed torsional, see-saw, 'bow-tie' waveform. It is postulated that a disturbance of central vestibular connections was the common pathogenesis for all components of the nystagmus.

Key words: nystagmus; Arnold-Chiari malformation; syrinx; magnetic search coil

INTRODUCTION

Torsional nystagmus that lacks any appreciable horizontal component is usually due to disease affecting central vestibular connections¹. Hemi-see-saw nystagmus, in which one eye rises and intorts while the other eye falls and extorts, followed by a corrective quick phase, is reported with a variety of brain stem lesions²⁻⁵ and may reflect disruption of central otolithic connections. In certain forms of vertical nystagmus occurring in primary position, quick phases are oblique with horizontal components alternating to the right or left. This is known as 'bow-tie nystagmus'⁶. We report a patient with a combi-

nation of these three forms of nystagmus who had brain stem anomalies.

CASE REPORT

A 46-year-old white man presented with the complaint of increasing weakness and sensory loss in the right arm. In 1964, he had a right facial palsy which resolved over several months. In 1984, he had the onset, over several hours, of visual blurring of the right eye which resolved over six months. In 1985, he experienced right-sided headaches without visual accompaniment, photophobia, or nausea. Because of persisting motor and sensory disturbance in his right arm, a myelogram was performed, which showed right C5-6 and C6-7 root sheath impingement. An EMG showed decreased conduction velocity in the right ulnar nerve without evidence of conduction block. In March 1986, the patient underwent a C5-6 and C6-7 foraminotomy and discectomy with some relief of symptoms. In September 1988, however, the headaches returned and he began having loss of sensation and paresthesias in his right hand, difficulty with writing, and inability to

* *Present address:* Department of Neurology, Emory University, 1365 Clifton Road N.E., Atlanta, GA 30322, USA

◇ *Correspondence to:* R. John Leigh, M.D., Department of Neurology, University Hospitals of Cleveland, 2074 Abington Road, Cleveland, OH 44106, USA

use fine tools. He also complained of being increasingly hoarse, and having difficulty in swallowing. On 15 May 1989 he came to our clinic for further evaluation.

Visual acuity was 20/25 OD and 20/20 OS with correction. Eye movements were full in range but a torsional nystagmus, with quick phases that were clockwise with respect to the patient, were noted on right gaze. He had a slight weakness of the right face with a synkinesis of the right orbicularis oculi and orbicularis oris. Myokymia of the right platysma was present. Indirect laryngoscopy showed paralysis of the right vocal cord. He had a moderate sensory loss to pin over the lower right face and neck with perioral sparing. This region of sensory loss extended down to the right shoulder and arm. In addition, there was an area of dense sensory loss along the dorsum of the hand, in the ulnar sensory distribution. Sensation was normal on the rest of the body. A Tinel's sign was present over the right ulnar nerve at the elbow. There was mild weakness of the right deltoid, triceps, biceps, brachioradialis, wrist flexors, and extensors, and abductor pollicis brevis. Muscles supplied by the right ulnar nerve were weak with severe atrophy of the right hypothenar eminence and a right claw-hand posture.

Laboratory studies demonstrated normal B12, folate, and VDRL. The chest X-ray showed chronic interstitial changes. EMG and nerve conduction studies showed a severe right ulnar mononeuropathy at the elbow with 50% conduction block and slowing of conduction velocity. The needle examination showed decreased recruitment of the right biceps brachii. Sagittal magnetic resonance images of the head and spine showed a mild Arnold-Chiari malformation with a syringomyelia cavity extending down to T7-8. Syringobulbia was present in the form of cleft-like areas of decreased signal on T1-weighted axial images (Fig. 1).

Horizontal, vertical, and torsional rotations of each eye were recorded using the magnetic search coil method⁷. A typical record is shown in Fig. 2. A low-amplitude, conjugate, torsional, clockwise, jerk nystagmus is evident, as is a conjugate, alternating, horizontal saccadic component. In addition, a hemi-see-saw nystagmus is present with slow phases directed counterclockwise, upward in the right eye and downward in the left eye. No horizontal component was present for nystagmus slow phases. Left eye quick phases were directed diagonally upward (alternating right and left), and they always had a clockwise torsional component.

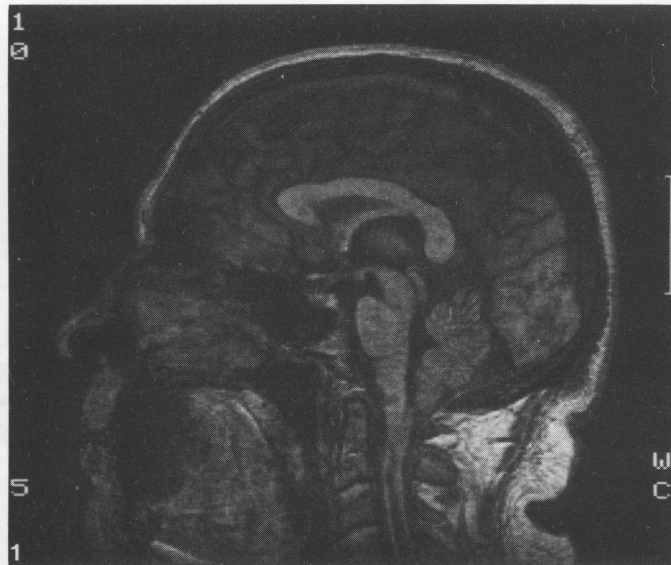
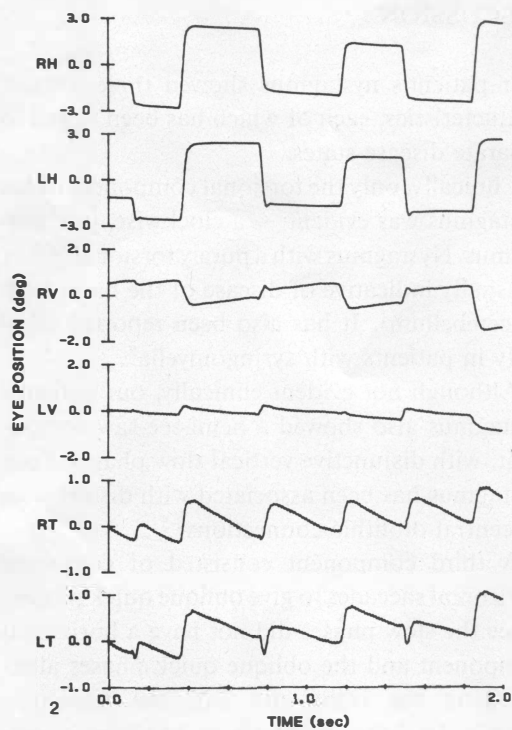


Fig. 1. Parasagittal MRI scan showing syringomyelia, syringobulbia, and Arnold-Chiari malformation.

Fig. 2. Magnetic search coil record of patient's nystagmus (see text for details). RH: horizontal position of right eye; LH: horizontal position of left eye; RV: vertical position of right eye; LV: vertical position of left eye; RT: torsional position of right eye; LT: torsional position of left eye. Upward deflections indicate eye rotations to the right, upward, or clockwise with respect to the patient.



Right eye quick phases were directed diagonally down (alternating right and left), also with a clockwise torsional component. Thus, the fast phases were horizontally and torsionally conjugate, but vertically disconjugate (right eye up, left eye down). On the other hand, the slow phases were torsionally conjugate, vertically disconjugate, but lacked any horizontal component. The resulting movements, which traced a 'bow-tie', are shown schematically in Fig. 3. The left eye traced a typical upbeat, bow-tie waveform as described by Sibony *et al.*⁶, but the right eye had a downbeat, bow-tie waveform. This nystagmus was slightly increased on right gaze, but was present in all gaze angles. It was little changed in darkness, but was suppressed by viewing a near target. Otherwise, saccades, smooth pursuit, and the vestibulo-ocular reflex in horizontal and vertical planes were preserved. There was no internuclear ophthalmoplegia.

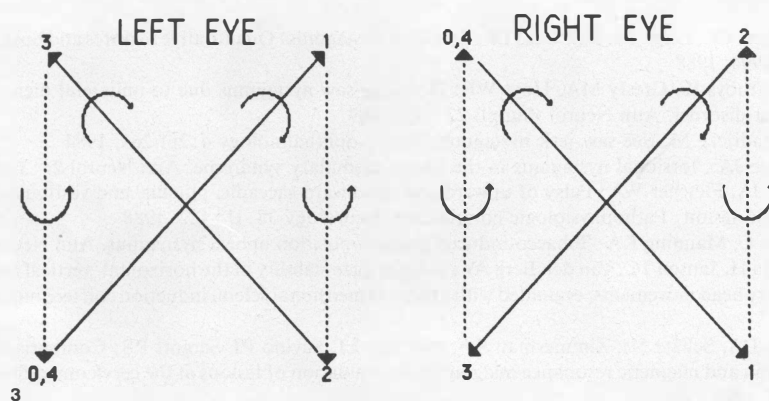


Fig. 3. An illustration of the patient's torsional, see-saw bow-tie nystagmus consisting of conjugate, clockwise, jerk nystagmus superimposed on an upbeat, bow-tie nystagmus in the left eye (LE) and a downbeat, bow-tie nystagmus in the right eye (RE). Fast phases are shown as solid lines and slow phases as dashed lines. The clockwise and counterclockwise (from the point of view of the patient) components are also shown. Corresponding points in the cycles of each eye are numbered.

DISCUSSION

Our patient's nystagmus showed three distinct characteristics, each of which has been linked to separate disease states.

Clinically, only the torsional component of his nystagmus was evident – a clockwise, jerk nystagmus. Nystagmus with a purely torsional vector is usually indicative of disease of the brain stem or cerebellum¹. It has also been reported clinically in patients with syringomyelia⁸.

Although not evident clinically, our patient's nystagmus also showed a hemi-see-saw component, with disjunctive vertical slow phases. Such nystagmus has been associated with disturbance of central otolithic connections²⁻⁵.

A third component consisted of conjoined horizontal saccades to give oblique quick phases. Since the slow phases did not have a horizontal component and the oblique quick phases alternated to the right and left, the trajectory described a 'bow-tie'. The latter has been report-

ed with upbeat nystagmus due to tobacco inhalation⁶ or cerebellar disease⁹. Our patient's left eye was similar to upbeat, bow-tie nystagmus (with a clockwise, torsional component) but the right eye had a downbeat, bow-tie waveform (also with clockwise, torsional quick phases).

The coexistence of these three components in our patient's nystagmus suggests a common pathogenesis due to disruption of central vestibular connections. Our case also illustrates the need for MR scanning in patients with torsional nystagmus and points out that complicated waveforms may be present in nystagmus which cannot be detected by clinical examination.

ACKNOWLEDGEMENTS

We are grateful to Holly A. Stevens for editorial assistance and to Richard Leigh, Jr. for help with illustrations. Supported by NIH grant EY06717 (to Dr. Leigh), the Department of Veterans Affairs, and the Evenor Armington Fund.

REFERENCES

1. Noseworthy JH, Ebers GC, Leigh RJ, Dell'Osso LF: Torsional nystagmus: Quantitative features and possible pathogenesis. *Neurology* 38:992-994, 1988
2. Halmagyi GM, Curthoys IS, Gresty MA, Hoyt WF: Hemi-see-saw nystagmus due to unilateral diencephalic lesion: A novel eye movement disorder. *Ann Neurol (Suppl)* 22:147, 1987
3. Dehaene I, Van Zandijcke M: See-saw jerk nystagmus. *Neuro-ophthalmology* 4:261-263, 1984
4. Morrow MJ, Sharpe JA: Torsional nystagmus in the lateral medullary syndrome. *Ann Neurol* 24:390-398, 1988
5. Ranalli PJ, Sharpe JA, Fletcher WA: Palsy of upward and downward saccadic, pursuit, and vestibular movements with a unilateral midbrain lesion: Pathophysiologic correlations. *Neurology* 38:114-122, 1988
6. Sibony PA, Evinger C, Manning KA: Tobacco-induced primary-position upbeat nystagmus. *Ann Neurol* 21:53-58, 1987
7. Ferman L, Collewijn H, Jansen TC, Van den Berg AV: Human gaze stability in the horizontal, vertical and torsional direction during voluntary head movements, evaluated with a three-dimensional scleral induction coil technique. *Vis Res* 27:811-828, 1987
8. Bosley TM, Cohen DA, Schatz NJ, Zimmerman RA, Bilaniuk LT, Savino PJ, Sergott RS: Comparison of metrizamide computed tomograph and magnetic resonance imaging in the evaluation of lesions at the cervicomedullary junction. *Neurology* 35:485-492, 1985
9. Leigh RJ, Zee DS: *The Neurology of Eye Movements*, 2nd edn, p 388. Philadelphia: FA Davis 1991