

Downbeat nystagmus in an infant [◇][§]

Spontaneous resolution during infancy

B. M. WEISSMAN^{1, 3}, L. F. DELL'OSSO^{1, 2*} and A. DISCENNA²

Ocular Motor Neurophysiology Laboratory¹, Veterans Administration Medical Center; and the Departments of Neurology² and Pediatrics³, Case Western Reserve University and University Hospitals of Cleveland; Cleveland, OH, USA

ABSTRACT. Downbeat nystagmus (DBN) has been associated with pathologic as well as idiopathic conditions. DBN may occur during infancy or childhood or may be congenital. In all reported cases, the DBN persisted. The authors report an infant with DBN that resolved within the first year of life.

The patient's DBN was observed by six weeks of age. The patient preferred to keep her head in a chin-down position. Her physical and neurologic examination was otherwise normal. Family history contained no nystagmus. The DBN was documented by both vertical DC electro-oculography and infrared oculography. The DBN slow phases were predominantly of constant velocity. Subsequent magnetic resonance imaging studies and metabolic investigations were negative. The DBN was clinically undetectable at nine months of age. A repeat oculographic study at one year of age confirmed the resolution of DBN.

It is suggested that, in this case, DBN was caused by an immaturity of central connections associated with the vertical canal pathways and its resolution paralleled their later maturation.

Key words: downbeat nystagmus; infant; spontaneous resolution

INTRODUCTION

Downbeat nystagmus (DBN) is an ocular motor disorder commonly associated with cerebellar dysfunction. DBN has been infrequently report-

ed in children. Of the nonpathologic causes of DBN, one report described congenital hereditary DBN in an eight-year old boy¹. According to the report, it had been present from birth. We have studied one neurologically normal infant who had electro-oculographically (EOG) confirmed DBN from six weeks of age. This infant's DBN clinically resolved by age nine months. This case is the first report of an infant with transient DBN.

CASE REPORT

C.K. is a Caucasian infant who was first examined by us at three months of age. She was born at term

* *Reprint requests and correspondence to:* L. F. Dell'Osso, Ph.D., Ocular Motor Neurophysiology Laboratory, Veterans Administration Medical Center (127A), 10701 East Boulevard, Cleveland, OH 44106 USA, Telephone (216) 421-3224.

◇ This work was supported in part by the Veterans Administration (Dr. Dell'Osso) and a Rainbow New Investigator Research Grant (Dr. Weissman).

§ Presented at the INOS Neuro-Ophthalmology Congress, 6-12 May, 1988, Vancouver, Canada.

gestation to a 27-year-old primagravida mother. Pregnancy, labor and delivery were all uncomplicated. Birth weight was 3800 g. At six weeks of age, her parents noticed that her eyes were 'jumpy' when she was placed in a supine position. When she was in a vertical position, she preferred to maintain her head in a chin-down position. There were no family members with ocular motor or cerebellar disorders. Ophthalmologic examination revealed a full range of eye movements and no evidence of funduscopy abnormality. Her neurologic examination confirmed a normal head circumference of 40 cm. She had DBN which increased in amplitude on down-gaze and was prominent when she was supine. The infant had no other cranial nerve abnormalities. There were no signs of cerebellar dysfunction. The remainder of her neurologic examination was appropriate for her age. A magnetic resonance image of the head showed a normal appearing brain parenchyma and a normal size and position of the brainstem and posterior fossa. Laboratory studies, which included a metabolic screen and lysosomal enzymes, were normal.

At three months of age, occasional beats of DBN were present when the infant was in a sitting position. When she was placed in a supine position, nonfatiguing DBN was provoked. With return to a vertical position, the DBN decreased in amplitude and frequency. Her vertical and horizontal vestibulo-ocular reflexes (VOR) were qualitatively normal (in the light). At five months of age, she failed to show spontaneous DBN when in a vertical position. When she was supine, DBN was elicited but lasted less than ten seconds. A clinical evaluation of the infant at nine months of age suggested resolution of DBN. This clinical observation was confirmed by EOG three months later.

METHODS

After the parents gave informed consent, vertical eye movements were recorded using both DC EOG and infrared oculography (bandwidth 0-100 Hz). Calibration was qualitatively obtained by rotating the infant's head for the range of eye movements. The recording included an examination of spontaneous eye movements and position-

al changes in the vertical (sitting) and supine positions.

RESULTS

Results of the electro-oculographic (EOG) recordings are shown in Figs 1A and B. Fig. 1A is a vertical DC EOG recording of the right eye. The nystagmus was conjugate. The infant was three months old when the record was obtained. Nonfatiguing DBN was elicited when the infant was placed in a supine position. With a change in position to vertical (sitting, as indicated by the arrow in Fig. 1A), the frequency and amplitude of the nystagmus decreased. Fig. 1B shows the infant's DBN two months later. The nystagmus was not observed with the infant held in the upright position. In the supine position, DBN was elicited but diminished in frequency and amplitude as well as duration. When compared to the previous study, nystagmus fatigued within ten seconds. A third oculographic study obtained when the infant was 12 months old did not show DBN in the supine or vertical positions.

DISCUSSION

Reports of DBN in children are infrequent. The youngest case reported in an extensive review by Halmagyi and colleagues² was ten years of age. Bixenman¹ reported the youngest case of DBN (hereditary congenital DBN) which was reportedly present from birth. Thus, DBN in infants is a rare event. Reports relating vertical nystagmus in infants have described upbeat and see-saw³ and a pendular⁴ type of nystagmus. In most of these cases, vertical nystagmus was associated with an ocular abnormality. Hereditary congenital DBN has been reported as an autosomal dominant condition; thus, other affected individuals are often available for examination. The present case

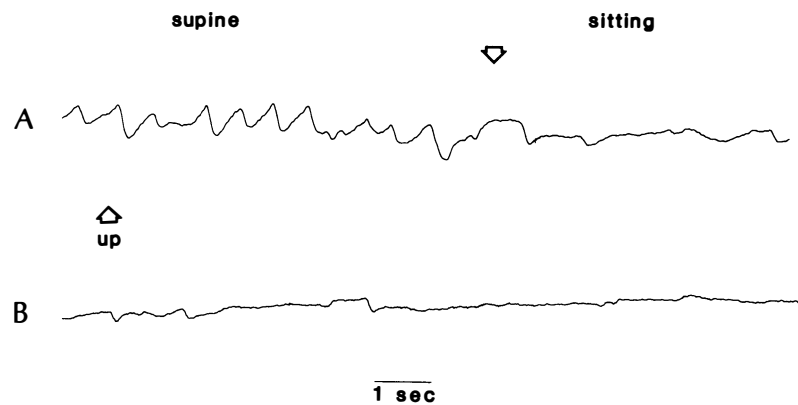


Fig. 1. A. Vertical DC electro-oculographic record obtained from the infant at three months of age. Only the right eye is shown; the nystagmus was conjugate. When the infant was placed in the supine position, nonfatiguing downbeat nystagmus was elicited. With a change in position to vertical (sitting, at the arrow), the frequency and amplitude of the nystagmus decreased. B. At five months of age, the infant's nystagmus has diminished with the infant in the supine position. There was no downbeat nystagmus in the sitting position.

had neither an ocular abnormality nor a family history of nystagmus.

DBN has been more commonly associated with a cerebellar disorder. The site of the lesion is thought to be the vestibulocerebellum. Studies by Zee and colleagues⁵ and pathologic correlations in the human² support this localization. More recently, Gresty and colleagues⁶ evaluated the influence of vertical canal and otolith factors in a patient with tilt-sensitive DBN. Unlike the present case, their patient's DBN was maximal in the upright position and abolished in the supine position. They concluded that the patient's DBN

was the result of asymmetric vertical canal reflexes which were modulated by otolithic input. They compared this case to another patient with tilt-insensitive DBN who had hyperactivity of the upward VOR. Thus, in cases of DBN abnormal canal dysfunction should be considered. However, in the present case, DBN resolved spontaneously and the infant was neurologically normal.

We hypothesize that the appearance of DBN in this infant was due to an immaturity of central connections associated with vertical canal inputs and that its subsequent resolution was the result of the maturation of these inputs.

REFERENCES

1. Bixenman WW: Congenital hereditary downbeat nystagmus. *Can J Ophthalmol* 18:344-348, 1983
2. Halmagyi GM, Rudge P, Gresty MA, Sanders MD: Downbeating nystagmus. A review of 62 cases. *Arch Neurol* 40:777-784, 1983
3. Hoyt CS, Gelbart SS: Vertical nystagmus in infants with congenital ocular abnormalities. *Ophthalm Paediat Genet (Amsterdam)* 4:155-162, 1984
4. Johnsen SD, Deering WM: Intermittent vertical ocular oscillations in infancy. *J Pediat* 90:85-87, 1972
5. Zee DS, Yamzaki A, Butler PH, Gücer G: Effects of ablation of flocculus and paraflocculus on eye movements in primate. *J Neurophysiol* 46:878-899, 1981
6. Gresty MA, Barratt H, Rudge P, Page N: Analysis of downbeat nystagmus. *Arch Neurol* 43:52-55, 1986