

Symposium: Strabismus

‘ ‘ ‘

**THE EFFECTS OF CONGENITAL
NYSTAGMUS SURGERY**

JOHN T. FLYNN, MD

and

LOUIS F. DELL'OSSE, PhD
BY INVITATION
MIAMI, FLORIDA

Reprinted from Ophthalmology
American Academy of Ophthalmology
August 1979

Symposium: Strabismus

THE EFFECTS OF CONGENITAL
NYSTAGMUS SURGERY

JOHN T. FLYNN, MD

and

LOUIS F. DELL'OSSO, PhD

BY INVITATION

MIAMI, FLORIDA

Anderson-Kestenbaum operations for congenital nystagmus with severe head turn have been employed for the past 25 years. They have been documented as being effective in correcting head turns associated with congenital nystagmus. We have studied a group of patients with congenital nystagmus and head turn, both preoperatively and postoperatively, by means of recordings of eye movements. We have documented the effect of surgery in shifting the null position, in broadening the null position, and in lowering the nystagmus intensity. In some cases, an improvement of the visual acuity has also occurred.

ANDERSON¹ and Kestenbaum² independently and almost simultaneously first advocated surgical treatment of congenital nystagmus (CN) with a head turn. Although their surgical approaches differed, the results of both of their operations achieved the same ends, namely, displacing the eyes away from the

zone of least nystagmus. Since their initial reports, others have confirmed their observations and added a number of other important ones. Goto³, on the basis of his electro-oculogram (EOG) recordings, advocated resection and advancement of the muscles responsible for the quick phase of the nystagmus and also noted an improvement in the visual acuity of three of his four patients so treated. Pierce⁴ extended the principles advocated by Anderson and Kestenbaum to vertical head tilts accompanying CN. He also noted improved visual acuity in one of his two patients following such surgery. Sternberg-Raab⁵ reported the results of surgery in ten cases. Two of the ten had improvement in visual acuity following the surgery. In three of the ten, however, the head turn recurred on prolonged follow-up. Cooper and Sandall⁶ initially reported seven patients whom they treated surgically. They described a method of quantitative evaluation of the degree necessary to turn the eyes using the arc perimeter and advocated conservatism in the surgical approach. Two of their patients had improvement in their visual acuity following surgery. In a later report,⁷ they extended their observations to 18 patients with stra-

Submitted for publication Jan 2, 1979.

From the Bascom Palmer Eye Institute, Department of Ophthalmology, University of Miami School of Medicine and The Ocular Motor Neurophysiology Laboratory, Miami Veterans Administration Hospital, Department of Neurology, University of Miami School of Medicine.

Presented in combination with the American Association for Pediatric Ophthalmology and Strabismus at the 1978 annual meeting of the American Academy of Ophthalmology, Kansas City, MO, Oct 22-26.

Reprint requests to Bascom Palmer Eye Institute, PO Box 016880, Miami FL 33101 (Dr Flynn).

bismus as well as CN. Schlossman^{8,9} described his treatment of CN accompanied by strabismus and built his surgical approach around a maximum 5-mm weakening procedure on the medial rectus and no more than 1 mm more recession or resection on the lateral rectus. He noted improvement in visual acuity in the primary position in at least one of the six patients he presented. On the other hand, Taylor¹⁰ recommended large lateral rectus recessions (8-9 mm) and medial rectus recessions (6 mm) combined with 6-mm resections of their antagonists to effectively prevent the recurrence of the head turn. He described the synoptophore as an instrument adequate to measure the amount of eye deviation the surgeon had to correct to shift the quiet zone of the nystagmus to the primary position. Both of the cases he reported had significant improvement in their visual acuity following surgery.

Crone¹¹ described two types of operations for congenital nystagmus. A "relocating" operation, which is the classical Anderson-Kestenbaum operation, and an "immobilizing" operation, first described by Friede¹² in 1956, that consists of retroequatorial displacement of the agonist muscle(s) producing the slow phase of the nystagmus. Kommerell¹³ presented a series of 28 patients operated on by the Anderson-Kestenbaum operation. Twelve of his patients had full binocular vision; 16 had strabismus and amblyopia or microphthalmos of one eye. Considerable improvement in the head turn was obtained in 18, slight improvement in 4, and no improvement in 6. Significantly, he obtained no improvement in the visual acuity in any of his patients. Parks¹⁴ described quantitatively his approach

to the surgery of CN with a head turn consisting of a 7-mm recession of the lateral rectus and a 5-mm recession of the medial rectus muscles turning the eye into the position of least nystagmus, and a 6-mm resection of the medial rectus and an 8-mm resection of the lateral rectus turning the eyes in the opposite direction, the so-called "5-6-7-8" operation. However, Calhoun¹⁵ found, in a series of 19 patients operated on for CN with a head turn, that these indications were inadequate. He recommended doing 40% more on each of the muscles operated on to prevent recurrence of the head turn. Hugonnier¹⁶ presented his experience with 79 cases of surgically treated CN. Twenty-three had pure CN and 56 were associated with strabismus: 20 of the 23 with pure CN had a "good" result from surgery, defined by the author as improvement in the head turn and acuity in the primary position. Of the cases associated with strabismus, in only 15 was the nystagmus considered the primary indication for surgery. Thirteen benefited from the author's nonspecific criteria. Fells and Dulley¹⁷ reported improved visual acuity in eight of nine patients after surgical correction of the compensatory head posture.

In summary, there now exists a substantial body of knowledge on the operative indications, clinical methods of measurement of head turn, amount of surgery, and modification of the treatment to encompass strabismus and amblyopia, conditions often associated with CN. In a recent publication,¹⁸ we described in detail our methods of quantitatively studying preoperatively and postoperatively the precise location of the "null zone," (the amplitude and frequency is minimal), the "nystagmus intensity"

(the product of the nystagmus frequency in cycles per second \times amplitude in degrees), and other parameters relevant to the evaluation of the nystagmus. Employing these techniques preoperatively and postoperatively, there emerged from this analysis a clear-cut picture of the effects of surgery on congenital nystagmus. In this study, we would like to emphasize clinical aspects in the care of the patients with congenital nystagmus who are being evaluated for surgery and to emphasize, in particular, problems that may arise in the course of their therapy.

MATERIALS AND METHODS

All patients had, in addition to complete ophthalmologic examination, detailed examination of their eye movements by infrared recordings and graphic analysis of the profiles of the intensity of their nystagmus at various gaze angles. Details of these techniques are given in the previous reference.¹⁸

CASE REPORTS

CASE 1.—A 15-year-old white girl was first noted to have poor visual acuity soon after birth. Bilateral massive retinal hemorrhages were noted at ten weeks of age. These cleared completely by three months of age. At eight weeks of age, CN and a variable esotropia were noted. This later became a full-time left esotropia with amblyopia. Repeated attempts to patch the right eye during childhood failed to improve the vision in the left eye.

On examination, a head turn to the right was present and the patient's binocular visual acuity for distance was 20/70 in straight ahead gaze and 20/60 in left gaze. Monocularly, it was 20/70 in the right eye. In her left eye, she was 20/200 unimprovable. Twenty-five prism diopters of left esotropia by corneal light reflex was present at both distance and near. Her retinoscopy was OD +1.00 +0.75 \times 95 and OS +3.00 +1.00 \times 85. This did not significantly improve her visual acuity or head turn.

On quantitative nystagmus recordings preoperatively, there was a sharp null at 20° to the left (Fig 1).

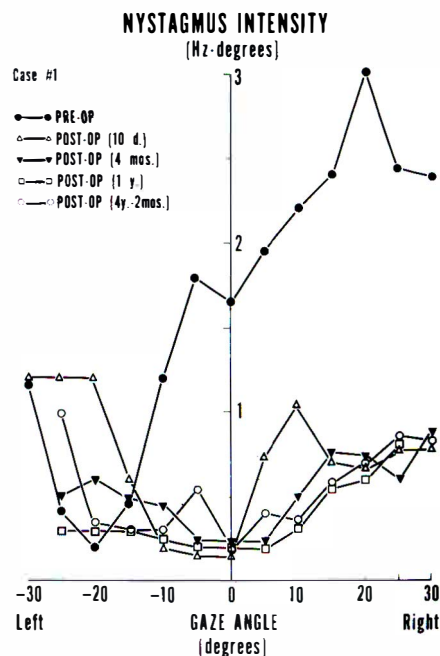


Fig 1.—Preoperative and postoperative plots of the intensity vs. gaze angle for Case 1, indicating the time course of improvement.

The management problems that this patient presented were as follows. First of all, she had strabismus with amblyopia in addition to her CN. To be effective, surgery had to be confined to the fixing right eye. The task was to move the eye 20° to the right. To accomplish this, any surgery done would have to overcorrect her 25Δ esotropia. After explaining these considerations to the patient and her parents, they elected to go ahead with the surgery and on May 6, 1974, a right medial rectus recession of 5 mm combined with a right lateral rectus resection of 6 mm was performed.

Postoperatively, the patient was 15Δ exotropic and has remained so to the present time. In the immediate postoperative period, the binocular visual acuity was 20/70+1 in the primary position. On the 11th postoperative day, her visual acuity binocularly had improved to 20/40-2 in the primary position. The patient adopted a

gaze position 5° to the left of the primary position. For this she was given a prism of 9Δ base-out over the right eye to enable her to use this position without a significant head turn. In this way, prisms were used to "fine tune" the surgical result.¹⁹ On last follow-up July 11, 1978, the patient's binocular visual acuity remains 20/40-2 in the primary position at distance and 20/50- at near. Her postoperative recordings (Fig 1) performed ten days, four months, one year, and more than three years following surgery show reduction of the nystagmus intensity overall, a shift in the null zone toward the primary position, and a broadening of the null zone. In addition to this, the patient seems to have achieved a stable increase in her visual acuity.

To the clinician, this patient presented the problem of performing muscle surgery on the seeing eye for relief of the head turn. The second problem was the obvious necessity of performing surgery adequate to shift this fixing eye 20° to the right, which would necessarily overcorrect the left esotropia. The risks attendant on the performance of this surgery were acceptable to the patient and her parents. Postoperatively, we failed to achieve complete correction of the head position, but the patient has done very well since surgery with the use of a small

prism before her fixing eye. She is now pursuing her career as a college student.

CASE 2.—A 6-year-old white boy had congenital nystagmus with a right head turn, first noted at 2-3 months of age. Detailed ophthalmologic examination was normal. When first seen by us in November 1973, the patient's binocular visual acuity in his head turn position was 20/40 and his monocular acuity was 20/50 in the right eye and 20/40 in the left eye. Out of his head turn position, it was 20/200-. His near visual acuity was 20/30 binocularly at 8 inches. The patient had fusion, normal fusional amplitudes, and normal correspondence on the synoptophore.

On quantitative recordings of his nystagmus, it proved to be jerk right except in far left gaze in which it was jerk left. There was a null between 20° and 25° left gaze preoperatively (Fig 2). Attempted convergence increased his nystagmus.

In contrast to the previous patient, this patient presented the classic indication for the Anderson-Kestenbaum relocating operation. The task was to move both eyes 20° to the right. On June 17, 1974, the left lateral rectus muscle was recessed 7 mm, the left medial rectus muscle was resected 6 mm, the right medial rectus muscle was recessed 5 mm, and the right lateral rectus muscle was resected 9 mm.

Postoperatively, the patient complained immediately of diplopia. He was found to have an esotropia of 12-15Δ. He fused with a prism of 12D base-out before his right eye. The head turn partially recurred soon after the surgery in the amount of 10° to the right. The nystagmus characteristics, measured postoperatively (Fig 2), showed a null shift toward the primary position, a broadening of the null region, and a lower nystagmus intensity over the range of gaze angles tested. These effects persisted through recordings up to fourteen months postoperatively.

The problems presented by this boy postoperatively were twofold. First, he had a persistent, surgically-created esotropia of 15Δ and required prisms to fuse. Second, his head turn was not fully abolished. It was therefore decided to selectively weaken his left turners, that is, his right medial rectus muscle and his left lateral rectus muscle, doing proportionately more on the right medial rectus than on the left lateral rectus to overcome the esotropia and to shift his broadened null zone closer to the primary position.

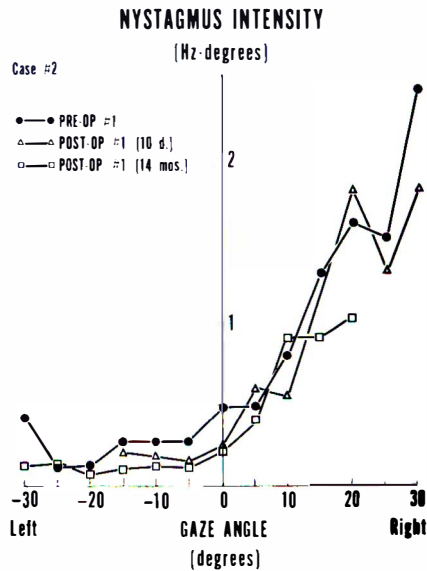


Fig 2.—Preoperative and postoperative (procedure No. 1) plots of the nystagmus intensity vs. the gaze angle for Case 2.

On December 1, 1975, the right medial rectus muscle was further recessed a 2 mm (a total recession of 7 mm) and the left lateral rectus muscle was recessed 3 mm (a total recession of 10 mm).

Postoperatively, the esotropia was eliminated as a result of the second operation and the effect on the nystagmus intensity (Fig 3) was to shift his null to the primary position.

On the last follow-up visit in July 1978, the patient's binocular visual acuity in the primary position was 20/20 and his monocular visual acuity was 20/25 in the right eye and 20/30 in the left eye. He had a slight (less than 5°) head turn to the right. His near binocular visual acuity was 20/20. On motility examination, the patient had, on cover test, an intermittent esotropia of 8Δ at distance and 12Δ at near. His near point of convergence was remote, the right eye deviating. He had a large-amplitude, right-beating nystagmus on gaze to the right; on left gaze, he had limited ability to turn either eye to the left beyond 20° to 25°. Postoperative recordings continued to show a broad null zone centered on the primary position and diminished nystagmus intensity (Fig 3).

This patient emphasized several management problems. The first of these was the creation of a tropia in a patient who was previously fusing. Although not emphasized in the literature on the surgery of congenital nystagmus, this occurs apparently about 20% of the time.²¹ In this patient, it was accompanied by rapid partial recurrence of his head turn due to inadequacy of the surgery. Because of certain family problems, repeat surgery was postponed until some 18 months after the first surgery. During the interim, the patient did reasonably well with a base-out prism over his right eye, which simultaneously helped him fuse and diminished his head turn to the right. The second surgical procedure has left him with an intermittent esotropia on cover test (the patient never experiences diplopia at the present time, however) and also has weakened his

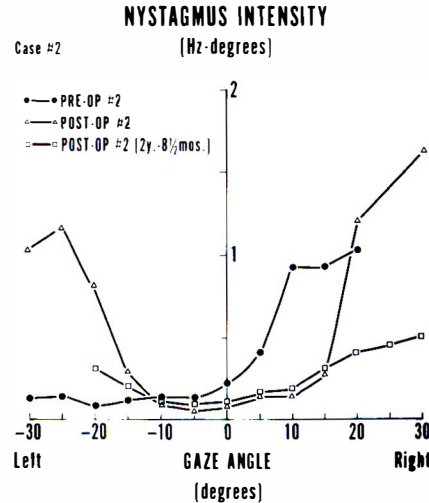


Fig 3.—Preoperative and postoperative (procedure No. 2) plots of the nystagmus intensity vs. the gaze angle for Case 2.

near point of convergence and constricted his gaze to the left. These are the trade-offs which one must make for effective surgery in congenital nystagmus. At the present time, we would avoid the so-called 5-6-7-8 operation,²² as we think that it does not achieve the end of adequately shifting the null zone to the primary position.

CASE 3.—A 22-year-old white male born prematurely developed severe cicatricial retrolental fibroplasia which left him with essentially light perception on his right eye and reduced vision in his left eye. Nystagmus and a right esotropia appeared early in infancy. He had surgery on the right eye for the esotropia at age 8. The patient was aware that he had to turn his head to the left to see clearly with his left seeing eye.

Examination revealed a vision of light perception with projection in the right eye. In the left eye, the vision was 20/100 in the primary position and 20/60 in right gaze and less than 20/100 in gaze to the left. At near, his vision was 20/30 in the left eye in gaze to the right. Twenty prism diopters of right esotropia was present by prism corneal light reflex measurement. A poor direct

light reflex and an afferent pupillary defect were present on the right and a retrolental membrane with a peripheral traction detachment in the right eye. In the left eye, the anterior segment was normal and there was marked straightening of the retinal vessels, ectopia of the macula temporally, and pigment changes and traction in the periphery consistent with a diagnosis of cicatricial retrolental fibroplasia.

Nystagmus recordings (Fig 4) demonstrated jerk left nystagmus which decreased in intensity toward a null which was beyond 30° to the right.

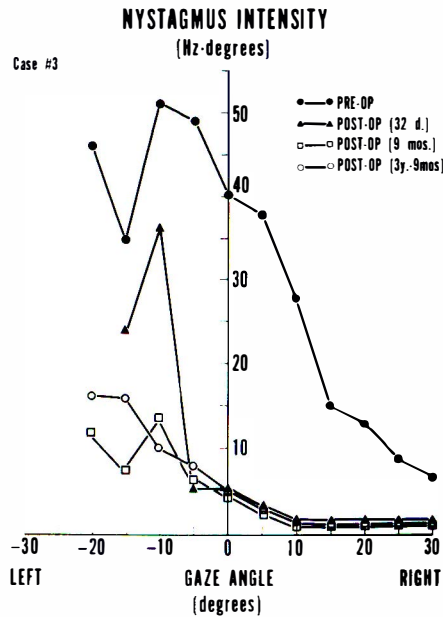


Fig 4.—Preoperative and postoperative plots of the nystagmus intensity vs. gaze angle for Case 3, indicating the time course of improvement.

The patient presented surgical indications similar to patient 1, but he differed in that the null position was extremely displaced (beyond 30° to the right). This type of patient is a candidate for an immobilizing type of operation as described by Crone,¹¹ ie, a monocular patient with a null position in far eccentric gaze, the operation would of necessity overcorrect his esotropia. In addition, one could anticipate that the heterotopia of the macula would add to the real divergence that might occur postoperatively, a pseudodivergence due to his large positive angle

kappa in the left eye. These problems were presented to the patient and because of the severity of the cosmetic defect and his real desire for improvement of this, he decided to go ahead with the surgery. An 8-mm recession of the left medial rectus combined with a recession of the conjunctival sac and a 7-mm resection of the left lateral rectus muscle was performed on December 9, 1974.

Postoperatively, much to our surprise, only a pseudodivergence due to the heterotopia of the macula occurred. The nystagmus intensity was markedly decreased (Fig 4) and the null zone shifted to the left, where it occupied a region between 10° and 30° to the right of the primary position. On last examination, the patient's nystagmus intensity and null zone have remained the same three years and nine months following surgery. The patient employs a head turn 12° to the left to see clearly. For him, this was enough cosmetic improvement and he does not wish to wear the required 20-25D to compensate for it or undergo further surgery.

From the standpoint of the clinician, the problem presented by this patient was the enormous surgical requirement necessary to shift the left eye 30° or more to the left. In fact, inadequate surgery was performed and the patient was left with a 12° to 15° head turn. At the present time, our management of such a patient would be to do an adjustable medical rectus recession of 15 mm or more combined with a resection. There is no question in our minds that such surgery is required in circumstances where the null zone is displaced more than 30° to the right or left of the primary position.

CASE 4.—A 28-year-old woman had congenital nystagmus and a right esotropia, poor vision in the right eye, and a cosmetically disfiguring head turn to the left to obtain her best vision. The patient had lost several jobs because of the appearance of her head turn and desired cosmetic correction of this.

On examination, the visual acuity in her right eye was 20/100 at distance and near. In her left eye, the visual acuity with a head turn 35° to the left was 20/50. In the pri-

mary position, the patient's vision was 20/100-. On clinical examination of her nystagmus, it seemed that her quiet phase in the left eye was about 15° to the right of the midline. In this position it appeared that to further dampen her nystagmus the patient would spontaneously develop an adduction movement of the right amblyopic eye of 15° to 20°.

On quantitative recordings (Fig 5), she was noted to have a null zone in her left eye at about 10° to 15° of right gaze. Convergence of the right eye was also noted to dampen her nystagmus.

On March 10, 1975, the patient had a left medial rectus recession of 5 mm, a left lateral rectus resection of 5 mm, and a right medial rectus recession of 6 mm. In the immediate postoperative period, although her head turn to the left was diminished, it recurred, as did the tendency for her right eye to go esotropic when the left eye assumed a position of about 15° to the right of the primary position. When last seen on August 10, 1978, the patients' visual acuity in her right eye was 20/100- and her left eye 20/20!. She had a head turn of 15° to the left, best seen on determining

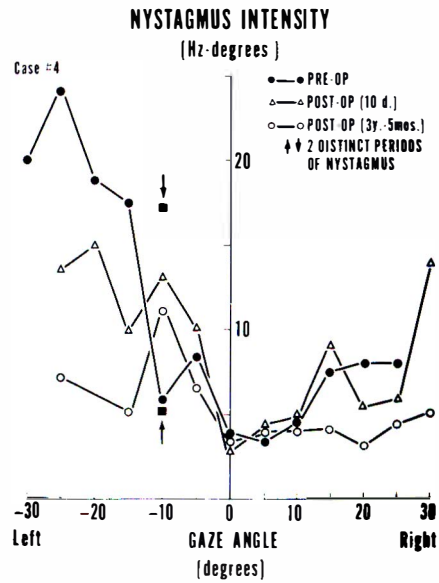


Fig 5.—Preoperative and postoperative plots of the nystagmus intensity vs. the gaze angle for Case 4.

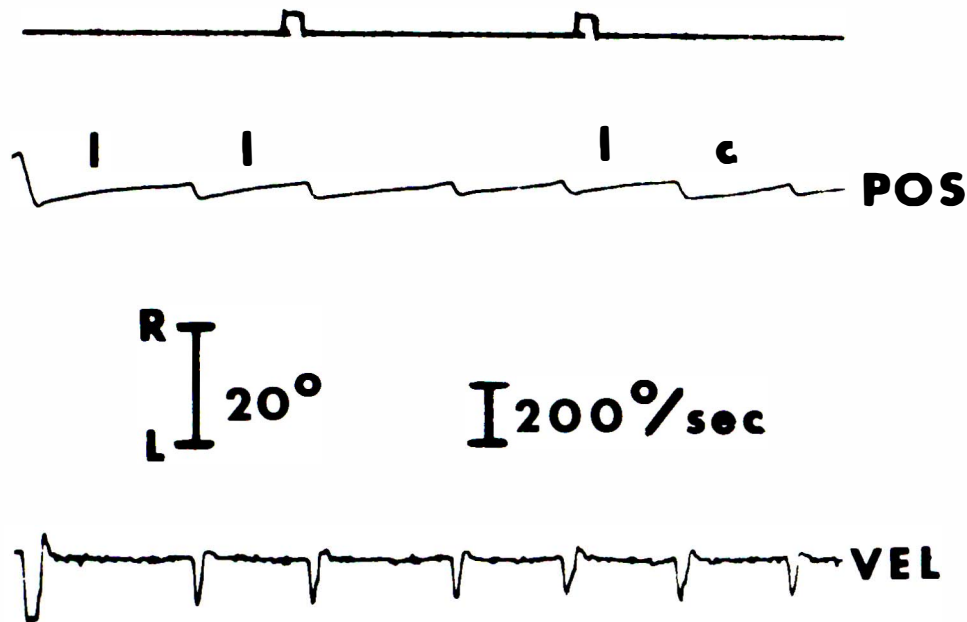


Fig 6.—A sample of the waveforms of Case 4 indicating the decreasing velocity slow phases diagnostic of latent nystagmus.

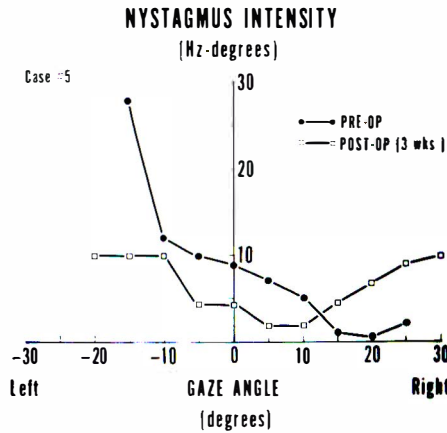


Fig 7.—Preoperative and postoperative plots of the nystagmus intensity vs. the gaze angle for Case 5. The postoperative curve is based on limited data as explained in the text.

her visual acuity at both distance and near. The amblyopic right eye continued to go esotropic in varying amounts depending on the effort the patient was making to obtain the best visual acuity from her left eye.

In reevaluating this patient's eye movement recordings, it was obvious that she was not a simple, straightforward case of congenital nystagmus on the basis of her waveforms (Fig 6). She actually was a case of combined congenital and latent nystagmus. These patients, in addition to their CN waveform, have a completely different waveform diagnostic of latent nystagmus.²³ They represent an entirely separate entity in terms of treatment and are not amenable to the standard Anderson-Kestenbaum operation or its modifications. During the early years of our experience with quantitative recordings, we were unaware of this difference and did an operation which was of doubtful benefit to the patient.

CASE 5.—A 24-year-old black man was first seen in the Eye Clinic on February 16, 1976 for complaints of headache and wiggling eyes. The patient's history of nystagmus goes back to early infancy and he claim-

ed he never had good vision in either eye. Neurologic and medical evaluation revealed only mild diastolic hypertension.

On examination, the patient's visual acuity binocularly was 20/20; monocularly, it was 20/50-2 in the right eye and 20/25-1 in the left eye. His near visual acuity was 20/25. He had a marked head turn to the left of 25° to 30°. His nystagmus was jerk left in all fields of gaze including far to the right. His nystagmus dampened on convergence. The visual fields and fundus examination were normal.

On quantitative nystagmus recordings (Fig 7), the patient had a null between 15° and 20° of right gaze.

On February 21, 1977, the patient had an Anderson-Kestenbaum operation performed, recessing his right lateral rectus muscle 11 mm and his left medial rectus muscle 6 mm and resecting his right medial rectus muscle 6 mm and his right lateral rectus muscle 11 mm.

Postoperatively, his visual acuity was 20/20 monocularly and binocularly in the primary position at distance and near. He was orthophoric and has fusion for the Bagolini lenses at both distance and near. The patient was noted, however, to have large saccadic eye movements, horizontal in direction, random in occurrence, and present primarily when he was being observed. These subsided spontaneously when the patient believed he was not being observed and when he put on dark sunglasses in order to read the visual acuity chart. The presence of these large saccades postoperatively (Fig 8) prevented accurate quantitative reevaluation of his nystagmus and the effect of the surgery on it. The curve shown in Figure 7 is our best estimate based on the available data.

The patient's behavior postoperatively took us by surprise. However, review of his Jackson Memorial Hospital chart revealed numerous visits to the Emergency Room for trivial complaints. A diagnosis of hysteria and/or hypochondriasis was made on a number of occasions. Clearly, this patient physiologically benefitted from his Kestenbaum operation in the sense that he could now read the visual acuity chart with his head straight. This, however, for psychological reasons became intolerable for him. He substituted for his congenital nystagmus, large-amplitude, irregular saccades. These corresponded to no known pathologic disorder of ocular motility. The problem presented by this patient in management was

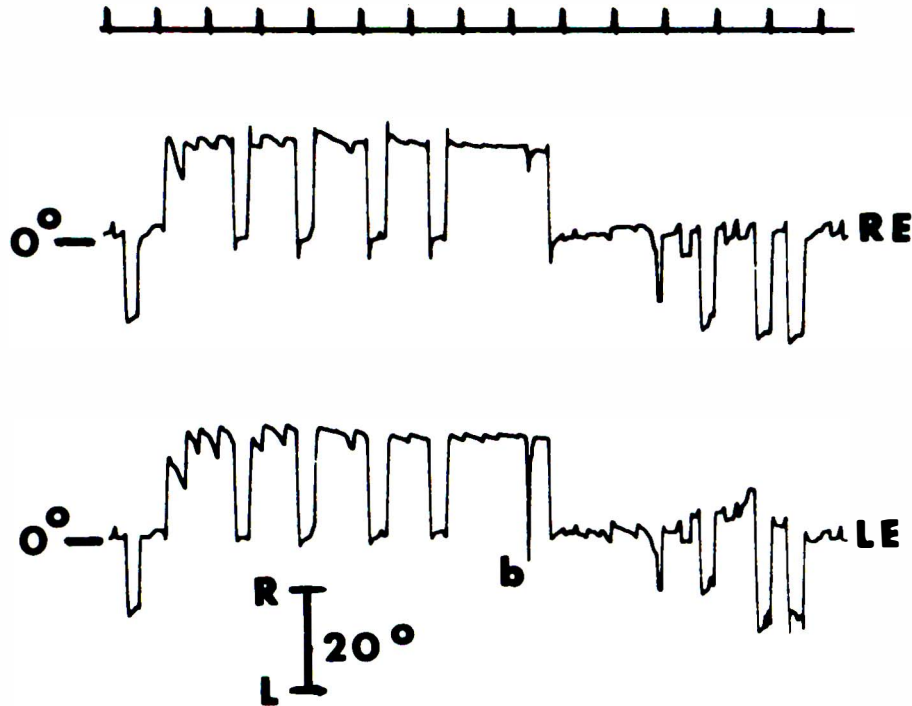


Fig 8.—Large saccades present postoperatively when the patient thought he was being observed.

our failure to anticipate the effect of the surgery and the change that it wrought on the patient's psyche.

Postoperatively, the patient complained bitterly of inability to control his eyes and had absolutely no insight into the fact that he was causing the very eye movements he could not control. Though contacted a number of times to return for follow-up evaluations and visits, the patient has steadfastly refused to keep these appointments.

CASE 6.—A 13-year-old white boy was noted shortly after birth to have a tendency to turn his head to the left. Nystagmus was noted shortly after that. There was no family history of serious eye problems.

On examination, his visual acuity binocularly was 20/40 with his head turned 20° to the left. His monocular visual acuity was 20/50+ in the right eye and 20/200 in the left eye. At near, his visual acuity was 20/40- binocularly; monocularly, he was 20/50 in the left eye and 20/50- in the right eye. His nystagmus showed a large null zone from close to the primary position to

20° to 30° to the right of the primary position. His nystagmus elsewhere was jerk right in gaze to the right and jerk left in gaze to the left. It was left-beating in upgaze and downgaze. His nystagmus was dampened on convergence. He was orthophoric. The remainder of his ocular examination was normal.

On quantitative recordings (Fig 9), the patient had a null zone of 20° to 25° to the right of the primary position. He also dampened his nystagmus significantly with convergence. On December 19, 1977, a 10-mm recession of the right lateral rectus muscle, a 6-mm resection of the right medial rectus muscle, a 6 mm recession of the left medial rectus muscle, and a 10 mm resection of the left lateral rectus muscle was performed.

Postoperatively March 30, 1978, his binocular visual acuity was 20/20-. His monocular visual acuity was 20/30- in the right eye and 20/20- in the left eye. His head turn appeared to be about 10° to the left. Postoperative recordings on the same day showed diminished nystagmus intensity and a broad

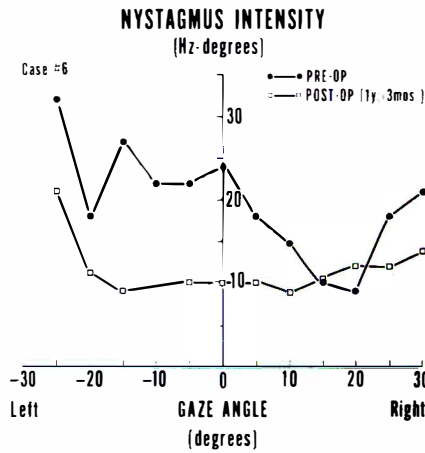


Fig 9.—Preoperative and postoperative plots of the nystagmus intensity vs. the gaze angle for Case 6.

null zone encompassing the primary position (Fig 9). The absolute null at 10° right gaze corresponded to his 10° left head turn and, more importantly, to an area in which longer periods of motionless faveation occurred per cycle and allowed extremely good vision.

This patient also presented the classic indications for the Anderson-Kestenbaum operation. This operation diminished his nystagmus intensity and broadened his null zone and shifted it to the primary position. In addition, his binocular visual acuity improved as a result of these changes in the characteristics of his nystagmus. He still has a slight head turn to the left, but, according to the patient and his family, this is much improved over what it was, and is acceptable to him and to them.

DISCUSSION

We have presented the results of our experience with six patients in whom quantitative recordings of their nystagmus could be performed both preoperatively and postoperatively. The surgical approach to congenital nystagmus produces the following changes: The nystagmus intensity is diminished over practically all gaze angles and the null zone is generally broadened and

shifted toward the primary position. A spontaneous improvement in the visual acuity may occur as a result of these changes.

Clinically, our six patients presented varying problems in management. The first patient represented the application of the Anderson-Kestenbaum technique to the monocular patient with strabismus and amblyopia. Postoperatively, her head turn recurred but was easily handled by a prescription of small prism. The second patient represents two complications of congenital nystagmus surgery, namely, the creation of a tropia where none existed before and the rapid recurrence of the head turn. Both of these proved amenable to reoperation. Our current practice is to reoperate these patients within three months if the head turn recurs or a tropia is created as a result of the surgery. The third patient presented indications similar to the first, however, the location of his null zone far in right gaze required an immobilizing operation to shift his null zone to the primary position. Inadequate surgery was performed and the head turn, although cosmetically acceptable to the patient, is still in the region of 12°. The fourth patient represents an example of latent nystagmus in conjunction with true congenital nystagmus with a head turn. This type of patient is not usually amenable to congenital nystagmus surgery. Clinically, these patients can appear very similar to ordinary congenital nystagmus patients; however, on recordings of their eye movements, they show a waveform characteristic of latent nystagmus (a decelerating exponential slow phase) (Fig 6) in addition to those of true CN. As one would expect, she did not benefit significantly from the

congenital nystagmus surgery. The fifth patient represents a clear-cut illustration of the truism that the physician is responsible in his treatment for the whole patient, not just his eyes. We clearly missed the many dependency-created psychologic problems that this patient manifested in his other medical history. Simple review of his medical record prior to the surgery would have revealed this to us. Although the nystagmus surgery itself was successful, it was quickly replaced by the patient with an even more crippling psychologically induced type of bizarre eye movement which, according to the physicians who have seen the patient, persists to this day. The sixth patient represents the happy results that can occur in congenital nystagmus surgery, both clinically and in the eye movement laboratory.

Although the field of congenital nystagmus surgery has been expanding for the past 25 years since its introduction by Anderson and Kestenbaum, there is still a great deal to be learned in applying their principles to the patient with congenital nystagmus. The use of quantitative preoperative and postoperative recordings has proved valuable in our hands in fully documenting the nature of the nystagmus, in confirming the presence of a null zone, in measuring its distance from the primary position, in planning the surgical approach, and, finally, in quantitatively evaluating the result of surgery. They have documented clearly those cases in which the surgery was slightly inadequate and resulted in an improved but not abolished head turn. The stationarity of the measured postoperative null positions should dispell the current popular notion that the head turn (ie, the off-primary position null angle)

"recurs" at some variable time post-operatively. If the surgery were insufficient, the null position will be seen at its new, less severe position immediately postoperatively and remain fixed.

ACKNOWLEDGMENTS

The authors gratefully acknowledge the assistance of Mary Jeanne Williams in the preparation of the manuscript.

REFERENCES

1. Anderson JR: Causes and treatment of congenital eccentric nystagmus. *Br J Ophthalmol* 37:267-281, 1953.
2. Kestenbaum A: Nouvelle operation de nystagmus. *Bull Soc Ophthalmol Fr* 6:599-602, 1953.
3. Goto N: A study of optic nystagmus by the electro-oculogram. *Acta Soc Ophthalmol Jpn* 58:851-865, 1954.
4. Pierce D: Operations on vertical muscles in cases of nystagmus. *Br J Ophthalmol* 43:230-233, 1959.
5. Sternberg-Raab A: Anderson-Kestenbaum operation for asymmetric gaze nystagmus. *Br J Ophthalmol* 47:339-345, 1963.
6. Cooper EL, Sandall GS: Surgical treatment of congenital nystagmus. *Arch Ophthalmol* 81:473-480, 1969.
7. Sandall GS, Cooper EL: Surgical therapy of congenital jerk-type nystagmus: Its cause and effect on heterotropia. *Doc Ophthalmol* 34:361-364, 1973.
8. Schlossman A: Nystagmus with strabismus: Surgical management. *Trans Am Acad Ophthalmol Otolaryngol* 76:OP-1479-OP-1486, 1972.
9. Schlossman A: The effect of nystagmus on comitant strabismus: Surgical implication. *Ann Inst Barraquer* 12:341-353, 1974-5.
10. Taylor JN: Surgery for horizontal nystagmus: Anderson-Kestenbaum operation. *Aust J Ophthalmol* 1:114-116, 1973.

11. Crone RA: The operative therapy of nystagmus. *Ophthalmologica* 163:15-20, 1971.
12. Friede R: Zur operativen Behandlung des Nystagmus gravis nebst Bemerkungen zur Extraction der kongenitalen Katarakt. *Klin Monatsbl Augenheilkd* 128:451-455, 1956.
13. Kommerell G: Nystagmusoperationen zur Korrektur verschied ener Kopfwagshaltungen. *Klin Monatsbl Augenheilkd* 164: 172-191, 1974.
14. Parks MM: Congenital nystagmus surgery. *Am Orthopt J* 23:35-40, 1973.
15. Calhoun JH, Harley RD: Surgery for abnormal head position in congenital nystagmus. *Trans Am Ophthalmol Soc* 71:70-87, 1973.
16. Hugonnier R: Notre position actuelle sur les operations dirigees contre le nystagmus. *Ann Inst Barraquer* 12:327-340, 1974-5.
17. Fells P, Dulley B: Surgical management of compensatory head posture. *Trans Ophthalmol Soc UK* 96:90-95, 1976.
18. Dell'Osso LF, Flynn JT: Congenital nystagmus surgery: A quantitative evaluation of the effects. *Arch Ophthalmol*, in press.
19. Dell'Osso LF, Flynn JT, Daroff RB: Hereditary congenital nystagmus: An intra-familial study. *Arch Ophthalmol* 92:366-374, 1974.
20. Dell'Osso LF: Fixation characteristics in hereditary congenital nystagmus. *Am J Optom* 50:85-90, 1973.
21. Rosenbaum, AL Metz HS, Carlson M, Jampolsky AJ: Adjustable rectus muscle recession surgery. *Arch Ophthalmol* 95:817-820, 1977.
22. Calhoun JH: Personal communication.
23. Daroff RB, Trost BT, Dell'Osso LF: Nystagmus and related ocular oscillations, in Glaser JS (ed): *Neuro-ophthalmology Hagerstown, MD, Harper & Row, 1978.*