

## New Treatments for Infantile and Other Forms of Nystagmus

LOUIS F. DELL'OSSO

### ABSTRACT

Our objective was to translate the past 40 years of infantile nystagmus syndrome (INS) research (i.e., ocular motor recording and control-systems analysis) into a therapeutic approach. Our eye movement recordings use infrared reflection, magnetic search coil, and high-speed digital video systems. Each eye was calibrated during monocular fixation (fellow-eye occluded). We analyzed and displayed all data using software developed and written in our laboratory in the MATLAB (MathWorks, Natick, MA) environment, including the eXpanded Nystagmus Acuity Function (NAFX). Analysis of  $\approx 1000$  INS subjects over 40 years revealed waveform characteristics that can be exploited therapeutically. Analysis of postoperative INS data suggested that tenotomy and resuture (at the original insertions) of the extraocular muscles in the plane of the IN would improve foveation. The NAFX across normal gaze angles showed both peak-value increases and NAFX-curve broadening. We have concluded that all patients with nystagmus should have eye movement recording and analysis. The resulting accurate diagnosis and documentation of INS characteristics (undetectable by clinical observation) identify the best therapy. NAFX analysis allows estimation of postoperative acuities and determination of the most appropriate therapies. This eye movement-based procedure is the first to provide both the physician and patient with a post-therapeutic estimation of specific improvements

in visual function that is not possible from acuity measurements alone.

The most common types of benign nystagmus seen in infancy consist of the mixture found in the infantile nystagmus syndrome (INS), also known as congenital nystagmus, followed by the fusion maldevelopment nystagmus syndrome (FMNS), also known as latent/manifest latent nystagmus; additional types include the nystagmus blockage syndrome (NBS) and the spasmus nutans syndrome (SNS).<sup>1</sup> FMNS shares some clinical characteristics with INS, but it is *always* associated with strabismus and has a directional change with ocular cover, beating toward the fixating eye; it is rarely only present with occlusion of one eye. NBS is a special case of INS in which a purposive esotropia either damps the INS or converts it to a low-amplitude FMNS; both of the resulting waveforms allow higher acuity. SNS is a rare, disconjugate pendular nystagmus with head-nodding and tilt.<sup>2</sup> Accurate diagnosis of each type is necessary, because each has a different mechanism and relationship to strabismus, and each requires different therapy. This review concentrates on INS and the conclusions and recommendations that have resulted from ocular motility analysis. Commonly held clinical impressions about INS and FMNS have been found to be less than helpful, while others are simply wrong.

INS can appear at birth but is usually noted in early infancy (at the time of development of both motor and visual function) and persists throughout life. This is an ocular motor disorder that may (>50%) or may not be associated with afferent visual abnormalities

(e.g., albinism, aniridia, retinal dystrophies, optic nerve/foveal hypoplasia, retinal disease, ametropia, or congenital cataracts). Therefore, all INS patients should have a thorough examination of the eye (including slit-lamp examination for iris transillumination and fundus examination) and afferent visual system. This includes testing monocular and binocular vision, refraction, and ophthalmoscopy. Additional tests may also be indicated, such as color vision and visual fields, dark adaptation, electroretinography, visual evoked potentials, or orbital and central nervous system imaging such as MRI. A combination of visual and ocular motor system evaluations helps in understanding systemic diagnosis, visual system prognosis, and potential treatment options.

## METHODS

Recording and calibrating the eye movements of subjects with nystagmus (or with saccadic intrusions or oscillations) is fundamentally equivalent to recording and calibrating normal eye movements. Most of the recording systems that are currently available (infrared reflection [IR], magnetic search coil, or high-speed digital video) are adequate to record horizontal eye movements. The latter two are better suited when both horizontal and vertical eye movements are required; electro-oculography is not acceptable. Both IR and digital video are noninvasive and suitable for infants and children; the search coil requires placing a contact lens containing a coil of wire in each eye. Each eye must be calibrated monocularly (i.e., with the other occluded) by using only the foveation periods of the waveforms and simple, non-stress-inducing LED targets, not acuity targets. Further details of recording and calibrating nystagmus may be found elsewhere.<sup>3</sup>

Analysis of INS recordings is aimed at evaluation of the waveform at different gaze angles and its foveation quality, an objective measurement of which is the eXpanded Nystagmus Acuity Function (NAFX). It uses the time intervals of foveation periods and their position and velocity standard deviations to establish a measure of the “quality” of an INS waveform (i.e., how likely it was to allow good acuity). The details of using the NAFX software may be found elsewhere.<sup>4</sup>

## CLINICAL AND OCULAR MOTOR CHARACTERISTICS

The INS consists of one or more types of nystagmus with characteristic waveforms, head turns, tilts, or oscillations; rarely, the nystagmus becomes manifest later in life.<sup>5</sup> The term *congenital* should be thought of as a congenital “predisposition” for this particular type

of ocular motor instability, rather than taken literally. The mistaken presumption that the nystagmus was *caused* by poor vision and that two different types, “sensory-defect” and “motor-defect,” existed grew from the common association of INS with primary visual defects. The simplistic claim (mistakenly attributed to Dr. David Cogan) that these two putative types of INS could be identified by their waveforms (i.e., “sensory” = pendular and “motor” = jerk) has no basis in either clinical or eye movement data. In fact, Cogan specifically warned against such a distinction.<sup>6,7</sup> Eye movement recordings subsequently demonstrated that INS had the same waveforms and underlying mechanism, regardless of the coincidental, facilitating existence of a sensory deficit. Thus, the nystagmus is the *direct* result of an ocular motor control instability that may develop with or without an accompanying sensory deficit. INS may appear spontaneously or be familial. Hereditary INS may be sex-linked, recessive, or dominant; the dominant form has been linked with chromosome 6p12.<sup>8</sup> Recent genetic studies have identified genes and genetic loci associated with INS and retinal developmental defects accompanying some forms of INS.<sup>9</sup>

Although INS waveforms may appear to be either pendular or jerk, eye movement recordings have revealed that both stem from the same underlying pendular oscillation.<sup>10</sup> Because of this, the originating slow phases of jerk waveforms have increasing velocities with the normal saccadic fast phases bringing the eye back to target. Pure pendular and jerk waveforms are not conducive to good acuity because of their extremely short foveation times (i.e., the time intervals when eye position maintains the target image within the foveal area and in which eye velocity is less than 4 deg/s); hence, in INS we seldom see pure pendular or jerk waveforms but rather waveforms with extended foveation. Many of the resulting INS waveforms are pathognomonic and are an expression of the attempts of the saccadic and fixation subsystems to increase foveation time; therefore, they are *diagnostic*, as they are found in no other type of nystagmus. Individuals in families with INS may display the same subset of the 12 known INS waveforms.<sup>11,12</sup> Infants may exhibit mature jerk INS waveforms, or they may change with age. Waveform maturation reflects saccadic modification of the underlying pendular waveform by the developing visual and motor systems, and also reflects the infant’s state of visual attention. Eye movement recordings can accurately diagnose infants based on those waveforms that are pathognomonic for INS, whether or not mature waveforms are present. All INS patients, regardless of the clinical appearance of their nystagmus (pendular or jerk), should have a thorough eye and afferent visual-system examination in conjunction with eye movement recordings.

The clinical characteristic features of INS summarized in Table 11.1 are not specific enough to reliably differentiate INS from FMNS; many erroneous clinical interpretations are listed, the most important of which is the mistaken belief that a direction reversal with alternate eye cover is diagnostic of FMNS, which it is not. The nystagmus that is present may be either INS with a latent component or FMNS (see Table 11.1 and subsequent sections). Because only eye movement recordings can accurately diagnose nystagmus and are necessary for the highest standard of care for nystagmus patients, this review will presume eye movement recordings are available for determining diagnosis, treatment, and the direct effects of treatment.

Most INS patients have a mainly horizontal nystagmus, albeit many times with a minor torsional component; vertical, oblique, and circular waveforms of INS may also be present (see Table 11.1). Horizontal INS remains horizontal, even in vertical or oblique directions of gaze, and may not change on occlusion of either eye; this is an important diagnostic indicator. Some INS patients may have a latent component that results in a direction reversal with occlusion—the INS waveform reverses direction due to a shift in the “null” position. Although this mimics FMNS clinically, the waveforms can be only be accurately differentiated by eye movement recordings.

The presence of a “null” position of gaze, the so-called gaze-angle null, where nystagmus damps is an important diagnostic feature of INS. However, the NAFX “peak,” where the nystagmus waveform is best for acuity, is a more accurate and clinically useful characterization. A preferred head-turn may appear if the NAFX peak is narrow and not straight ahead (i.e., gaze-angle null); even very young children may adopt this to improve their vision. Although primary-position visual acuity and stereo acuity are all that are usually measured clinically, visual function depends on other factors. A more important measure of both visual function and therapeutic improvement may be the degradation of a patient’s acuity with lateral gaze (lateral to their idiosyncratic angle of maximal acuity, formerly known as their “null” angle). Therefore, visual acuities should be measured by the clinician at different gaze angles by fixing the visual stimuli and moving the head to known angles.<sup>13</sup> Also needed are head-posture assessment, identification of asymmetric (a)periodic alternating nystagmus (APAN), and cycloplegic refraction. APAN often goes undetected,<sup>14-16</sup> which results in improper muscle-shifting surgery.<sup>17</sup> Any refractive error should be corrected with glasses or contact lenses (the latter being preferred).

Figure 11.1 shows how the NAFX peak may shift with changes in the fixating eye in cases of INS (with a latent component) plus strabismus (esotropia, left,

Table 11.1 Characteristics of Infantile Nystagmus Syndrome

Clinical observations
Binocular with similar amplitude in both eyes
Usually horizontal (vertical, diagonal, or elliptical rare and <i>small components missed</i> )
“Pendular” or “jerk” appearance (often <i>misdiagnosed</i> )
Apparent jerk direction not always correct (often <i>misdiagnosed</i> )
Asymmetric aperiodic alternation possible (baclofen ineffective)
Provoked or increased by “fixation attempt” and stress
Abolished in sleep or inattention to visual tasks
Diminished (damped) by gaze-angle or convergence nulls
Reversal with cover (often <i>misdiagnosed</i> as FMNS)
Apparent “inversion” of the optokinetic reflex ( <i>misinterpreted</i> )
Apparent “reversal” of smooth pursuit ( <i>misinterpreted</i> )
Associated head oscillation ( <i>misinterpreted as compensatory</i> )
Associated head turn and/or tilt
No oscillopsia except under rare conditions
Patients complain of being “slow to see”
Ocular motor findings
Increasing-velocity slow phases (some linear)
Distinctive waveforms with foveation periods and braking saccades
Many INS waveforms cannot be differentiated, nor can their direction be determined, clinically ( <i>misdiagnosed</i> as nystagmus type or jerk direction)
“Horizontal” INS actually has a torsional component and subclinical SSN
Gaze-modulated, not gaze-evoked, nystagmus
Normal smooth pursuit, optokinetic, and vestibulo-ocular systems (each causing a shift in the INS “null”)
Reversal of the IN with alternate cover due to INS “null” shift (INS with a latent component <i>misdiagnosed</i> , “FMNS”)
Two head postures due to the INS “null” shift in INS with a latent component ( <i>misdiagnosed</i> as INS with “two nulls”)
Reversal of the IN during optokinetic stimulation ( <i>misinterpreted</i> as “inversion” of the optokinetic reflex)
Reversal of the IN during smooth pursuit ( <i>misinterpreted</i> as “reversal” of smooth pursuit)
Associated head oscillation <i>not compensatory</i> due to normal vestibuloocular reflex
Head turns or tilts provide waveforms with the best foveation quality
Convergence damping improves foveation over a broader range of gaze angles
Tenotomy portion of EOM surgery improves foveation over a broader range of gaze angles
Target acquisition time much longer than saccadic reaction time, reducing visual function

FMNS, fusion maldevelopment nystagmus syndrome; IN, infantile nystagmus; INS, infantile nystagmus syndrome; SSN, see-saw nystagmus.

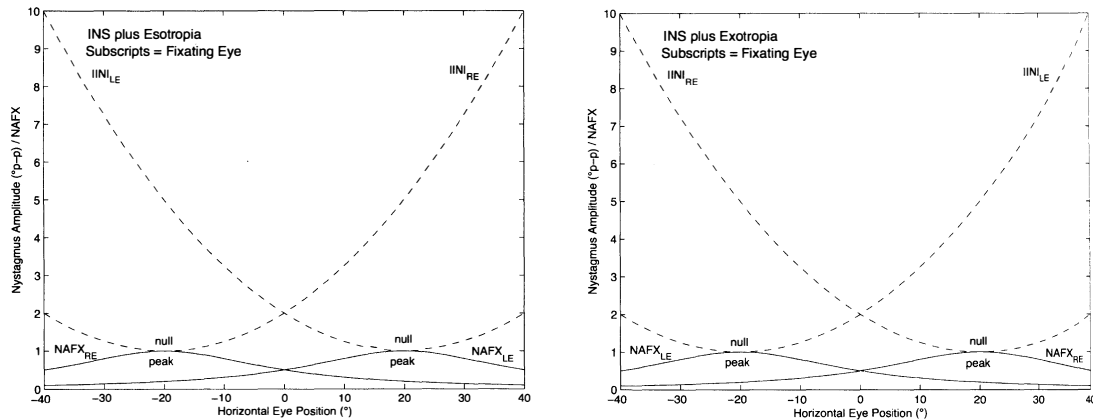


Figure 11.1 Demonstration of the infantile nystagmus syndrome (INS) “null” and eXpanded Nystagmus Acuity Function (NAFX) peak shifts due to a latent component in patients with INS plus esotropia (left) and exotropia (right). Large shifts result in head turns that lead to the clinical misimpression of INS with “two nulls,” when in fact there is one null that shifts with changes in the fixating eye.

and exotropia, right). Such cases are often misdiagnosed as INS with “two nulls” when, in fact, there is one null, the position of which is determined by which eye is fixating. These cases, although diagnostic challenges, may be successfully treated by combining the four-muscle tenotomy procedure described below with strabismus recessions.<sup>18</sup> Convergence may also damp INS (called a vergence null), allowing near visual acuity to be better than distance acuity; this, too, should be measured by the clinician. Convergence also broadens the NAFX-versus-gaze-angle peak, allowing better acuity over a larger portion of the visual field; this is called the “longest foveation domain” (LFD).<sup>19,20</sup>

Increasing visual attention (“fixation attempt”) may increase the intensity of INS (as well as the head oscillations that often accompany INS), and visual inattention damps it (it is also diminished during sleep).<sup>21</sup> Recent evidence isolated the stress often associated with increased fixation attempt as the factor that exacerbates INS rather than the simple act of trying to see higher acuity targets.<sup>22</sup> However, fixation attempt is responsible for the genesis of INS, which disappears when the patient is inattentive or sleeping.

Individuals with INS usually do not experience an illusory oscillatory movement of their environment (oscillopsia).<sup>23,24</sup> The absence of oscillopsia in INS, and also in FMNS, suggests that both oscillations occur within an efference copy feedback loop that serves to nullify the effects of retinal-image oscillation induced by either of these instabilities.<sup>25</sup> *Any patient with a primary complaint of oscillopsia should be assumed to have an acquired condition until proven otherwise.* However, nearly 40% of INS patients may, at least occasionally, experience oscillopsia.<sup>26</sup> Most of

these instances are associated with exacerbations of the patient’s nystagmus by fatigue, illness, stress, or looking in a “nonpreferred” gaze direction.

Attempting a visually demanding task may cause head nodding in some INS patients. This reflects the effects of the nystagmus signal that drives both the eyes and the neck muscles, to which the signal has access via the semilunar ganglion.<sup>27</sup> Head nodding is *not* compensatory, as the patient’s normal VOR cancels the effects of head oscillation during the periods of target foveation normally present in the INS waveform. *The head tremor in INS is easily suppressed voluntarily, but this is not the case in acquired disease.*

## THERAPIES

Current therapies for nystagmus may act either *centrally* or *peripherally*. Central therapies (neurosurgical or pharmacological) are directed at the central source of the nystagmus with the aim of directly reducing the initiating brainstem nystagmus signal (the motor command). Peripheral therapies (pharmacological, optical, or surgical) are directed at a peripheral mechanism to directly reduce the resulting eye oscillation without affecting the brainstem nystagmus motor command. An additional, new therapy to treat nystagmus is *afferent* therapy. An example is gene therapy applied to the retina to correct genetic deficits that impair vision directly and may facilitate the development of nystagmus (e.g., RPE65 deficiency and INS).<sup>28</sup> Figure 11.2 illustrates the anatomical sites of each type of therapy, the neurophysiological signals present, and the measurements of each therapy’s direct and indirect effects.

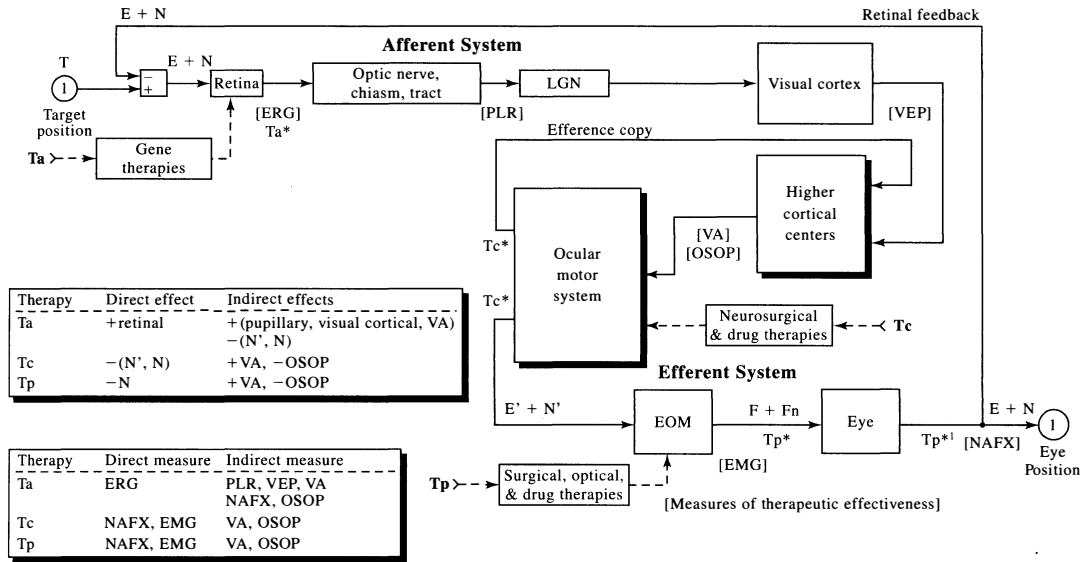


Figure 11.2 A block diagram of the ocular motor system indicating the types of therapeutic intervention for nystagmus, their anatomic sites, and direct and indirect measurements of their effectiveness. Ta is afferent therapy for deficits in the visual system (shown here, gene therapy for retinal deficiencies), Tc is central (neurosurgical or drug) therapy for nystagmus, and Tp is peripheral (surgical, optical, or drug) therapy for nystagmus. Shown in square brackets are the sites of therapeutic tests of visual and ocular motor function. The direct and indirect effects of each type of therapy and the direct and indirect outcome measures for each are listed in the legend boxes. e, retinal error; E, eye position; EMG, electromyogram; ERG, electroretinogram; F, extraocular muscle force; Fn, extraocular muscle nystagmus force; n, nystagmus error; N, nystagmus; NAFX, eXpanded Nystagmus Acuity Function; PLR, pupillary light reflex; VEP, visual evoked potential; +, improved, higher or better; -, diminished, lower or less; \* or \*1, site of primary effect of therapy; ', motor commands.

The most accurate measure of any therapy is a measure of its *direct* effects, rather than an indirect measure of a neurophysiological function that is dependent on other intervening functions, each subject to idiosyncratic deficits. For visual performance measures, before and after therapy in nystagmus, most clinicians only measure resolution limit; visual acuity is the standard for most visual disorders. However, in nystagmus (especially INS) this is not an accurate or inclusive measure, because the nystagmus may vary with gaze angle and worsen with fixation effort. Also, many patients with INS have one or more afferent visual deficits that limit potential visual acuity, whether or not they were related to the series of events in the motor system that resulted in ocular motor instability. Finally, even for those with no afferent deficits, mental status (stress) often results in a measured visual acuity that is lower than the acuity achieved during normal life when there is no stress. Visual performance in nystagmus is dependent on three factors: retinal image slip velocities, foveation accuracy and variability, and the presence of ocular and visual pathway anomalies. NAFX analysis of the foveation-period quality for the fixating eye in primary position and the gaze-angle

modulation of the NAFX provide direct measures of most therapies and can accurately gauge the improvement of visual function in INS. Therefore, we recommend the use of the NAFX to measure therapeutic effectiveness in nystagmus. When recorded under the same nonstressful conditions used in our lab, the INS waveforms and their measures (e.g., the NAFX) are consistent over time, and any changes post-therapy can be ascribed to the therapy.

Eye movement recordings document the characteristic waveforms of the nystagmus that definitively distinguish INS from FMNS and other, acquired forms of nystagmus. This diagnostic information, along with the patient's idiosyncratic INS variation with both gaze angle and convergence, form the foundation for effective therapeutic intervention. The NAFX values over different gaze and convergence angles can be used to predict the expected therapeutic improvement in peak visual acuity and the range of gaze angles with high acuity.<sup>20</sup> Different therapies have been tried for INS, from prisms to biofeedback, including recently reported improvement with gabapentin in a small number of patients.<sup>29</sup> However, the mainstay of therapy is surgery.

## Surgical

Surgical treatment has classically been performed for two main reasons: (1) correction of anomalous head posture and (2) improvement of visual performance. Oscillopsia is not a problem in INS and thus not an indication for treatment, unlike in acquired nystagmus. There have been two main types of surgery advocated: (1) Kestenbaum surgery—horizontal rectus-muscle paired recessions and resections to shift the eye position to take advantage of a gaze-angle null, and (2) artificial divergence surgery—bimedial rectus-muscle recessions to create mild divergence (exophoria) of the eyes and take advantage of a convergence-angle null. We recommend the following combinations of surgery based on preoperative eye movement recordings and analysis.

1. If the NAFX improves with convergence and/or convergence damps nystagmus in nonstrabismic, binocular patients, “artificial divergence” plus tenotomy surgery is recommended.<sup>30</sup> This consists of bimedial horizontal rectus recessions plus bilateral horizontal rectus tenotomies. The recessions create mild divergence (exophoria) of the eyes such that the patient is forced to employ fusional vergence to see, and this convergence damps the nystagmus, possibly due to pulley repositioning. This surgery should only be used if the patient has fusion, and it is usually offered to patients who have responded to a trial with base-out prisms (with -1.0S if pre-presbyopic).
2. If there is a sharp NAFX peak and/or compensatory head posture with a “null” zone, the Kestenbaum surgery is the best approach.<sup>31</sup> This is a *four-muscle* surgery consisting of yoke-paired recessions (Anderson)<sup>32</sup> and resections (Goto)<sup>33</sup> of the horizontal rectus muscles to shift the eyes opposite to an eccentric NAFX peak (i.e., in the direction of the head turn). The two muscles that move the eyes in the direction opposite to the head turn are recessed, and the two muscles that move the eyes in the direction of the head turn are resected (see Lee<sup>34</sup> for a discussion of these surgical techniques). The resulting innervation to primary position places the eyes at the new centered NAFX peak. Although the Kestenbaum surgery was originally used only for large head turns, the discovery of important waveform improvements due to the tenotomies that are an integral part of the procedure now indicate its use for any narrow, eccentric NAFX peak, regardless of the amount of eccentricity or the presence of a head turn. The same therapeutic benefits may be achieved by a combined Anderson-plus-tenotomy procedure, whereby yoke-paired recessions of two

horizontal rectus muscles (to shift the eyes opposite to an eccentric NAFX peak) plus tenotomies and reattachments to their original insertions of the other pair of horizontal rectus muscles (to complete the four-muscle tenotomy damping effect) are performed. Because tenotomy has been identified as the underlying reason for damping INS, two-muscle procedures like the Anderson or Goto should not be used without combining them with tenotomy of the remaining two muscles in the plane of the nystagmus.

3. If both 1 and 2 apply, bimedial horizontal rectus recessions plus bilateral horizontal rectus tenotomies are recommended; vergence NAFX peaks are higher than version peaks.<sup>35</sup>
4. If there are neither convergence nor gaze-angle improvements in the INS, the four-muscle tenotomy procedure is recommended.<sup>36-39</sup> As indicated above, we use the NAFX values to (a) determine which patients should have surgery and (b) predict the expected improvements in both best acuity and the gaze-angle range of high acuity.<sup>20</sup>

Tenotomy is thought to affect eye muscle proprioception and reduce the small-signal (slow-phase) gain to improve nystagmus with or without a “null” zone.<sup>40</sup> Large recessions of all the horizontal rectus muscles have been recommended by some strabismus surgeons<sup>41,42</sup> for similar indications, with the premise that the force exerted by all the muscle is weakened, thereby damping nystagmus. However, this affects the ocular motility and can cause undesirable exotropia. Because tenotomy accomplishes INS damping without altering ocular motor homeostasis (i.e., no muscles are moved), we do not recommend maximal recessions of the four horizontal rectus muscles for INS patients, especially those who have binocularity and are at risk to develop diplopia as a result of weakening the eye muscles. Tenotomy’s efficacy has been demonstrated in an animal study, a masked-data clinical trial, and subsequently in INS patients in whom the “null” broadening effects were demonstrated. It has also been used successfully to damp acquired nystagmus and reduce oscillopsia in acquired pendular nystagmus secondary to MS<sup>43</sup> and downbeat nystagmus of unknown etiology.<sup>44</sup>

INS patients who also have strabismus should have strabismus correction added to either of the nystagmus surgeries described in 2 or 4; convergence-damping surgery of INS is contraindicated by strabismus. However, if an esotropia is present, bimedial horizontal rectus recessions may be added to the nystagmus surgery to correct the strabismus. Tables 11.2 and 11.3 summarize the different conditions that may be present in INS (Table 11.2) and FMNS (Table 11.3) and provide guidelines for the respective types of nystagmus and

Table 11.2 Surgical Treatment Guidelines for Infantile Nystagmus Syndrome\*

Without strabismus	
Vergence “null” <sup>1</sup>	Bimedial rectus recessions ( $\pm$ bilateral rectus tenotomies)
Gaze-angle “null” <sup>2</sup>	Kestenbaum (4-muscle R&R) Anderson (2-muscle recessions) + 2-muscle tenotomies
Both types of “nulls” <sup>2</sup>	Bimedial rectus recessions ( $\pm$ bilateral rectus tenotomies)
No or 0° “null” <sup>1</sup>	Tenotomy (4-muscle)
With strabismus	
$\pm$ Near “null” <sup>1</sup>	ET: Bimedial rectus recessions (for strabismus) + bilateral rectus tenotomies (for INS) XT: Bilateral rectus recessions (for strabismus) + Bimedial rectus tenotomies (for INS)
Gaze-angle “null” <sup>2</sup>	Kestenbaum (4-muscle, 2 resections and 2 recessions) + Strabismus recession of the deviated eye (ET or XT) Anderson (2-muscle recessions) + 2-muscle tenotomies + Strabismus recession of the deviated eye (ET or XT)
Both types of “nulls” <sup>2</sup>	Kestenbaum (4-muscle, 2 resections, and 2 recessions) + Strabismus recession of the deviated eye (ET or XT) Anderson (2-muscle recessions) + 2-muscle tenotomies + Strabismus recession of the deviated eye (ET or XT)
No or 0° “null” <sup>1</sup>	Tenotomy (4-muscle) + Strabismus recession of the deviated eye (ET or XT)

\* Diagnosed by eye-movement recordings, not clinically. <sup>1</sup> With or without asymmetric (a)periodic alternating nystagmus (APAN); <sup>2</sup> No APAN; E/XT, eso-/exotropia; R&R, recession-resection. Tenotomy procedure is detachment and reattachment of the muscle at its original insertion. 4(2)-muscle means the 4 (or 2) muscles—2 (or 1) per eye—in the major plane of the nystagmus. Source: National Eye Institute. *The Classification of Eye Movement Abnormalities and Strabismus (CEMAS): Report of an NEI Sponsored Workshop, 2001*. National Eye Institute Web site. <http://catalog.nei.nih.gov/productcart/pc/viewPrd.asp?idcategory=0&idproduct=52>. Accessed January 21, 2008; Weissman BM, Dell’Osso LF, Abel LA, Leigh RJ. Spasmus nutans: a quantitative prospective study. *Arch Ophthalmol*. 1987;105:525–528.

strabismus surgery recommended for each; the patient’s individual afferent and efferent characteristics should determine the specific surgical approach taken. The addition of tenotomies to strabismus surgeries for FMNS reflects our expectation that they will prove to be as beneficial as in INS and acquired nystagmus. These tables are only guidelines for uni-planar nystagmus; more complete details, including multiplanar nystagmus and anomalous head positions, may be found elsewhere.<sup>1</sup>

With precise eye movement recording, accurate identification of NAFX peaks allows surgeons to more accurately plan eye muscle surgery without having to

rely on the measurement of head posture, which is under the patient’s control and is therefore both variable and unreliable. The eye movement analysis of tenotomy has shown that because of the NAFX peak broadening, the various surgical formulas derived for strabismic eye alignment are unnecessary for nystagmus rotations in binocular patients, and the more homeostatic equal resections and resections would be preferred. Postoperative recordings of waveforms have shown the predicted shift in the NAFX peak, broadening of the LFD, and improvement in the NAFX, thereby increasing the visual performance outcome. Multiplanar INS may require two-stage surgeries, first

Table 11.3 Surgical Treatment Guidelines for Fusion Maldevelopment Nystagmus Syndrome\*

ET (Adducting >> Abducting eye fixation)	Bimedial rectus recessions (for strabismus) (+ > -) Bilateral rectus tenotomies (for FMNS)
XT (Adducting >> Abducting eye fixation)	Bilateral rectus recessions (for strabismus) (+ > -) Bimedial rectus tenotomies (for FMNS)
<b>Unioocular fixation</b>	
Primary position	Strabismus recession of the deviated eye (ET or XT) (+ > -) 3-m tenotomies (for FMNS)
ET (Adduction >> Abduction)	Bimedial rectus recessions (for strabismus) (+ > -) Bilateral rectus tenotomies (for FMNS)
XT (Abduction >> Adduction)	Bilateral rectus recessions (for strabismus) (+ > -) Bimedial rectus tenotomies (for FMNS)

\* Diagnosed by eye-movement recordings, not clinically. E/XT, eso-/exotropia; FMNS, fusion maldevelopment nystagmus syndrome. Tenotomy procedure is detachment and reattachment of the muscle at its original insertion. 3-m means the 3 muscles—2, fixating, and 1, deviated eye—in the major plane of the nystagmus.

in the plane of the major component of the INS and then, if necessary, in the secondary plane; in some cases, the improvements from the first stage will negate the necessity for the second.

#### Nonsurgical

Base-out (BO) prisms may be used to exploit convergence nulls in binocular INS patients. Usually 7 diopter (D) BO prisms are added to the patient's refraction with -1.0S added for pre-presbyopic patients (the latter must be removed when presbyopia occurs). Once converged, INS remains damped at most gaze angles (especially those in the central  $\pm 20^\circ$  of gaze)<sup>19</sup>; therefore, we recommend equal-value, BO prisms rather than composite prisms for those with both eccentric and near NAFX peaks. This minimizes the amount of prism in each eye and reduces chromatic distortion.

For those whose INS damps with afferent stimulation of the ophthalmic division of the trigeminal nerve, soft contact lenses will both correct refractive errors and improve the nystagmus waveform.<sup>45-47</sup> For other INS patients, contact lenses may also be prescribed for their optical correction and for use in sports. Contact lenses may be prescribed in addition to surgical therapy, providing additional improvement.

#### NAFX-BASED THERAPY DETERMINATION AND PREDICTED OUTCOMES

##### Using the NAFX to Determine Post-Therapy Efficacy

Based on the NAFX data gathered in the study of the effects of tenotomy, two curves were produced: (1) pretenotomy NAFX versus percent of NAFX improvement and (2) pretenotomy LFD versus percent of LFD improvement.<sup>20</sup> The highest percentage improvements were found for those patients with the worst pretenotomy values (i.e., corresponding to the worst visual acuities and the narrowest high-acuity range of gaze angles). The least improvements were found for patients whose INS waveforms were conducive to high acuity and/or allowed a broad high-acuity range of gaze angles. Thus any patient with a low NAFX, a low LFD, or both should benefit from tenotomy (or other four-muscle) surgery. Conversely, only those patients whose NAFX and LFD were *both* high would not benefit from surgical therapy, at least for these two static measures of visual function.

##### Using the NAFX to Predict and Determine Post-Therapy Outcomes

Once the NAFX and LFD percent-improvement curves are used to determine whether surgery is indicated,

they can be used in conjunction with the measured pre-surgical peak visual acuity to estimate the expected post-surgical improvement in visual acuity and in the breadth of the high-acuity range of gaze angles. Finally, they can also be used to measure the actual improvements in both measures of visual function. The following example demonstrates how this is done.

Our fictional patient is a 9-year-old child with nystagmus whose visual acuity is 20/200 and, for simplicity, who has no strabismus. The patient has one of the many afferent deficits associated with INS (any one will do here). The results of the patient's ocular motor recordings and analysis yield a diagnosis of INS with a primary position peak NAFX of 0.3 and an LFD of  $15^\circ$ .

First, we choose the proper NAFX-versus-acuity line based on the patient's age (Fig. 11.3, top left, heavy line). Second, we plot the NAFX point on the age-matched line. This establishes a potential visual acuity of 20/70. That is, if a patient with an NAFX of 0.3 had only INS, the measured acuity would be 20/70.

Because the measured acuity was actually 20/200, we know there is an afferent deficit. To determine its effect on visual acuity, we draw another line with the same slope as the age-matched line through the NAFX = 0.3 point plotted at the measured acuity (Fig. 11.3, top right, dashed line). The intercept of the dashed line at NAFX = 1 (i.e., if there were no INS) shows that the afferent deficit above would have reduced the visual acuity from 20/20 to 20/25, or 25%.

To determine whether surgery (in this case, a four-muscle tenotomy) is indicated, we plot the presurgical NAFX on the NAFX improvement curve (Fig. 11.3, middle left). The expected NAFX improvement is 60% and thus surgery is indicated.

To estimate the expected post-tenotomy improvement in NAFX and *measured* acuity, we plot the calculated post-tenotomy NAFX point ( $0.3 + 0.3[0.60] = 0.48$ ) on the dashed line (Fig. 11.3, middle right). Thus the post-tenotomy visual acuity should improve to 20/70, or 185.7%.

To estimate the expected post-tenotomy improvement in LFD, we plot the pretenotomy LFD point on the LFD improvement curve (Fig. 11.3, bottom). The expected LFD improvement is 120%, yielding an estimated post-tenotomy LFD of  $15^\circ + 1.2(15^\circ) = 33^\circ$ . From the post-tenotomy eye movement data, we can calculate the actual improvements in both the NAFX and LFD and measure the visual acuity. We can then compare our estimates with the actual results.

#### DISCUSSION

The ideal measure of any nystagmus therapy is one that is both a direct outcome measure of that therapy



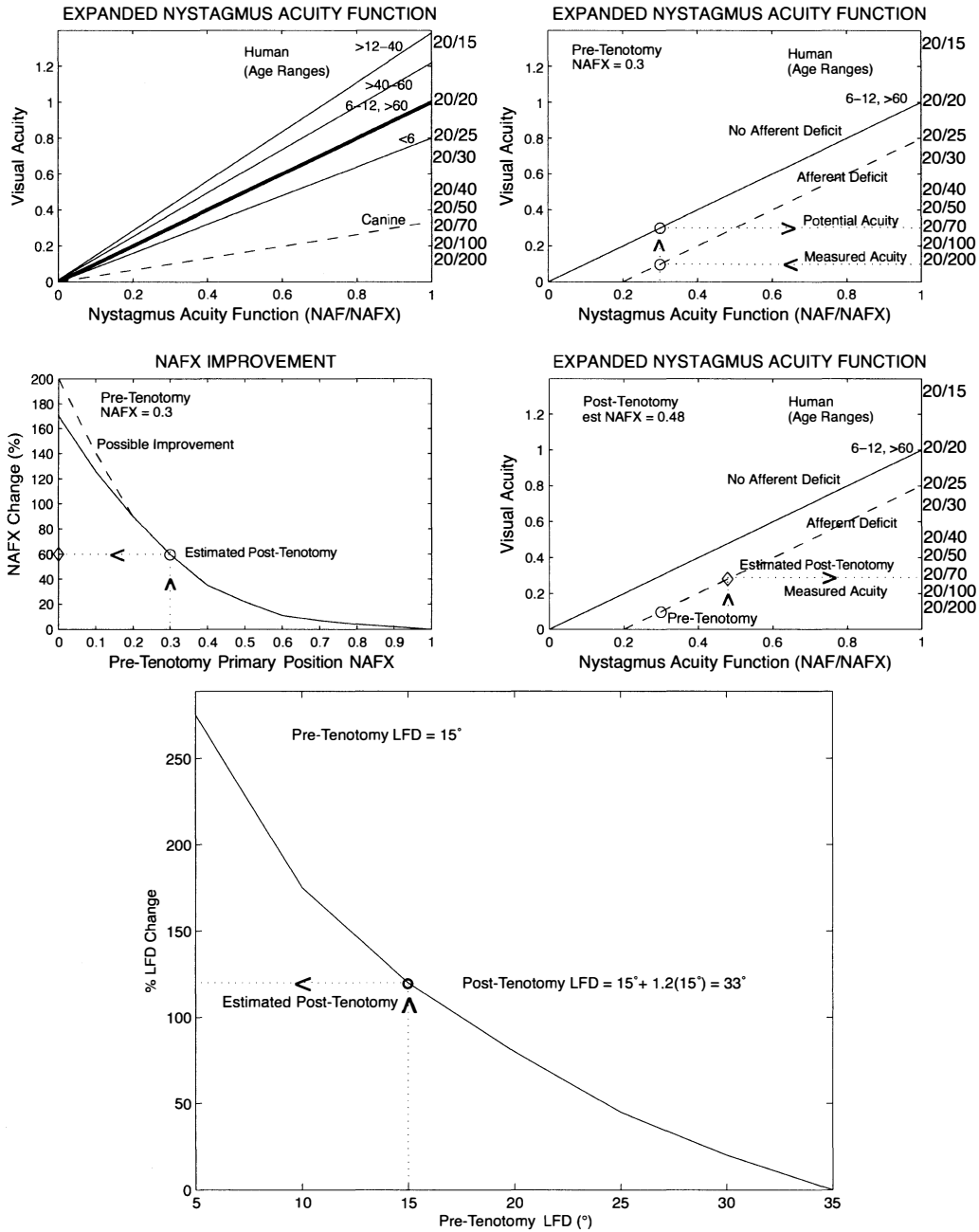


Figure 11.3 Demonstration of the use of the eXpanded Nystagmus Acuity Function (NAFX) and longest foveation domain (LFD) function to estimate post-tenotomy improvements in visual acuity and broadening of high-acuity gaze-angle range, respectively. NAFX vs. visual acuity lines for different patient age ranges (top left). Plots of the patient's pretenotomy NAFX and measured visual acuity points (top right) when (A) there is no significant sensory deficit accompanying the INS or (B) there is a sensory deficit and a dashed line is drawn through it. (A) Determination of estimated NAFX improvement (bottom left). Determination of estimated visual acuity improvement (bottom right). Bottom center: Determination of estimated high-acuity gaze-angle range improvement. INS, infantile nystagmus syndrome.

and, if possible, a predictive measure of the medical goals of improved primary-position acuity and *improved visual function*. As Figure 11.2 shows, the electroretinogram, pupillary light reflex, and visual evoked potential are the most direct measures for afferent therapies. Each is predictive of visual acuity, which is determined slightly upstream, albeit requiring higher cortical function. In animal studies, where visual acuity is not easily measured, the NAFX provides an easily obtainable, in vivo measure of gene therapy's effectiveness by measuring nystagmus waveform improvements. Although an indirect measure of afferent therapy, the NAFX predicts potential acuity. For central and peripheral therapies, the best and least invasive direct measure is the NAFX; the electromyogram is both invasive and not easily related to visual acuity. Because the NAFX both predicts acuity improvements and measures increases in the range of gaze angles over which those improvements are present, it was chosen as the primary outcome measure of the effectiveness of tenotomy<sup>36,37</sup> and in two masked clinical trials of tenotomy for INS in adults<sup>38</sup> and children.<sup>39</sup> In many patients with INS, increasing the effective high-acuity visual field does more to improve visual function than increasing Snellen acuity in one small region of the visual field—unfortunately, this is neither appreciated nor measured in the physician's office. It does explain why a given therapy may result in a patient reporting that he can “see better” even when the pre- and post-therapeutic primary-position Snellen acuities are essentially equal.

As Figure 11.2 illustrates, peripheral surgical therapy acts at the muscle to damp the resulting nystagmus; it does not change the brainstem nystagmus signal itself. Also, it is equally effective in damping both infantile and acquired nystagmus (the muscle cannot determine the origin of the nystagmus signal). Central pharmacological therapy is administered to damp the brainstem nystagmus signal. Because of their independence, if both central and peripheral therapies are applied together (in either order), the result will be the multiplicative damping from both therapies. This type of “dual-mode” therapy has been shown to maximally damp the nystagmus and maximally improve visual function.<sup>43</sup>

We have shown, for the first time and with the use of eye movement data and the NAFX analyses, that we can accurately determine a priori whether the patient has INS or some other form of nystagmus, whether surgery will improve visual function enough to justify it, what surgery is best for each patient, how much visual acuity will improve, and how much the high-acuity range of gaze angles will broaden. None of these diagnostic or therapeutic assessments is possible from only a clinical examination and visual acuity measurement.

Finally, we have recently uncovered a “dynamic” source of visual function deficit in INS that causes patients to complain that they are “slow to see.” They have an elevated target acquisition time (far longer than their slightly elevated saccadic reaction time).<sup>44</sup> This raises the question, “Does nystagmus surgery (specifically, four-muscle tenotomy) also improve visual function by reducing target acquisition time?” Preliminary data suggest that it does.

Eye movement recordings and NAFX analysis used in the diagnostic workup and therapeutic decision processes should produce accurate and repeatable diagnoses and reduce repeat (i.e., corrective) nystagmus surgeries. Complex cases combining INS, strabismus, latent components, and even FMNS require eye movement recordings and analyses.

**ACKNOWLEDGMENTS** The author acknowledges the following colleagues, whose collaboration during the past 40 years of INS research formed the foundation for this data-based approach to diagnosis, therapy, and evaluation of visual function improvement (listed chronologically): L. Stark, G. Gauthier, R. B. Daroff, J. T. Flynn, L. A. Abel, D. Schmidt, S. Traccis, C. Ellenberger, R. J. Leigh, A. Tabuchi, R. M. Steinman, H. Collewijn, J. Van der Steen, B. M. Weissman, R. W. Hertle, N. V. Sheth, J. Shallo-Hoffmann, R. W. Williams, L. Averbuch-Heller, J. B. Jacobs, B. F. Remler, D. W. Hogan, D. M. Erchul, R. L. Tomsak, G. M. Acland, J. Bennett, R. A. Burnstine, A. Serra, and Z. I. Wang.

This work was supported in part by the Office of Research and Development, Medical Research Service, U.S. Department of Veterans Affairs.

## References

1. National Eye Institute. *The Classification of Eye Movement Abnormalities and Strabismus (CEMAS): Report of an NEI Sponsored Workshop, 2001*. National Eye Institute Web site. <http://catalog.nei.nih.gov/productcart/pc/viewPrd.asp?idcategory=0&idproduct=52>. Accessed January 21, 2008.
2. Weissman BM, Dell'Osso LF, Abel LA, Leigh RJ. Spasmus nutans: a quantitative prospective study. *Arch Ophthalmol*. 1987;105:525–528.
3. Dell'Osso LF. Recording and calibrating the eye movements of nystagmus subjects. *OMLAB Report #011105, 2005:1-4*. Ocular Motility Laboratory Website. [www.omlab.org/OMLAB\\_page/Teaching/teaching.html](http://www.omlab.org/OMLAB_page/Teaching/teaching.html). Last updated February 7, 2005. Last accessed March 3, 2008.
4. Dell'Osso LF. Using the NAFX for eye-movement fixation data analysis and display. *OMLAB*

- Report #111005, 2005:1-7. Ocular Motility Laboratory Web site. [www.omlab.org/OMLAB\\_page/Teaching/teaching.html](http://www.omlab.org/OMLAB_page/Teaching/teaching.html). Last updated January 29, 2008. Last accessed March 3, 2008.
5. Gresty MA, Bronstein AM, Page NG, Rudge P. Congenital-type nystagmus emerging in later life. *Neurology*. 1991;41:653-656.
  6. Cogan DG. Congenital nystagmus. *Can J Ophthalmol*. 1967;2:4-10.
  7. Dell'Osso LF, Hertle RW, Daroff RB. "Sensory" and "motor" nystagmus: erroneous and misleading terminology based on misinterpretation of David Cogan's observations. *Arch Ophthalmol*. 2007;125(11):1559-1561.
  8. Kerrison JB, Koenekoop RK, Arnould VJ, Zee D, Maumenee IH. Clinical features of autosomal dominant congenital nystagmus linked to chromosome 6p12. *Am J Ophthalmol*. 1998;125:64-70.
  9. Kerrison JB. New genetic, pathophysiologic, and therapeutic issues in nystagmus. *Curr Opin Ophthalmol*. 1999;10:411-419.
  10. Dell'Osso LF. Biologically relevant models of infantile nystagmus syndrome: the requirement for behavioral ocular motor system models. *Semin Ophthalmol*. 2006;21(2):71-77.
  11. Dell'Osso LF, Daroff RB. Congenital nystagmus waveforms and foveation strategy. *Doc Ophthalmol*. 1975;39:155-182.
  12. Dell'Osso LF. Congenital, latent and manifest latent nystagmus: similarities, differences and their relationship to strabismus. *J Jpn Orthop Coun*. 1985;22:12-15.
  13. Yang D, Hertle RW, Hill VM, Stevens DJ. Gaze-dependent and time-restricted visual acuity measures in patients with Infantile Nystagmus Syndrome (INS). *Am J Ophthalmol*. 2005;139(4):716-718.
  14. Shallo-Hoffmann J, Dell'Osso LF, Dun S. Time-varying, slow phase component interaction in congenital nystagmus. *Vision Res*. 2004;44:209-220.
  15. Shallo-Hoffmann J, Faldon M, Tusa RJ. The incidence and waveform characteristics of periodic alternating nystagmus in congenital nystagmus. *Invest Ophthalmol Vis Sci*. 1999;40:2546-2553.
  16. Shallo-Hoffmann J, Riordan-Eva P. Recognizing periodic alternating nystagmus. *Strabismus*. 2001;9(4):203-215.
  17. Shallo-Hoffmann JA, Visco F Jr, Tusa RJ. Mis-use of the artificial divergence operation to treat congenital nystagmus in a patient with infantile strabismus and acromatopsia: analysis of eye movement recordings. In: Sharpe JA, ed. *Neuro-ophthalmology at the Beginning of the New Millennium*. Englewood, NJ: Medimond Medical Publications; 2000:125-129.
  18. Wang ZI, Dell'Osso LF, Tomsak RL, Jacobs JB. Combining recessions (nystagmus and strabismus) with tenotomy improved visual function and decreased oscillopsia and diplopia in acquired downbeat nystagmus and in horizontal infantile nystagmus syndrome. *J AAPOS*. 2007;11:135-141.
  19. Serra A, Dell'Osso LF, Jacobs JB, Burnstine RA. Combined gaze-angle and vergence variation in infantile nystagmus: two therapies that improve the high-visual acuity field and methods to measure it. *Invest Ophthalmol Vis Sci*. 2006;47:2451-2460.
  20. Wang Z, Dell'Osso LF, Jacobs JB, Burnstine RA, Tomsak RL. Effects of tenotomy on patients with infantile nystagmus syndrome: foveation improvement over a broadened visual field. *J AAPOS*. 2006;10:552-560.
  21. Dell'Osso LF. Fixation characteristics in hereditary congenital nystagmus. *Am J Optom Arch Am Acad Optom*. 1973;50:85-90.
  22. Tkalcevic LA, Abel LA. The effects of increased visual task demand on foveation in congenital nystagmus. *Vision Res*. 2005;45:1139-1146.
  23. Dell'Osso LF, Leigh RJ. Foveation periods and oscillopsia in congenital nystagmus. *Invest Ophthalmol Vis Sci*. 1990;31:122.
  24. Dell'Osso LF, Leigh RJ. Foveation period stability and oscillopsia suppression in congenital nystagmus. An hypothesis. *Neuroophthalmology*. 1992;12:169-183.
  25. Dell'Osso LF, Averbuch-Heller L, Leigh RJ. Oscillopsia suppression and foveation-period variation in congenital, latent, and acquired nystagmus. *Neuroophthalmology*. 1997;18:163-183.
  26. Abadi RV, Bjerre A. Motor and sensory characteristics of infantile nystagmus. *Br J Ophthalmol*. 2002;86:1152-1160.
  27. Sheth NV, Dell'Osso LF, Leigh RJ, Van Doren CL, Peckham HP. The effects of afferent stimulation on congenital nystagmus foveation periods. *Vision Res*. 1995;35:2371-2382.
  28. Jacobs JB, Dell'Osso LF, Hertle RW, Acland GM, Bennett J. Eye movement recordings as an effectiveness indicator of gene therapy in RPE65-deficient canines: implications for the ocular motor system. *Invest Ophthalmol Vis Sci*. 2006;47:2865-2875.
  29. Shery T, Proudlock FA, Sarvananthan N, McLean RJ, Gottlob I. The effects of gabapentin and memantine in acquired and congenital nystagmus: a retrospective study. *Br J Ophthalmol*. 2006;90(7):839-843.

30. Cüppers C. Probleme der operativen Therapie des okulären Nystagmus. *Klin Monatsbl Augenheilkd*. 1971;159:145–157.
31. Kestenbaum A. Nouvelle operation de nystagmus. *Bull Soc Ophthalmol Fr*. 1953;6:599–602.
32. Anderson JR. Causes and treatment of congenital eccentric nystagmus. *Br J Ophthalmol*. 1953;37:267–281.
33. Goto N. A study of optic nystagmus by the electro-oculogram. *Acta Soc Ophthalmol Jpn*. 1954;58:851–865.
34. Lee J. Surgical management of nystagmus. *J Roy Soc Med*. 2002;95:238–241.
35. Dell'Osso LF, Van der Steen J, Steinman RM, Collewijn H. Foveation dynamics in congenital nystagmus I: Fixation. *Doc Ophthalmol*. 1992;79:1–23.
36. Dell'Osso LF. Extraocular muscle tenotomy, dissection, and suture: a hypothetical therapy for congenital nystagmus. *J Pediatr Ophthalmol Strab*. 1998;35:232–233.
37. Dell'Osso LF, Hertle RW, Williams RW, Jacobs JB. A new surgery for congenital nystagmus: effects of tenotomy on an achiasmatic canine and the role of extraocular proprioception. *J AAPOS*. 1999;3:166–182.
38. Hertle RW, Dell'Osso LF, FitzGibbon EJ, Thompson D, Yang D, Mellow SD. Horizontal rectus tenotomy in patients with congenital nystagmus. Results in 10 adults. *Ophthalmology*. 2003;110:2097–2105.
39. Hertle RW, Dell'Osso LF, FitzGibbon EJ, Yang D, Mellow SD. Horizontal rectus muscle tenotomy in patients with infantile nystagmus syndrome: a pilot study. *J AAPOS*. 2004;8:539–548.
40. Wang Z, Dell'Osso LF, Zhang Z, Leigh RJ, Jacobs JB. Tenotomy does not affect saccadic velocities: support for the "small-signal" gain hypothesis. *Vision Res*. 2006;46:2259–2267.
41. Helveston EM, Ellis FD, Plager DA. Large recession of the horizontal recti for treatment of nystagmus. *Ophthalmology*. 1991;98:1302–1305.
42. Von Noorden GK, Sprunger DT. Large rectus muscle recession for the treatment of congenital nystagmus. *Arch Ophthalmol*. 1991;109:221–224.
43. Tomsak RL, Dell'Osso LF, Rucker JC, Leigh RJ, Bienfang DC, Jacobs JB. Treatment of acquired pendular nystagmus from multiple sclerosis with eye muscle surgery followed by oral memantine. *DJO*. 2005;11(4):1–11.
44. Wang ZI, Dell'Osso LF. Being "slow to see" is a dynamic visual function consequence of infantile nystagmus syndrome: model predictions and patient data identify stimulus timing as its cause. *Vision Res*. 2007;47(11):1550–1560.
45. Abadi RV. Visual performance with contact lenses and congenital idiopathic nystagmus. *Br J Physiol Optics*. 1979;33:32–37.
46. Dell'Osso LF, Traccis S, Abel LA, Erzurum SI. Contact lenses and congenital nystagmus. *Clin Vision Sci*. 1988;3:229–232.
47. Matsubayashi K, Fukushima M, Tabuchi A. Application of soft contact lenses for children with congenital nystagmus. *Neuroophthalmology*. 1992;12:47–52.

Advances in Understanding  
Mechanisms and Treatment of Infantile  
Forms of Nystagmus

---

*Edited by*

R. John Leigh, MD

Michael W. Devereaux, MD

OXFORD  
UNIVERSITY PRESS  
2008