

Spasmus Nutans: A Quantitative, Prospective Study

B. M. Weissman^{*,****}, L. F. Dell'Osso^{*,***},
L. A. Abel^{*,***} and R. J. Leigh^{*,**,*}

Ocular Motor Neurophysiology Laboratory* and Neurology Service**, Veterans Administration Medical Center; and the Departments of Neurology*** and Pediatrics****, Case Western Reserve University and University Hospitals, Cleveland, Ohio, USA

INTRODUCTION

Nystagmus in infancy may be due to a variety of disorders. The differential diagnosis includes congenital nystagmus (CN), latent/manifest latent nystagmus (LMLN), nystagmus in association with optic nerve glioma and spasmus nutans. Once optic glioma is excluded, SN may be suspected from anomalous head movement and disconjugate oscillations, but, at present, only follow-up will confirm whether a child has CN or SN.

We have prospectively conducted a study of the ocular oscillations in infants with the presumptive diagnosis of spasmus nutans with the objective of identifying features characteristic of SN early in its course.

METHODS

None of the infants in the study group showed signs of neurologic deficit, diminished visual acuity, strabismus, optic nerve abnormality or ocular pathology. When possible, the infants and children were videotaped before the oculographic recording session. Movements of both eyes were recorded using infrared or DC, electro-oculographic (EOG) techniques. The total system bandwidth (position and velocity) was 0-100 Hz. Although absolute amplitude calibration was not possible, these methodologies allowed accurate measurement of ocular oscillation waveforms. In addition, by equalizing records during saccades, it was possible to judge the relative waveform amplitude in each eye. For most of the recording sessions, eye velocity was also obtained for more accurate delineation of the waveforms.

RESULTS

The mean age of onset was four months with a range of birth to fourteen months. Four of the five exhibited head nodding or tilting in addition to the ocular oscillations. One of the children demonstrated a resolution of his ocular oscillations ten months after their onset, thereby confirming the diagnosis of spasmus nutans. He had no definite history of abnormal head movement. One infant showed no ocular oscillations on the video record although there was occasional head nodding. However, persistence of her nystagmus was evident in the eye movement records.

Table 1 summarizes the nystagmus characteristics. All infants demonstrated a pendular waveform both in the initial and follow-up records. The frequency of the ocular oscillations ranged from 3 to 9 Hz. Most patients showed a range of frequencies within one recording session. All of the patients exhibited an asymmetry of the amplitudes of the oscillations in the two eyes. Two patients showed periods of asymmetry and symmetry during a single recording session. Three patients exhibited phase differences ranging between 0 and 180 degrees. In two, the phase difference variability was in a narrower range, remaining between 120 and 180 degrees. A mean and standard deviation analysis of approximately ten measured cycles from each record underscore this variability. One infant, R.W., first showed only in-phase oscillations; at a subsequent recording session seven months later, the phase relationships between the waveforms in each eye varied from 0 through 180 degrees.

TABLE 1 Characteristics of Spasmus Nutans

name	wave-	relative			
date	form	frequency	amplitude	phase relations	conjugacy
M.L. 1/83	P	3 Hz	R>L =	range: 0 - 180 m: 135.5 sd: 52.9	-1 0,-2
5/85	P	3 - 5 Hz	R>L =	range: 0 - 180 m: 78.7 sd: 61	+1 0,-1 -2,+2
J.H. 1/84	P	4 - 6 Hz	R>L,=	range: 0 - 180 m: 129.7 sd: 73.4	-1,-2 +1,+2 0
5/85		(No ocular oscillations present)			
R.W. 10/84	P	7 - 9 Hz	R>L	range: 0	+1
6/85	P	6 - 7 Hz	L>R	range: 0 - 180 m: 89.6 sd: 70.5	+1,-1
S.T. 2/85	P	6 Hz	L>R	range: 120 - 180 m: 142.1 sd: 22.2	-1
C.D. 4/85	P	5 - 6 Hz	L>R	range: 0 - 180 m: 104.3 sd: 63.7	-1 +1

P - pendular, R - right, L - left, m - mean, sd - standard deviation. Conjugacy scale: +2 - equal amplitudes, in phase; +1 - unequal amplitudes, in phase; 0 - uniocular; -1 - unequal amplitudes, out of phase; -2 - equal amplitudes, out of phase. Amplitudes and conjugacies listed in order of descending incidence.

The conjugacy scale facilitates comparison between patients since it indicates both relative amplitudes and phase difference of the oscillation of the two eyes. The terms "in phase" and "out of phase" indicate phase differences of 0 - 90 and 90 - 180 degrees, respectively. Thus, the predominant conjugacy number (shown on the first line of each recording session) corresponds to the mean value of that patient's phase relationship and most common relative amplitude.

Eye movement recordings documented the transient nature of the phase relationship between the oscillations of the two eyes. Figure 1 shows both eyes at three closely spaced times in a single recording session for one patient. The SN varied from in phase to 180 degrees out of phase within 2 seconds; the uniocular portion preceded this by 90 seconds. True uniocular oscillation was recorded in only three of the seven patients.

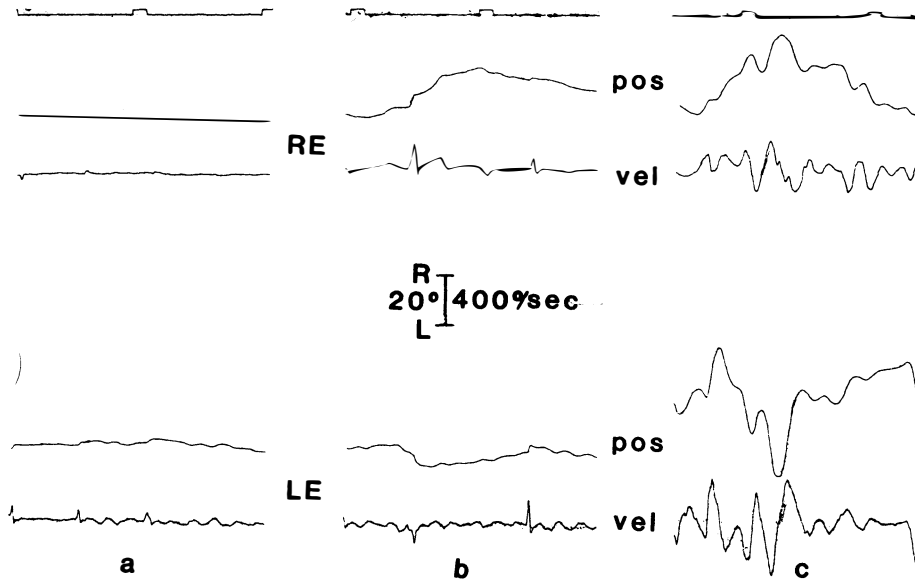


Fig. 1. Examples of spasmus nutans with the following relative amplitudes: a) uniocular oscillation of the LE; b) binocular oscillation with no phase difference; and c) binocular oscillation with 180 degree phase difference. R - right, L - left, RE - right eye, LE - left eye, pos - position, vel - velocity and, the timing marks represent 1 second intervals.

In one patient, the vestibulo-ocular reflex was stimulated by quasi-sinusoidal passive movement of the infant's head in the horizontal plane. This manipulation did not suppress his ocular oscillations. Active head movement in relation to the ocular oscillations was not evaluated.

DISCUSSION

Spasmus nutans is a benign, self-limiting condition which should be differentiated from other diseases of infancy that have significant morbidity and potential mortality. Several reports describe cases in which infants presented with pendular and often asymmetric nystagmus initially diagnosed as spasmus nutans (Albright, and colleagues, 1984; Antony, and colleagues, 1980; Kelly, 1970; Koenig, and colleagues, 1982; Lavery, and colleagues, 1984). These infants were later found to have optic nerve and intracranial gliomas. An important clinical feature in all of these patients was the presence of optic nerve atrophy. Some of the patients exhibited other associated clinical findings such as diencephalic syndrome and evidence of increased intracranial pressure. This is the first study, to date, which both clinically and oculo-graphically evaluates

infants carrying the SN diagnosis and quantitatively documents eye movement recordings in a patient whose acquired pendular nystagmus subsequently resolved.

Congenital nystagmus is an ocular oscillation which may be first noted during infancy. The diagnostic distinction between CN, LMLN and spasmus nutans is important. Congenital nystagmus and LMLN are associated with life-long impairment of visual acuity; the CN patient's siblings and children may be similarly affected. Thus, it is important to differentiate congenital nystagmus from spasmus nutans as early as possible.

Gresty, and colleagues (1976) and Gresty and Ell (1981) described three patients who exhibited a distinct pattern of eye/head coordination. All carried a tentative diagnosis of spasmus nutans; head shaking modified their nystagmus so that vision improved. However, all were older children (> three years of age) and follow-up was not obtained. Suppression of nystagmus occurred with both active and passive head shaking. Gresty and colleagues interpreted this adaptative suppression of nystagmus as due to vestibular stimulation. In one of our patients, J.H., we passively horizontally rotated the infant's head and observed no modification of the nystagmus. Our patient had no clear history of anomalous head movement whereas all of Gresty's patients did. This patient's nystagmus subsequently resolved.

Analysis of the waveforms revealed that within a single recording session, both the frequency of the oscillations and the interocular phase relationships may vary considerably, even from second to second. In two patients, variability in the relative amplitude and waveform characteristics was noted not only during one recording session, but also in different sessions. We were unable to detect abnormal eye or head movements in a video-tape record of the one infant whose SN had clinically resolved; the eye movement recordings clearly showed ocular oscillations.

The etiology of this transient condition of infancy and early childhood still remains to be determined. Earlier reports considered the pathogenesis of this disorder related to diverse causes which included light deprivation, dietary factors, season, epilepsy, and poor socio-economic conditions (Kalyanaraman, and colleagues, 1973; Østerberg, 1937). However, the report of SN in twins points to the importance of genetic factors (Hoyt and Aicardi, 1979; Katzman, and colleagues, 1981).

Quantitative oculography has made analysis of the dynamic characteristics of eye movements possible. For acquired pendular nystagmus in adults, Gresty, and colleagues (1982) suggested a defect with yoking between vertical, horizontal and torsional ocular motor systems. The disconjugate nature of the nystagmus suggests a yoking abnormality. In infants with SN, the abnormality may not represent a static anatomic lesion of the yoking system but, instead, an aberrant development of the connections associated with it; subsequent modification of these may account for the transient nature of the nystagmus and its variability.

One ocular motor system we considered as possibly contributing to development of spasmus nutans is the vergence system. The vergence system, in adults, can be made to oscillate at a mean of 2.5 Hz (Zuber and Stark, 1968). It would be difficult for such a system to account for the rapid (e.g., 11 Hz) ocular oscillations observed with spasmus nutans, but could account for the low frequency oscillations. Moreover, none of the infants we examined showed signs of a strabismus that might indicate an abnormality of the vergence mechanism.

The saccadic system is another ocular motor control system that may account for the development of SN. Zee and Robinson (1979) previously described and modelled saccadic oscillations. Both their patient and model simulation showed high frequency oscillations. A similar instability of this system may result in the observed rapid ocular oscillations seen in SN. However, all of the SN patients we examined made normal saccades.

The pursuit system can also exhibit oscillatory behavior. Recent work by Optican, and colleagues (1985) evaluated the adaptation of the pursuit system in adult patients with monocular ocular motor palsies. They observed 3 Hz ocular oscillations associated with pursuit under conditions causing high pursuit gain. However, this low-frequency oscillation cannot account for the higher frequency waveforms seen in SN.

Spasmus nutans is a still perplexing self-limiting affliction of infancy and early childhood. Future studies should help elucidate the neural substrate of this disorder. This knowledge will help us use recording for early discrimination between spasmus nutans and other ocular oscillations.

ACKNOWLEDGEMENTS

This work was supported in part by the Veterans Administration.

REFERENCES

- Albright, A.L., R.J. Scwabassi, T.L. Slamovits, and I. Bergman (1984). Spasmus nutans associated with optic gliomas in infants. *J. Pediat.*, 105, 778-780.
- Antony, J.H., R.A. Ouvrier, and G. Wise (1980). Spasmus nutans. A mistaken identity. *Arch. Neurol.*, 37, 373-375.
- Gresty, M.A., and J.J. Ell (1981). Spasmus nutans or congenital nystagmus? Classification according to objective criteria. *Brit. J. Ophthalmol.*, 65, 510-511.
- Gresty, M.A., J.J. Ell, and L.J. Findley (1982). Acquired pendular nystagmus: its characteristics, localising value and pathophysiology. *J. Neurol. Neurosurg. Psychiat.*, 45, 431-439.
- Gresty, M.A., J. Leech, M.D. Sanders, and H. Eggars (1976). A study of head and eye movement in spasmus nutans. *Brit. J. Ophthalmol.*, 160, 652-654.
- Hoyt, C.S., and E. Aicardi (1979). Acquired monocular nystagmus in monozygous twins. *J. Pediat. Ophthalmol. Strab.*, 16, 115-118.
- Kalyanaraman, K., K. Jagannathan, R.A. Ramanujam, and B. Ramamurthi (1973). Congenital head nodding and nystagmus with cerebrotocerebellar degeneration. *J. Pediat.*, 83, 1023-1026.
- Katzman, B., L.W. Lu, and R.P. Tiwari (1981). Spasmus nutans in identical twins. *Ann. Ophthalmol.*, 13, 1193-1195.
- Kelly, T.W. (1970). Optic glioma presenting as spasmus nutans. *Pediat.*, 45, 295-296.
- Koenig, S.B., T.P. Naidid, and Z. Zaporackas (1982). Optic glioma masquerading as spasmus nutans. *J. Pediat. Ophthalmol. Strab.*, 19, 20-24.
- Lavery, M.A., J.F. O'Neill, F.C. Chu, and L.J. Martyn (1984). Acquired nystagmus in early childhood: a presenting sign of intracranial tumor. *Ophthalmol.*, 91, 425-435.
- Østerberg, G. (1937). On spasmus nutans. *Acta Ophthalmol.*, 15, 457-467.
- Optican, L.M., D.S. Zee, and F.C. Chu (1985). Adaptive response to ocular muscle weakness in human pursuit and saccadic eye movements. *J. Neurophysiol.*, 54, 110-122.
- Zee, D.S., and D.A. Robinson (1979). A hypothetical explanation of saccadic oscillations. *Ann. Neurol.*, 5, 405-414.
- Zuber, B.L., and L. Stark (1968). Dynamical characteristics of the fusional vergence eye-movement system. *IEEE Trans. Sys. Sci. Cybernet.*, SCC-4, 72-79.

ADAPTIVE PROCESSES IN VISUAL AND OCULOMOTOR SYSTEMS

Proceedings of a conference held in Asolimar, California, USA
16–20 June 1985

Editors:

E. L. KELLER and D. S. ZEE



PERGAMON PRESS

OXFORD · NEW YORK · TORONTO · SYDNEY
FRANKFURT · TOKYO · SAO PAULO · BEIJING