

## Torsional nystagmus: Quantitative features and possible pathogenesis

**Article abstract**—We measured eye rotations in three planes in a patient with acquired, torsional nystagmus. This nystagmus had linear or increasing-velocity waveforms, was increased after active pitch rotations of the head, and was suppressed by convergence. Magnetic resonance imaging demonstrated a midpontine lesion that was probably a venous angioma. We postulate that torsional nystagmus in this patient was due to disruption of central vestibular connections.

NEUROLOGY 1988;38:992-994

John H. Noseworthy, MD; George C. Ebers, MD; R. John Leigh, MD; and Louis F. Dell'Osso, PhD

**Nystagmus** in which the predominant rotation of the eyes is torsional (ie, cyclorotation or roll of the eyes around the line of sight) is uncommon and has rarely been reported<sup>1</sup> due, in part, to lack of satisfactory methods for recording these rotations. We report here quantitative measurements on a patient with almost pure torsional nystagmus who was shown to have a discrete pontine lesion.

**Case report.** At age 44 (December 1981) this patient noticed diagonal diplopia for 30 minutes. He recovered fully but had a similar transient episode 5 days later. At this time he first noticed recurrent episodes of oscillopsia. He described brief (duration 1 to 2 minutes) sensations of counterclockwise movement of the environment that increased in frequency with exercise and could be abolished by fixation on a stationary object or with eye closure. Four months later he had a 6-hour episode of numbness of the lower lip from which he recovered completely. His medical history, family history, and functional inquiry were unremarkable.

Examination at age 46 (January 1983) revealed primary position torsional nystagmus with counterclockwise quick-phases. (The convention used here is to define "clockwise" and "counterclockwise" from the point of view of the patient, not the examiner.<sup>2</sup> This convention is consistent with that used for horizontal and vertical eye movements and helps with interpretation of visual symptoms due to torsional nystagmus.) This nystagmus increased in amplitude on left gaze. It converted to a low-amplitude counterclockwise nystagmus on

right gaze and a vertical nystagmus on looking up. Convergence abolished the nystagmus. There was mild slowing of rapid, repetitive foot movements on the left and a possible upgoing toe on the right. CT showed mild midline cerebellar atrophy. An abnormality was suspected in the left pons on the brainstem auditory evoked response (BAER) in that waves IV and V were poorly defined with left ear stimulation. Visual evoked responses were normal. CSF was positive for oligoclonal banding (isoelectric focusing in agarose method). A single episode of pontine demyelination was suspected.

He continued to have intermittent oscillopsia over the next 3 years with no new neurologic symptoms or findings on repeated neurologic examinations. Examination at age 49 (October 1986) revealed pure torsional nystagmus with quick-phases that were counterclockwise in the primary position. This nystagmus was more prominent in left gaze and was suppressed by convergence. The nystagmus was not influenced when visual fixation was eliminated with Frenzel goggles. There was minor slowing of adduction of the left eye. There was a left hyperphoria and left exophoria which was more marked in right gaze. Magnetic resonance imaging (1.5 T General Electric Signa) revealed a discrete abnormality in the left midpontine tegmentum suggestive of a venous angioma (figure 1).

In July 1987, positional testing showed no change in the torsional nystagmus with lateral head tilt or lying prone. However, with the assumption of a right-ear-dependent, head-hanging position, after a latency of 3 seconds there was a high-amplitude clockwise nystagmus that persisted for 15 seconds; with three repetitions, this nystagmus disappeared.

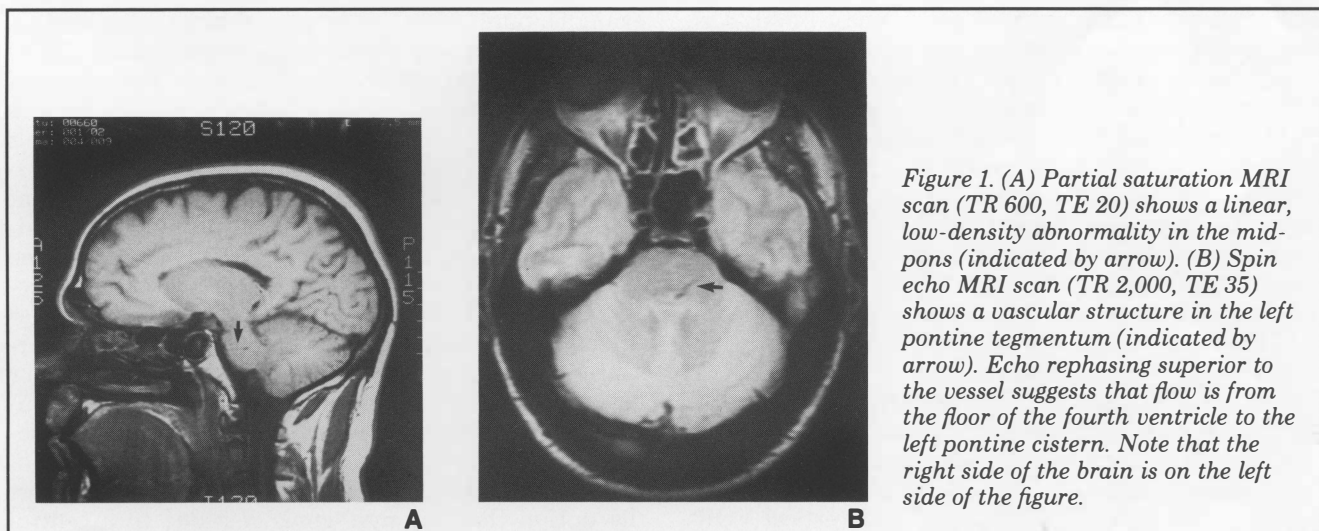


Figure 1. (A) Partial saturation MRI scan (TR 600, TE 20) shows a linear, low-density abnormality in the midpons (indicated by arrow). (B) Spin echo MRI scan (TR 2,000, TE 35) shows a vascular structure in the left pontine tegmentum (indicated by arrow). Echo rephasing superior to the vessel suggests that flow is from the floor of the fourth ventricle to the left pontine cistern. Note that the right side of the brain is on the left side of the figure.

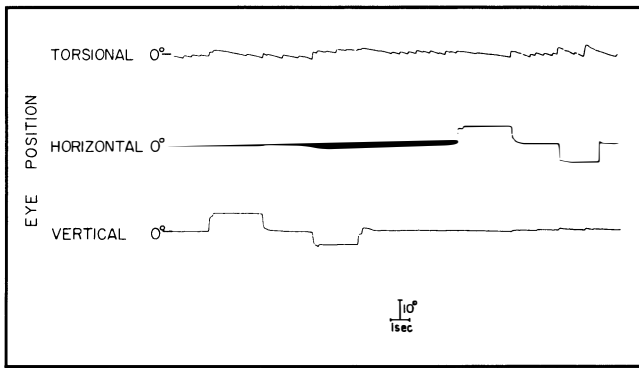


Figure 2. Spontaneous counterclockwise torsional nystagmus in primary and secondary positions of gaze. Upward pen deflections represent counterclockwise, rightward and upward rotations of eyes in the orbits. Note that vertical and horizontal components are minimal, even in secondary gaze positions.

**Methods.** Horizontal and vertical rotations of the right eye and torsional rotations of the left eye were measured using 6-foot magnetic field coils (CNC Engineering, Seattle, WA) and search coils consisting of Silastic scleral annuli (Skalar, Delft, Netherlands).<sup>3</sup> The search coils were calibrated by clamping them to a protractor device and measuring the changes in voltage induced by known rotations in three planes. The patient made horizontal and vertical saccades between fixed target locations, pursued a small moving target at constant horizontal or vertical velocities of up to 20 degrees/second, actively rotated his head in yaw, pitch, or roll to test the vestibulo-ocular reflex (VOR), and fixed on a small object held by the examiner at 1.3 meters ("far") or 20 cm ("near"). Data were displayed on a pen recorder (bandwidth 0 to 100 Hz) and stored on magnetic tape for off-line digitization (at 200 Hz) for analysis with an interactive program.

**Results.** With the eyes close to primary position, there was a spontaneous, counterclockwise, torsional nystagmus (ie, intorsional slow-phases in the left eye). Only minimal horizontal and vertical components were evident (figure 2), and these components did not change appreciably when the eyes moved to some new horizontal or vertical position in the orbit. The slow-phase profile was sometimes linear and sometimes increasing velocity. The mean velocity of slow-phases (averaged over ten successive cycles) was 2.5 degrees/second. On looking to the left, the slow-phase velocity (mean, 5 degrees/second) and intensity of nystagmus increased. The nystagmus partially damped with convergence (figure 3A). During horizontal smooth pursuit, the nystagmus increased modestly (mean slow-phase velocity, 5.5 degrees/second), but a prominent increase followed pitch head rotations when mean slow-phase velocity was 14 degrees/second (figure 3B). Static, ear-to-shoulder head tilt did not noticeably affect slow-phase velocity. During active rotations of the head in roll, at about 0.5 Hz, asymmetry of the torsional VOR was evident with counterclockwise beating nystagmus (figure 3C). Horizontal saccades of the right eye were normal. Smooth pursuit showed some impairment both up and to the right. The horizontal and vertical VOR appeared normal, as judged by the stability of gaze during active head rotations.

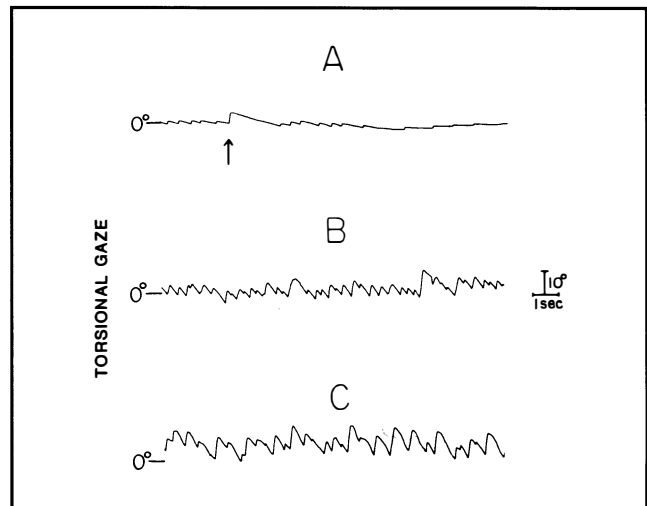


Figure 3. (A) Suppressive effect on nystagmus of viewing a near target (presented at time indicated by arrow). (B) Following active pitch movements of the head, the torsional nystagmus was increased. (C) During active roll head movements, asymmetry of the torsional VOR was evident with counterclockwise quick-phases. Upward pen deflections represent counterclockwise eye rotations in space (gaze).

**Discussion.** Torsional rotations of the eye are frequently a component of acquired forms of nystagmus—for example, in benign paroxysmal positional vertigo and in see-saw nystagmus. In our patient, the torsional movements were much greater than any associated vertical or horizontal movements. The torsional nystagmus was only mildly affected by changes in orbital position. Moreover, changes in orbital position produced only small horizontal or vertical components. The torsional nystagmus was accentuated after actively rotating the head in pitch and was suppressed by convergence.

Why pure torsional nystagmus is uncommon remains unclear. One possible explanation relates to the central connections from the semicircular canals. For example, pure upbeat or pure downbeating nystagmus require involvement of connections from corresponding canals on both sides (eg, the posterior canals for downbeat<sup>4</sup>). Pure torsional nystagmus would require involvement of connections from both vertical canals from one labyrinth. Is the pathogenesis of pure torsional nystagmus similar to that of upbeat or downbeat nystagmus? Although downbeating nystagmus was initially postulated to be due to an imbalance of the smooth pursuit system, more recent views have suggested a central disturbance of the vertical semicircular canals or the otoliths, and the former seem more important.<sup>4,5</sup> Since there is no torsional pursuit system, our patient's nystagmus could not be due to a pursuit imbalance. Striking increases of torsional nystagmus occurred following pitch head rotations, but static tilts of his head had little effect. This evidence might support the notion that his nystagmus was due to a central imbalance of connections from the vertical semicircular canals. In addition, positional testing produced an op-

positely directed (clockwise) nystagmus that showed the temporal features of the nystagmus of benign paroxysmal positional vertigo (fatigue and habituation). It seems possible that positional testing reversed a central vestibular imbalance, but the possibility of coexistent cupulolithiasis cannot be ruled out. In any case, persistent torsional nystagmus cannot be regarded as a manifestation of peripheral vestibular disease. Also against a peripheral etiology is the lack of effect of visual fixation on the nystagmus.

The increasing slow-phase velocity observed in our patient's nystagmus has also been described in acquired upbeating and downbeating nystagmus.<sup>6</sup> Thus, this is further evidence that his nystagmus represented a central disturbance of vestibular connections from the vertical semicircular canals. His nystagmus suppressed with convergence, a phenomenon described with congenital nystagmus, but also in some forms of acquired oscillations such as downbeat nystagmus.<sup>7</sup> It has been recently shown that viewing a near target influences the function of the vestibulo-ocular and otolith-ocular reflexes.<sup>8</sup>

Finally, under natural circumstances, purely torsional eye rotations occur only in response to vestibular stimuli. In our patient, change in horizontal or vertical orbital position did not introduce appreciable horizontal or vertical eye rotations; the nystagmus remained predominantly torsional. The latter suggests that central vestibular mechanisms play a significant role in adjusting eye rotations for different orbital positions—a role previously ascribed to orbital mechanics.<sup>9</sup>

The lesion in this patient, running from the floor of the fourth ventricle into the left midpontine tegmentum, might have disrupted commissural fibers between the vestibular nuclei. However, because programs for torsional eye rotations require central processing of information from more than one vertical canal (see above), it seems more likely that projections from the vestibular nuclei or vestibulo-cerebellum to the midbrain nuclei that coordinate torsional gaze were involved. Thus, our patient had a partial left internuclear ophthalmoplegia. Moreover, it has been reported that torsional eye movements are produced during experimental stimulation of the brachium conjunctivum.<sup>10</sup>

The ability to reliably and accurately record torsional rotations of the globe in patients with neurologic disease opens up a field of study that has been held back by lack of adequate recording methods until the present. The magnetic search coil method for recording eye

movements now allows precise measurement of eye and head rotation in all three planes and thus is a powerful tool for the analysis of disorders of ocular motility.

## Acknowledgments

We are grateful to Holly Stevens and Laura Feick for editorial assistance.

---

From the Department of Clinical Neurological Sciences, University of Western Ontario, London, Ontario, Canada (Drs. Noseworthy and Ebers); and the Ocular Motor Neurophysiology Laboratory, VA Medical Center, and Department of Neurology, University Hospitals, Case Western Reserve University, Cleveland, OH (Drs. Leigh and Dell'Osso).

Supported by a Career Development Award from the Multiple Sclerosis Society of Canada (to Dr. Noseworthy), a Career Scientist Award from the Ontario Ministry of Health (to Dr. Ebers), US PHS grant EY06717 (to Dr. Leigh), the Evenor Armington Fund, and the Veterans Administration.

Received August 27, 1987. Accepted for publication in final form October 26, 1987.

Address correspondence and reprint requests to Dr. Leigh, Department of Neurology, University Hospitals of Cleveland, 2074 Abington Road, Cleveland, OH 44106.

---

## References

1. Dell'Osso LF. Nystagmus and other ocular motor oscillations and intrusions, chap 9. In: Lessel S, Van Dalen JTW, eds. *Current neuro-ophthalmology*, vol 1. Chicago: Year Book Medical Publishers, 1987:139-172.
2. Kestenbaum A. *Clinical methods of neuro-ophthalmologic examination*, 1st ed. New York: Grune and Stratton, 1947:216-260.
3. Ferman L, Collewijn H, Jansen TC, Van den Berg AV. Human gaze stability in the horizontal, vertical and torsional direction during voluntary head movements, evaluated with a three-dimensional scleral induction coil technique. *Vision Res* 1987;27:811-828.
4. Baloh RW, Spooner JW. Downbeat nystagmus: a type of central vestibular nystagmus. *Neurology* 1981;31:304-310.
5. Gresty M, Barratt H, Rudge P, Page N. Analysis of downbeat nystagmus: otolithic vs. semicircular canal influences. *Arch Neurol* 1986;43:52-55.
6. Leigh RJ, Zee DS. *The neurology of eye movements*. Philadelphia: F.A. Davis, 1983:196-198.
7. Lavin PJM, Tracis S, Dell'Osso LF, Abel LA, Ellenberger C. Downbeat nystagmus with a pseudocycloid waveform: improvement with base-out prisms. *Ann Neurol* 1983;13:621-624.
8. Gresty MA, Bronstein AM, Barratt H. Eye movement responses to combined linear and angular head movement. *Exp Brain Res* 1987;65:377-384.
9. Fetter M, Hain TC, Zee DS. Influence of eye and head position on vestibulo-ocular reflex. *Exp Brain Res* 1986;64:208-216.
10. Cohen B, Goto K, Shanzer S, Weiss AH. Eye movements induced by electrical stimulation of the cerebellum in the alert cat. *Exp Neurol* 1965;13:145-162.